



PATIENT

Groot Parker

PRESENTING CLINICAL SIGNS

Enlarged abnormal spleen noted during a practice ultrasound. Otherwise no concerns at home.

SPECIES

Canine

ULTRASONOGRAPHIC EXAMINATION OF THE ABDOMEN

Urinary System

The **urinary bladder**, trigone, and pelvic urethra presented normal thicknesses and normal tone. The ureters were not visible which is normal. No uroliths or sediment were visualized and anechoic urine was present. No evidence of inflammatory or neoplastic changes were noted. Ureteral papillae were normal.

BREED

Pit Bull X

SEX

Neutered Male

The **kidneys** revealed normal size and structure, corticomedullary definition and ratio for this age. The cortices presented largely uniform texture with normal echogenic relationship to liver and spleen. Medullary structure differed distinctly from the cortex and no evidence of pelvic dilation was present. The capsules were acceptably uniform without significant irregularities. The left kidney measured 6.0 cm. The right kidney measured 6.0 cm.

AGE

10 Years

Adrenal Glands

The **adrenal glands** were not visualized.

WEIGHT

50 Pounds

Spleen

The **spleen** was uniformly enlarged with slight scalloping contour. Minor coarse architecture noted with heterogeneous parenchymal changes. Occasional hyperechoic nodule noted up to 0.94 cm x 0.60 cm.

Liver

The **liver** images submitted revealed subjectively normal liver size, contour, and structure. Parenchymal echogenicity was naturally coarse and hypoechoic to the spleen. Vascular and biliary tracts were of normal volume with no evidence of congestion. The gallbladder presented acceptably thin walls with primarily anechoic content. The cystic and common bile ducts were normal. No pathological hepatic lymphadenopathy was evident. No overt structural evidence of inflammatory, infiltrative or regenerative pathology was evident.

INTERPRETED BY

Eric Lindquist, DMV

DABVP, Cert. IVUSS

Gastrointestinal

Examination of the **gastrointestinal tract** revealed a stomach and intestine free of stasis, of normal wall thickness, acceptable curvilinear mural detail, and peristaltic activity. Small and large intestine demonstrated normal luminal chyme and stool consistency respectively. No obstructive or overt infiltrative disease was noted. No associated abnormal lymphatic activity was noted.

HOSPITAL NAME

Lone Mountain AH

Pancreas

The base and limbs of the **pancreas** were observed to be largely isoechoic to surrounding omental fat. Pancreatic duct and capsular contour were acceptably normal and parenchyma respected normal curvilinear patterns. No overt evidence of active inflammatory or neoplastic disease was noted.

REFERRING VET

Dr. Taylor Parker

INVOICE

38410

ULTRASONOGRAPHIC FINDINGS

- Hypersplenism with heterogeneous nodular changes – reactive hyperplasia, splenitis, emerging round cell neoplasia all possible.

DATE

6/4/22



PATIENT

Groot Parker

SPECIES

Canine

BREED

Pit Bull X

SEX

Neutered Male

AGE

10 Years

WEIGHT

50 Pounds

INTERPRETED BY

Eric Lindquist, DMV
DABVP, Cert. IVUSS

IMAGING PERFORMED BY

Dallas Reynolds, LVT

HOSPITAL NAME

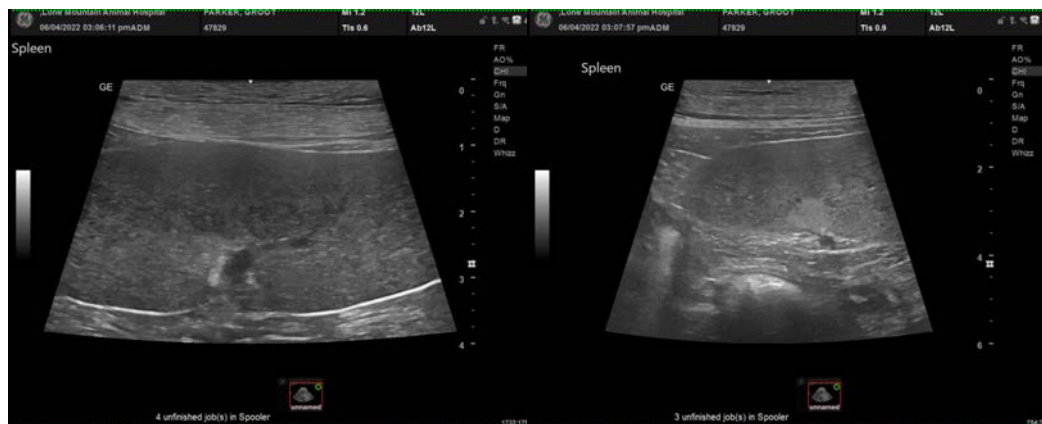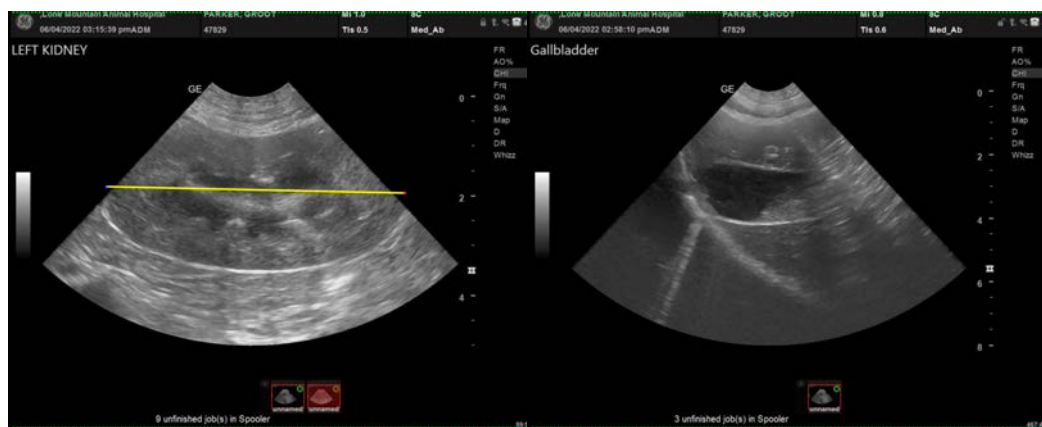
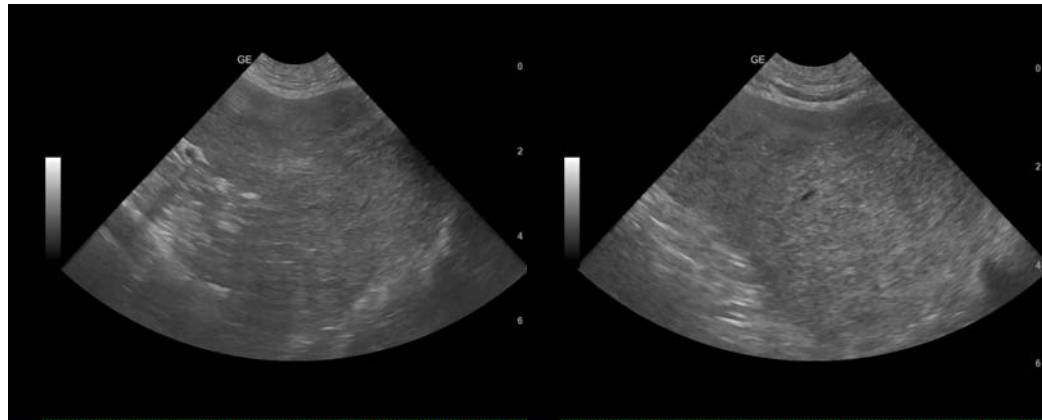
Lone Mountain AH

REFERRING VET

Dr. Taylor Parker

INTERPRETATION OF THE FINDINGS & FURTHER RECOMMENDATIONS

FNA warranted if any weight loss is an issue. If manual palpation reveals discomfort, proactive splenectomy could be considered.



INVOICE

38410

DATE

6/4/22



PATIENT

Groot Parker

SPECIES

Canine

BREED

Pit Bull X

SEX

Neutered Male

AGE

10 Years

WEIGHT

50 Pounds

INTERPRETED BY

Eric Lindquist, DMV

DABVP, Cert. IVUSS

IMAGING PERFORMED BY

Dallas Reynolds, LVT

HOSPITAL NAME

Lone Mountain AH

REFERRING VET

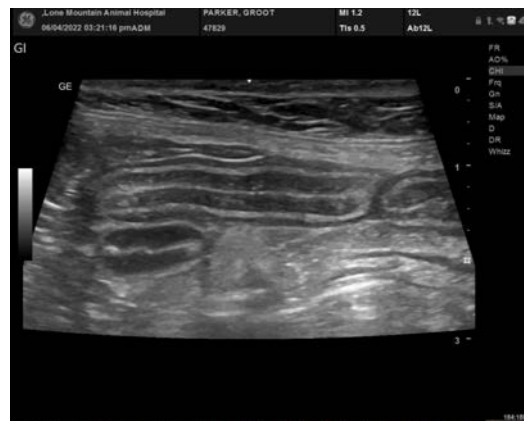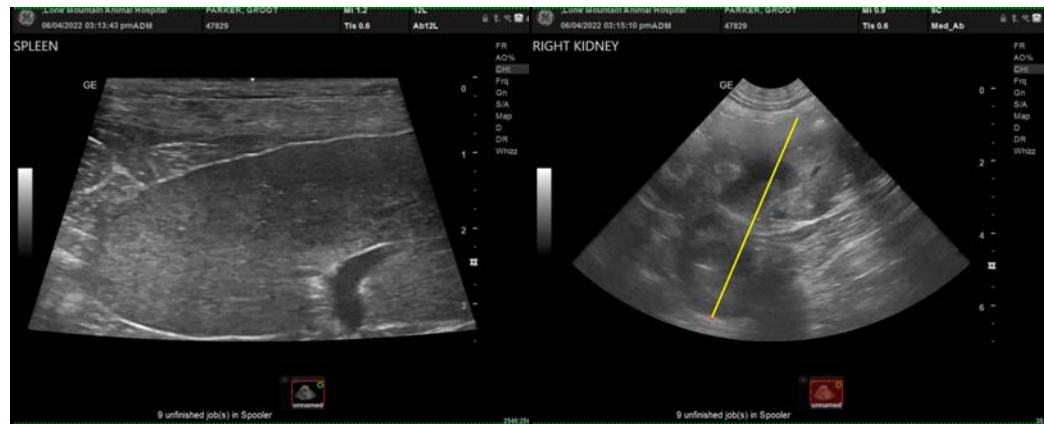
Dr. Taylor Parker

INVOICE

38410

DATE

6/4/22



The information and recommendations provided are based on the images presented by the referring veterinarian/sonographer. No evaluation can be communicated regarding pathology that was not visible in the image/video clips provided.

Thank you for this referral. If the clinical or image interpretation does not parallel your findings or if I can be of any further assistance please contact me.

Eric Lindquist, DMV, DABVP, Cert. IVUSS, CEO of SonoPath.com

info@SonoPath.com