



PATIENT

Bantu Flynn

SPECIES

Avian

BREED

African Grey

SEX

Female

AGE

24 Years

WEIGHT

466g

INTERPRETED BY

Eric Lindquist, DMV

DABVP, Cert. IVUSS

IMAGING PERFORMED BY

Dr. Taylor Parker

HOSPITAL NAME

Lone Mountain AH

REFERRING VET

Dr. Taylor Parker

PRESENTING CLINICAL SIGNS

was seen two days ago for lethargy and increased respiratory effort. was given doxycycline
Abnormal PE/Chem/CBC/UA Results: X-ray report: 1. The widened cardiohepatic silhouette and decreased detail of the caudal coelom are consistent with coelomic effusion. Concurrent cardiomegaly or a coelomic mass are also considered. Primary differentials include congestive heart failure, infectious/inflammatory coelomitis, or a neoplastic effusion. Coelomic ultrasound and an echocardiogram is recommended for further evaluation. 2. The increased opacity of the lungs and fluid-opaque abdominal air sacs may represent pneumonia and secondary air sacculitis or cardiogenic pulmonary edema. A metastatic neoplastic or infectious process is considered less likely. Air sac sampling can be considered for further characterization if heart failure is ruled out.

LIMITED ULTRASONOGRAPHIC EXAMINATION

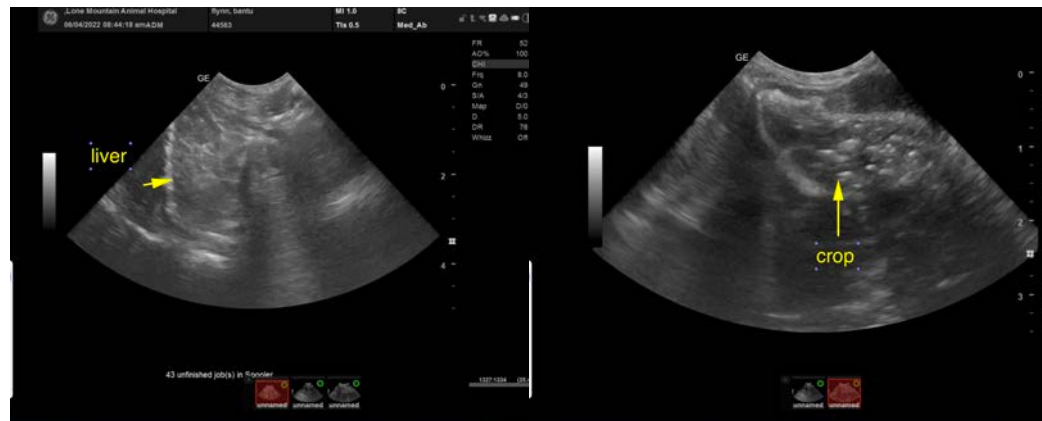Images were submitted of the cranial abdomen and caudal chest. The crop appeared to have normal content with a minor amount of fluid and echogenic material. The liver revealed some echogenic remodeling, history of inflammatory disease likely. No free fluid present. The heart was adequately contractile with no evidence of volume overload. No evidence of ascites. Surrounding tissue was unremarkable. Heart rate was approximately 300.

ULTRASONOGRAPHIC FINDINGS

- Normal cardiac volume and function
- Echogenic hepatic remodeling

INTERPRETATION OF THE FINDINGS & FURTHER RECOMMENDATIONS

I cannot rule out tachyarrhythmia in this patient. However, there is no evidence of primary cardiac disease from a functional or volume standpoint. Primary respiratory disease should be considered, or possible tachyarrhythmia. Liver enzymes should be evaluated if not already performed.



INVOICE

38424

DATE

6/4/22



PATIENT

Bantu Flynn

SPECIES

Avian

BREED

African Grey

SEX

Female

AGE

24 Years

WEIGHT

466g

INTERPRETED BY

Eric Lindquist, DMV

DABVP, Cert. IVUSS

IMAGING PERFORMED BY

Dr. Taylor Parker

HOSPITAL NAME

Lone Mountain AH

REFERRING VET

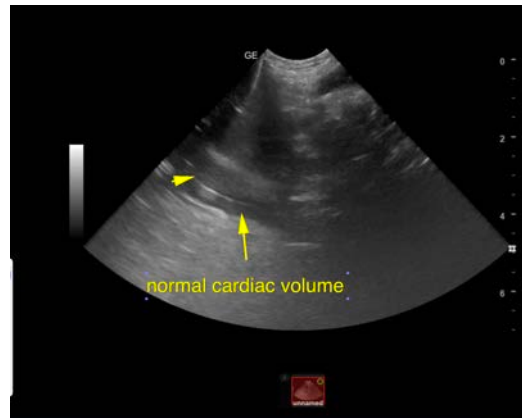
Dr. Taylor Parker

INVOICE

38424

DATE

6/4/22



The information and recommendations provided are based on the images presented by the referring veterinarian/sonographer. No evaluation can be communicated regarding pathology that was not visible in the image/video clips provided.

Thank you for this referral. If the clinical or image interpretation does not parallel your findings or if I can be of any further assistance please contact me.

Eric Lindquist, DMV, DABVP, Cert. IVUSS, CEO of SonoPath.com

info@SonoPath.com