



PATIENT

Harvey Beiermeister

SPECIES

Canine

BREED

Cockapoo

SEX

Neutered Male

AGE

1

WEIGHT

22.2

INTERPRETED BY

Eric Lindquist, DMV

DABVP, Cert. IVUSS

IMAGING PERFORMED BY

Jenn

HOSPITAL NAME

Rockaway AH

REFERRING VET

Dr. Maniar

INVOICE

43633

DATE

6/30/23

PRESENTING CLINICAL SIGNS

Recheck from yesterday showed gastric accumulation with empty small intestine

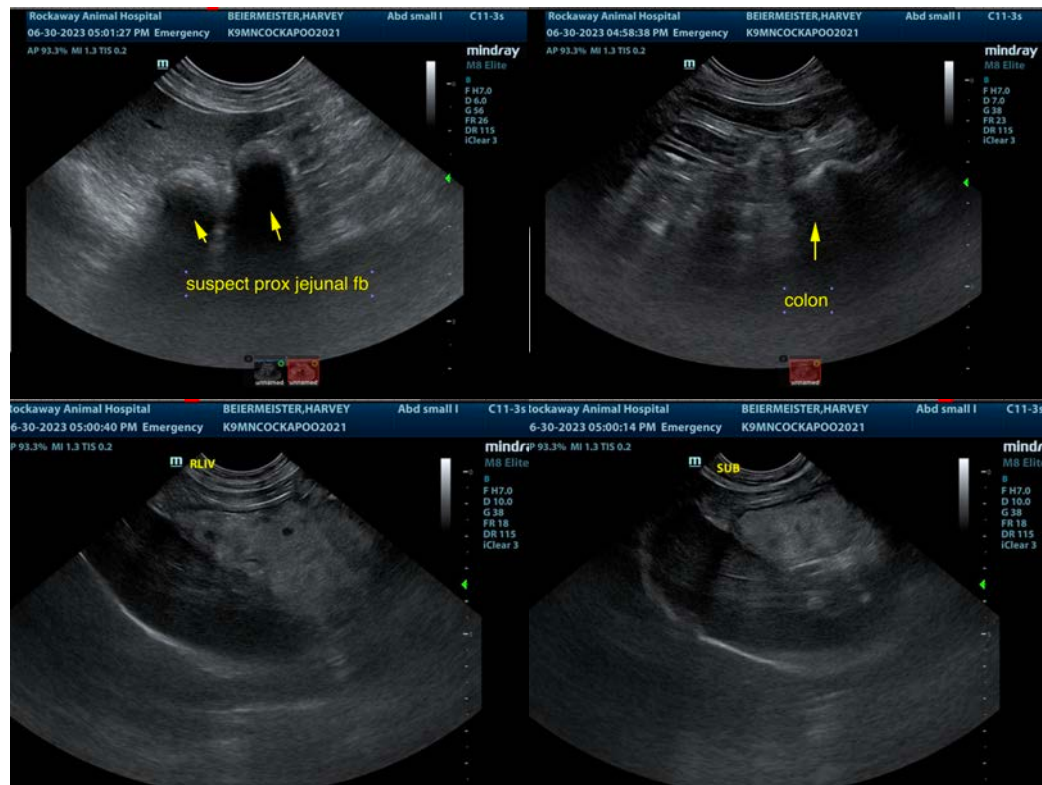
LIMITED ULTRASONOGRAPHIC EXAMINATION

Gastrointestinal

Persistent retention of ingesta noted in the stomach, consistent with chyme. The stomach was followed from the pylorus to the gastroesophageal inlet. Some shadowing material noted in the mid abdomen, appears to be distal duodenum or proximal jejunum followed by empty small intestine.

INTERPRETATION OF THE FINDINGS & FURTHER RECOMMENDATIONS

Given the gastric dilation and essentially empty colon at the level of the pelvic inlet, soft obstructive foreign matter in the small intestine is likely. This all presumes that the patient was completely NP prior to the sonogram. If the patient was NPO, then recheck sonogram just prior to surgery.



The information and recommendations provided are based on the images presented by the referring veterinarian/sonographer. No evaluation can be communicated regarding pathology that was not visible in the image/video clips provided.

Thank you for this referral. If the clinical or image interpretation does not parallel your findings or if I can be of any further assistance please contact me.

Eric Lindquist, DMV, DABVP, Cert. IVUSS, CEO of SonoPath.com

info@SonoPath.com