

**DATE PRESENTING CLINICAL SIGNS**

6/30/23 3/6 murmur; intermittent vomiting after meals; elevated liver values.

PATIENT Current Medications: Famotidine, Denamarin.
Lab Results: ALKP 2000.

Gunner Lovell Date of previous: No previous.
Sedation: Torb/Midaz
Stat Report: Not requested.

SPECIES

Canine

Imaging Performed By: Stephanie Warga RDCS, RVT.

BREED

Shih Tzu

ULTRASONOGRAPHIC EXAMINATION OF THE ABDOMEN**SEX**

Neutered Male

Urinary System

The **urinary bladder**, trigone, and pelvic urethra presented normal thicknesses and normal tone. The ureters were not visible which is normal. No uroliths or sediment were visualized and anechoic urine was present. No evidence of inflammatory or neoplastic changes were noted. Ureteral papillae were normal.

The residual prostate was uniform at 0.85 cm.

AGE

6/26/12

The **kidneys** revealed largely normal size and structure, corticomedullary definition and ratio (cortex 1/3 of medulla) were essentially maintained with some age-related loss of curvilinear patterns regarding the capsule and C/M junction. The cortices presented largely uniform texture with some increased echogenicity expected for his age patient. Medullary structure differed distinctly from that of the cortex and no evidence of pelvic dilation was present. The right kidney measured 4.73 cm. The left kidney measured 4.45 cm.

WEIGHT

19 Pounds

INTERPRETED BY

Eric Lindquist, DMV
DABVP, Cert. IVUSS

Adrenal Glands

The **adrenal glands** appeared slightly enlarged and swollen. No evidence of focal capsular expansion or invasion into the phrenic veins were noted. No overt suspicion of neoplasia was noted. This is considered likely a hyperplastic change associated with stress or adrenal endocrinopathy (PDH). If isosthenuria is persistently present and the patient morphologically suggests Cushing's disease then ACTH testing would be indicated. The right adrenal gland measured 1.97 cm x 0.57 cm at the caudal pole and 0.86 cm at the cranial pole. The left adrenal gland measured 2.19 cm x 0.76 cm at the caudal pole and 0.74 cm at the cranial pole.

HOSPITAL NAME

Banfield Abingdon

Spleen

The **spleen** revealed a focal hypoechoic nodule at the cranial pole measuring 0.87 cm x 0.46 cm.

REFERRING VET

Dr. Simpson

Liver

The **liver** was uniformly swollen with minor, excessive gallbladder debris and over distension with dependent and suspended bile without evidence of overt mucocele formation. However, excessive sludge was present. The liver presented coarse architecture with mildly increased portal markings and subtle, mixed echogenic changes. This is consistent with vacuolar hepatopathy and some level of remodeling and history of inflammatory component. There was no overt suspicion of neoplasia. Occasional hypoechoic non-disruptive nodule noted in the liver.

INVOICE

43674

Gastrointestinal

Examination of the **gastrointestinal tract** revealed a stomach and intestine free of stasis, of normal wall thickness, acceptable curvilinear mural detail, and peristaltic activity. Small and large intestine demonstrated normal luminal chyme and stool consistency respectively. No obstructive or overt infiltrative disease was noted. No associated abnormal lymphatic activity was noted.

Pancreas

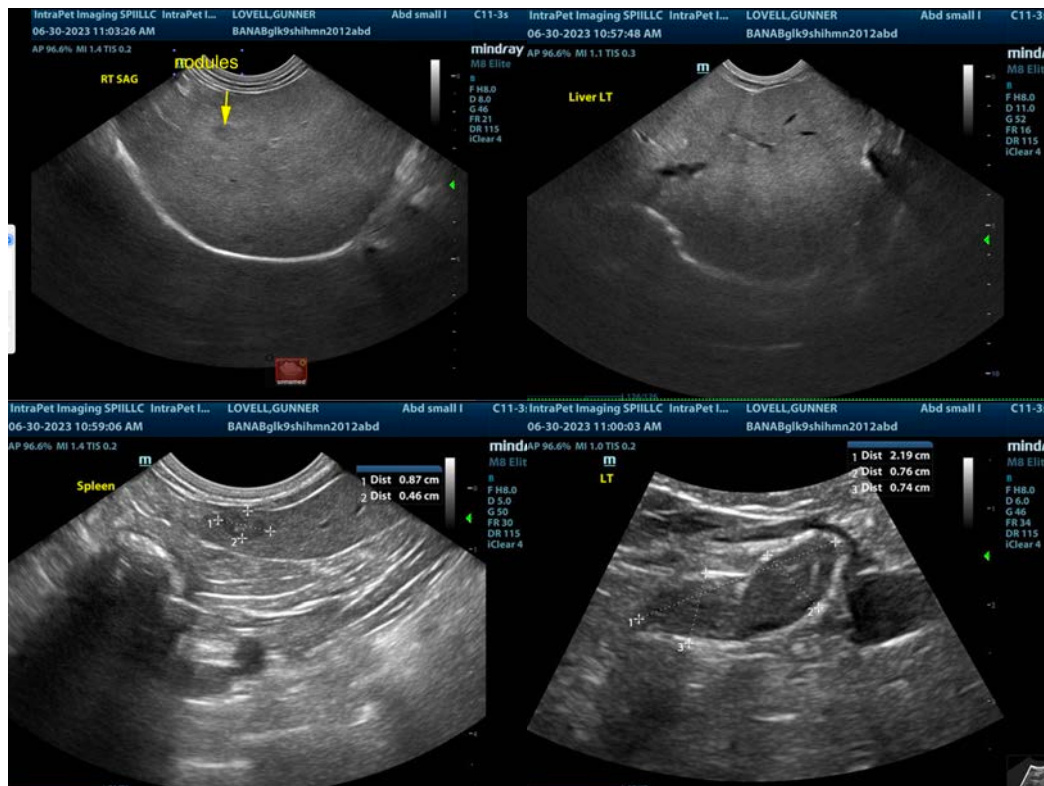
The base and limbs of the **pancreas** were observed to be largely isoechoic to surrounding omental fat. Pancreatic duct and capsular contour were acceptably normal and parenchyma respected normal curvilinear patterns. No overt evidence of active inflammatory or neoplastic disease was noted.

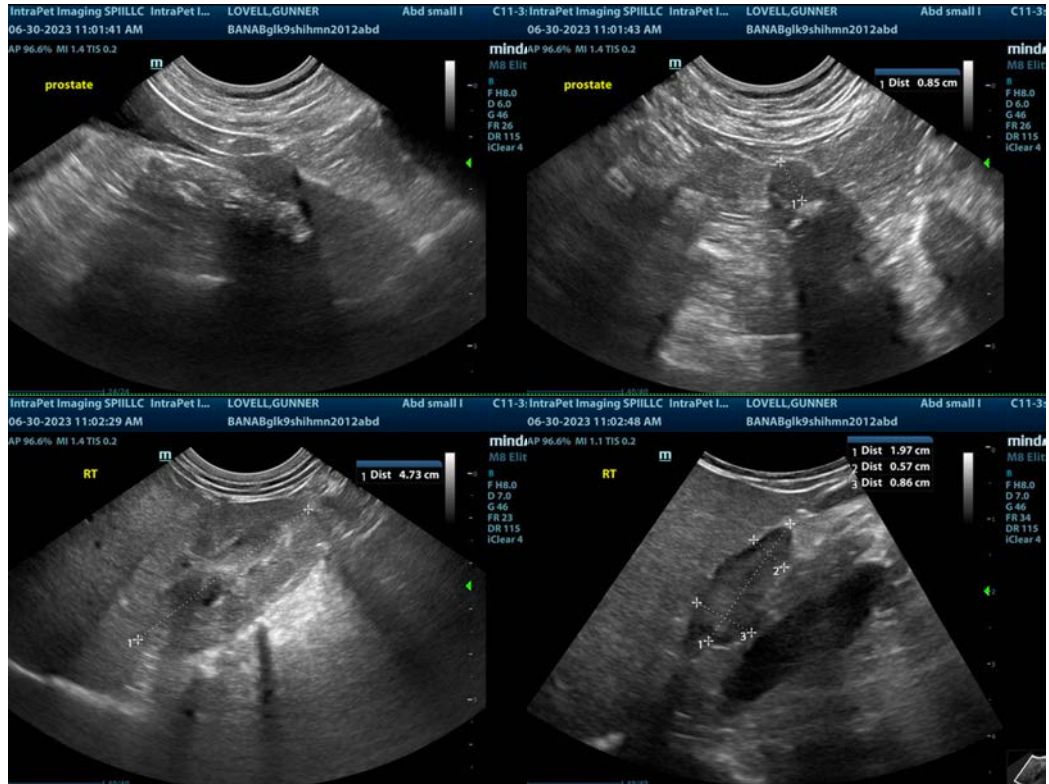
ULTRASONOGRAPHIC FINDINGS

- Mild bilateral adrenal hypertrophy
- Benign hepatopathy with occasional hypoechoic nodules
- Focal splenic nodule - Emerging round cell neoplasia, hyperplasia all possible.
- Age related renal changes

INTERPRETATION OF THE FINDINGS & FURTHER RECOMMENDATIONS

If the patient appears cushingoid, then workup for PH indicated. FNA of the splenic nodule indicated. FNA of the hepatic nodules would also be valid yet likely benign. No significant disruption of architecture.





The information and recommendations provided are based on the images presented by the referring veterinarian/sonographer. No evaluation can be communicated regarding pathology that was not visible in the image/video clips provided.

Thank you for this referral. If the clinical or image interpretation does not parallel your findings or if I can be of any further assistance please contact me.

Eric Lindquist, DMV, DABVP, Cert. IVUSS, CEO of SonoPath.com
info@SonoPath.com