



PATIENT

Bron McFarquhar

PRESENTING CLINICAL SIGNS

gastritis, gastric distention, vomiting

SPECIES

Canine

ULTRASONOGRAPHIC EXAMINATION OF THE ABDOMEN

Urinary System

The **urinary bladder**, trigone, and pelvic urethra presented normal thicknesses and normal tone. The ureters were not visible which is normal. No uroliths or sediment were visualized and anechoic urine was present. No evidence of inflammatory or neoplastic changes were noted. Ureteral papillae were normal.

BREED

Mastiff X

SEX

Neutered Male

The **kidneys** revealed normal size and structure, corticomedullary definition and ratio for this age. The cortices presented largely uniform texture with normal echogenic relationship to liver and spleen. Medullary structure differed distinctly from the cortex and no evidence of pelvic dilation was present. The capsules were acceptably uniform without significant irregularities. The right kidney measured 5.73 cm. The left kidney measured 6.21 cm.

AGE

3 Years

Adrenal Glands

Both **adrenal glands** were visualized and recognized as having normal shape, size, position and echogenicity for this breed. The phrenic vasculature, glandular echogenicity and detail were unremarkable. Capsule, cortex, and medullary definition were normal for this age patient. The right adrenal gland measured 2.67 cm x 0.68 cm at the caudal pole and 1.26 cm at the cranial pole. The left adrenal gland measured 2.81 cm x 0.78 cm at the caudal pole and 0.80 cm at the cranial pole.

WEIGHT

65.6 Pounds

Spleen

The **spleen** presented a smooth homogeneous parenchyma hyperechoic to liver and renal cortical parenchyma. The capsule was smooth without noticeable expansion or deviation from within the spleen or adjacent pathology. The splenic vasculature demonstrated normal volume without signs of congestion or thrombosis. No sonographic evidence of acute or chronic inflammatory, neoplastic, or infarctual changes were noted.

INTERPRETED BY

Eric Lindquist, DMV

DABVP, Cert. IVUSS

Liver

The **liver** presented normal size and contour with increased portal markings. The gallbladder and common bile duct were unremarkable. Hepatic vascularity was normal.

IMAGING PERFORMED BY

Jenn

HOSPITAL NAME

Rockaway AH

Gastrointestinal

Examination of the **gastrointestinal tract** revealed a stomach and intestine free of stasis, of normal wall thickness, acceptable curvilinear mural detail, and peristaltic activity. Small and large intestine demonstrated normal luminal chyme and stool consistency respectively. No obstructive or overt infiltrative disease was noted. No associated abnormal lymphatic activity was noted.

REFERRING VET

Dr. Maniar

Pancreas

The base and limbs of the **pancreas** were observed to be largely isoechoic to surrounding omental fat. Pancreatic duct and capsular contour were acceptably normal and parenchyma respected normal curvilinear patterns. No overt evidence of active inflammatory or neoplastic disease was noted.

INVOICE

39132

PRIMARY FINDINGS

DATE

6/30/22



PATIENT

Bron McFarquhar

- Mild hepatic remodeling, unremarkable abdomen otherwise

SPECIES

Canine

BREED

Mastiff X

SEX

Neutered Male

AGE

3 Years

WEIGHT

65.6 Pounds

INTERPRETED BY

Eric Lindquist, DMV

DABVP, Cert. IVUSS

IMAGING PERFORMED BY

Jenn

HOSPITAL NAME

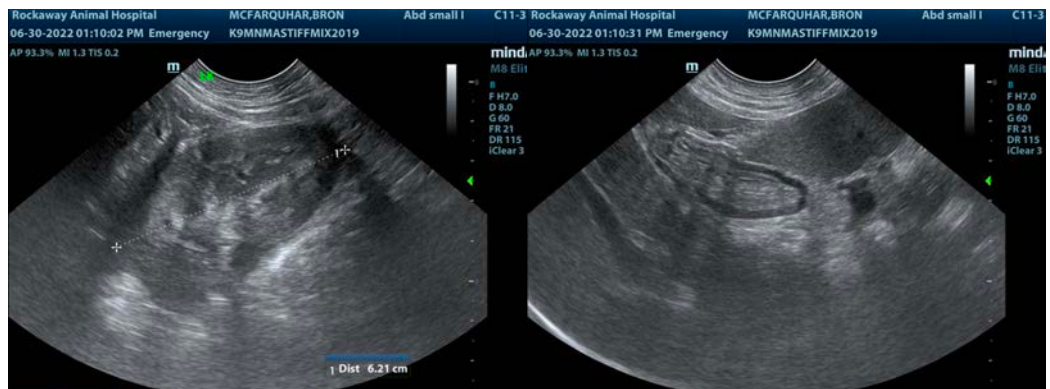
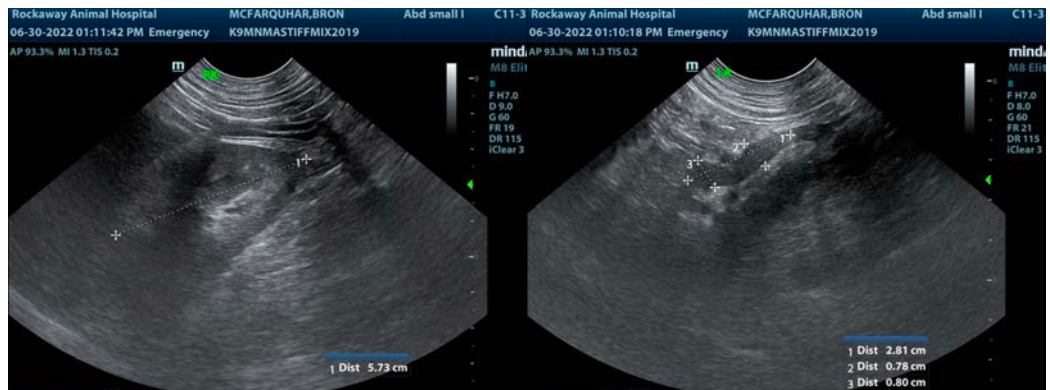
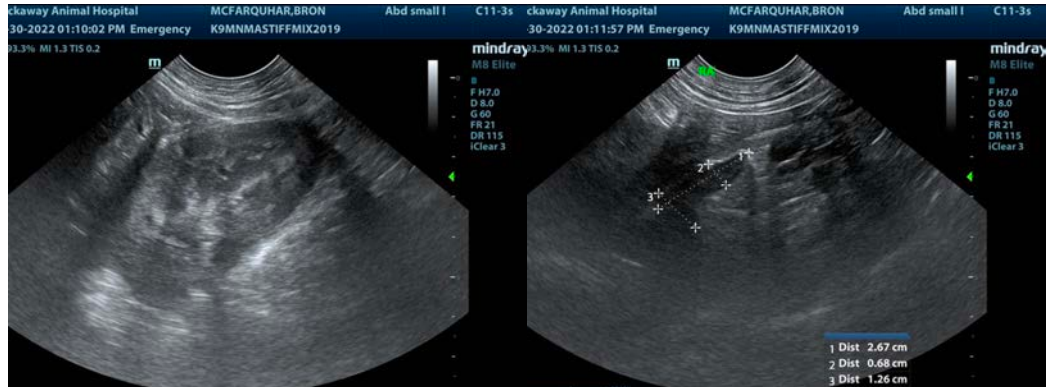
Rockway AH

REFERRING VET

Dr. Maniar

INTERPRETATION OF THE FINDINGS & FURTHER RECOMMENDATIONS

Supportive GI care should prove effective. If liver enzyme elevations are present, then FNA of the liver would be indicated, or core biopsy.



INVOICE

39132

DATE

6/30/22



PATIENT

Bron McFarquhar

SPECIES

Canine

BREED

Mastiff X

SEX

Neutered Male

AGE

3 Years

WEIGHT

65.6 Pounds

INTERPRETED BY

Eric Lindquist, DMV

DABVP, Cert. IVUSS

IMAGING PERFORMED BY

Jenn

HOSPITAL NAME

Rockaway AH

REFERRING VET

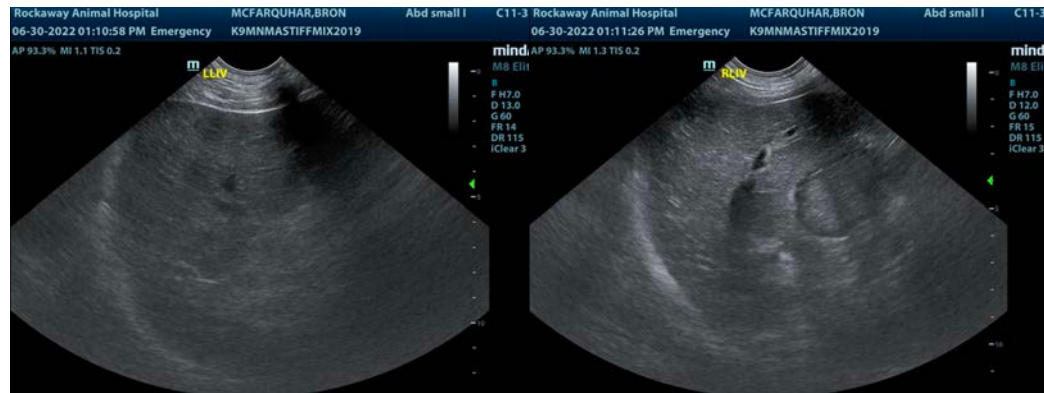
Dr. Maniar

INVOICE

39132

DATE

6/30/22



The information and recommendations provided are based on the images presented by the referring veterinarian/sonographer. No evaluation can be communicated regarding pathology that was not visible in the image/video clips provided.

Thank you for this referral. If the clinical or image interpretation does not parallel your findings or if I can be of any further assistance please contact me.

Eric Lindquist, DMV, DABVP, Cert. IVUSS, CEO of SonoPath.com

info@SonoPath.com