



PATIENT

Maggie DosSantos

SPECIES

Canine

BREED

Chihuahua

SEX

Female

AGE

10 Years

WEIGHT

3.92 kg

INTERPRETED BY

Eric Lindquist, DMV,
DABVP(CFM), Cert.
IVUSS

IMAGING PERFORMED BY

Dr. Laura De Cordon

HOSPITAL NAME

Lakeview Animal
Hospital

REFERRING VET

Dr. Laura De Cordon

INVOICE

16279

DATE

06/03/26

PRESENTING CLINICAL SIGNS

P presents as a new patient with chronic diarrhea for the past 3-4 months that has been treated with various medications and diet changes. Patients fecal have been normal. Mild ALT elevation, other BW values normal

ULTRASONOGRAPHIC EXAMINATION OF THE ABDOMEN

Urinary System

The **urinary bladder**, trigone, and pelvic urethra to a depth of 2.0 cm presented normal thicknesses and normal tone. The ureters were not visible which is normal. No uroliths or sediment were visualized, and anechoic urine was present. No evidence of inflammatory or neoplastic changes were noted. Ureteral papillae were normal.

The **kidneys** revealed normal size and structure, corticomedullary definition and ratio for this age. The cortices presented largely uniform texture with normal echogenic relationship to liver and spleen. Medullary structure differed distinctly from the cortex and no evidence of pelvic dilation was present. The capsules were acceptably uniform without significant irregularities. The left kidney measured 3.38 cm in length. The right kidney measured 3.66 cm in length.

Adrenal Glands

Both **adrenal glands** were visualized and recognized as having normal shape, size, position and echogenicity for this breed. The phrenic vasculature, glandular echogenicity and detail were unremarkable. Capsule, cortex, and medullary definition were normal for this age patient. The left adrenal gland measured 0.36 cm width. The right adrenal gland measured 0.36 cm width.

Spleen

The **spleen** presented a smooth homogeneous parenchyma hyperechoic to liver and renal cortical parenchyma. The capsule was smooth without noticeable expansion or deviation from within the spleen or adjacent pathology. The splenic vasculature demonstrated normal volume without signs of congestion or thrombosis. No sonographic evidence of acute or chronic inflammatory, neoplastic, or infarctual changes were noted.

Liver

The **liver** revealed multifocal hypoechoic nodular changes with coarse parenchymal architecture. The gallbladder and common bile duct were unremarkable.

Gastrointestinal

Examination of the **gastrointestinal tract** revealed a stomach and intestine free of stasis, of normal wall thickness, acceptable curvilinear mural detail, and peristaltic activity. Small and large intestine demonstrated normal luminal chyme and stool consistency respectively. No obstructive or overt infiltrative disease was noted. No associated abnormal lymphatic activity was noted.

Pancreas

The base and limbs of the **pancreas** were observed to be largely isoechoic to surrounding omental fat. Some mild parenchymal remodeling, however, with mild deviation from curvilinear normalcy was observed. Pancreatic duct and capsular irregularities were present consistent with age related



PATIENT

Maggie DosSantos

SPECIES

Canine

BREED

Chihuahua

SEX

Female

AGE

10 Years

WEIGHT

3.92 kg

INTERPRETED BY

Eric Lindquist, DMV,
DABVP(CFM), Cert.
IVUS

IMAGING PERFORMED BY

Dr. Laura De Cordon

HOSPITAL NAME

Lakeview Animal
Hospital

REFERRING VET

Dr. Laura De Cordon

INVOICE

16279

DATE

06/03/26

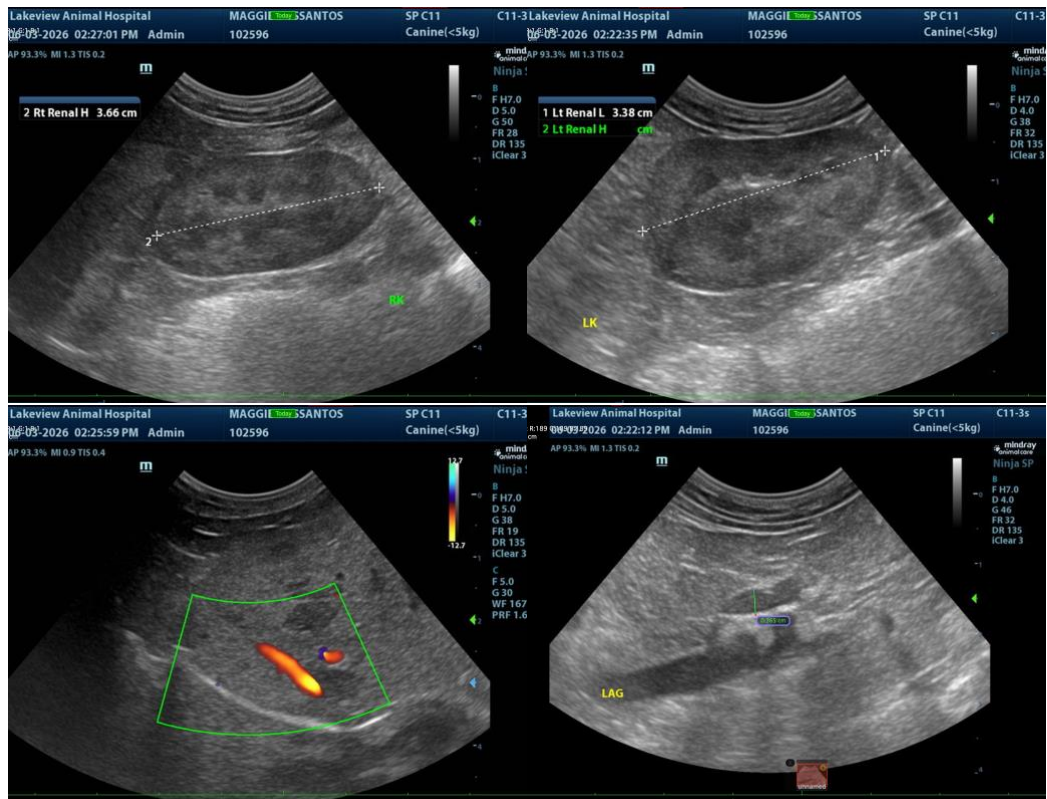
changes. If pain upon imaging (+ Murphy sign) was present or if the patient is focally painful in subxiphoid palpation then low-grade smoldering chronic pancreatitis should be suspected.

ULTRASONOGRAPHIC FINDINGS

- Nodular hyperplasia liver pattern with moderate amount of remodeling.
- Unremarkable geriatric abdomen otherwise.

INTERPRETATION OF THE FINDINGS & FURTHER RECOMMENDATIONS

FNA is indicated of the general hepatic parenchyma and nodular changes. Bile acid profile would be ideal. No evidence of gross pathology.





PATIENT

Maggie DosSantos

SPECIES

Canine

BREED

Chihuahua

SEX

Female

AGE

10 Years

WEIGHT

3.92 kg

INTERPRETED BY

Eric Lindquist, DMV,
DABVP(CFM), Cert.
IVUSS

IMAGING PERFORMED BY

Dr. Laura De Cordon

HOSPITAL NAME

Lakeview Animal
Hospital

REFERRING VET

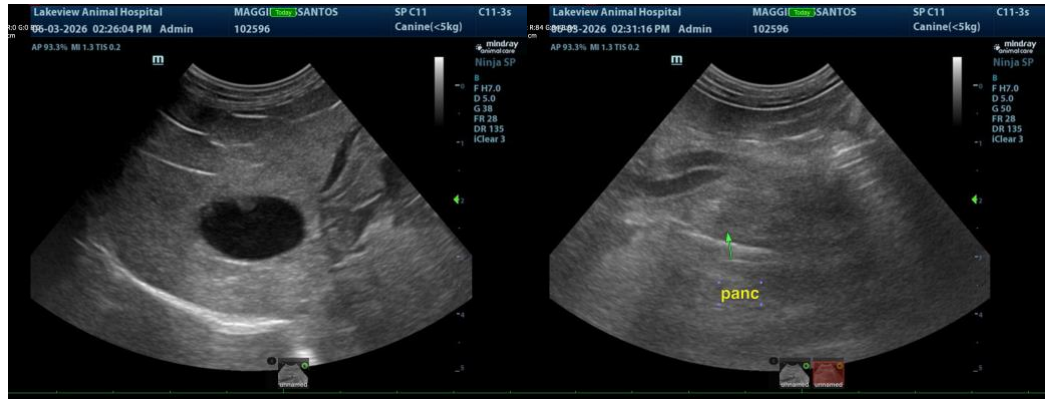
Dr. Laura De Cordon

INVOICE

16279

DATE

06/03/26



The information and recommendations provided are based on the images presented by the referring veterinarian/sonographer. No evaluation can be communicated regarding pathology that was not visible in the image/video clips provided.

Thank you for this referral. If the clinical or image interpretation does not parallel your findings or if I can be of any further assistance, please contact me.

Eric Lindquist, DMV, DABVP(CFM), Cert. IVUSS,

CEO, Owner, Founder -- SonoPath.com

info@SonoPath.com