



PATIENT

Louis Draper

SPECIES

Canine

BREED

Poodle

SEX

Neutered male

AGE

5 years

WEIGHT

53.2 lbs

INTERPRETED BY

Eric Lindquist, DMV
DABVP, Cert. IVUSS

IMAGING PERFORMED BY

Amy Capraro

HOSPITAL NAME

Braintree VC

REFERRING VET

Dr. Capraro

INVOICE

78336

DATE

6/3/26

PRESENTING CLINICAL SIGNS

History: Patient presented 5/25/26 to ER for single episode of hematuria. ER did rads, labs and culture which was all negative/normal. Sent home on clavamox and gabapentin x 7 days. Recommend AUS to rule out other issues. Presented for urinary check.

ULTRASONOGRAPHIC EXAMINATION OF THE ABDOMEN

Urinary System

The **urinary bladder**, trigone, and pelvic urethra presented normal thicknesses and normal tone. The ureters were not visible which is normal. No uroliths or sediment were visualized and anechoic urine was present. No evidence of inflammatory or neoplastic changes was noted. Ureteral papillae were normal.

The **kidneys** revealed normal size and structure, corticomedullary definition and ratio for this age. The cortices presented largely uniform texture with normal echogenic relationship to liver and spleen. Medullary structure differed distinctly from the cortex and no evidence of pelvic dilation was present. The capsules were acceptably uniform without significant irregularities. The left kidney measured 5.1 cm. The right kidney measured 5.9 cm.

The iliac trifurcation was unremarkable.

Adrenal Glands

The **left adrenal gland** was visualized and recognized as having normal shape, size, position and echogenicity for this breed. The phrenic vasculature, glandular echogenicity and detail were unremarkable. Capsule, cortex, and medullary definition were normal for this age patient. The left adrenal gland measured 0.6 cm. The **right adrenal gland** was not visualized.

Spleen

The **spleen** presented a smooth homogeneous parenchyma hyperechoic to liver and renal cortical parenchyma. The capsule was smooth without noticeable expansion or deviation from within the spleen or adjacent pathology. The splenic vasculature demonstrated normal volume without signs of congestion or thrombosis. No sonographic evidence of acute or chronic inflammatory, neoplastic, or infarctual changes was noted.

Liver

The **liver** images submitted revealed subjectively normal liver size, contour, and structure. Parenchymal echogenicity was naturally coarse and hypoechoic to the spleen. Vascular and biliary tracts were of normal volume with no evidence of congestion. The gallbladder presented acceptably thin walls with primarily anechoic content. The cystic and common bile ducts were normal. No pathological hepatic



PATIENT

lymphadenopathy was evident. No overt structural evidence of inflammatory, infiltrative or regenerative pathology was evident.

Louis Draper

SPECIES

Gastrointestinal

Canine

Examination of the **gastrointestinal tract** revealed a stomach and intestine free of stasis, of normal wall thickness, acceptable curvilinear mural detail, and peristaltic activity. The stomach revealed a minor amount of floating chyme filled lumen. Small and large intestine demonstrated normal luminal chyme and stool consistency respectively. No obstructive or overt infiltrative disease was noted. No associated abnormal lymphatic activity was noted.

BREED

Poodle

SEX

Neutered male

Pancreas

AGE

The base and limbs of the **pancreas** were observed to be largely isoechoic to surrounding omental fat. Pancreatic duct and capsular contour were acceptably normal and parenchyma respected normal curvilinear patterns. No overt evidence of active inflammatory or neoplastic disease was noted.

5 years

WEIGHT

53.2 lbs

ULTRASONOGRAPHIC FINDINGS

INTERPRETED BY

Structurally unremarkable abdomen.

Eric Lindquist, DMV
DABVP, Cert. IVUSS

INTERPRETATION OF THE FINDINGS & FURTHER RECOMMENDATIONS

IMAGING PERFORMED BY

I cannot rule out pathology in the deep pelvic urethra such as prostatic or urethral disease. Underlying occult UTI, deep urethral pathology, coagulopathy and idiopathic hematuria are all potentials in this patient.

Amy Capraro

HOSPITAL NAME

Braintree VC

REFERRING VET

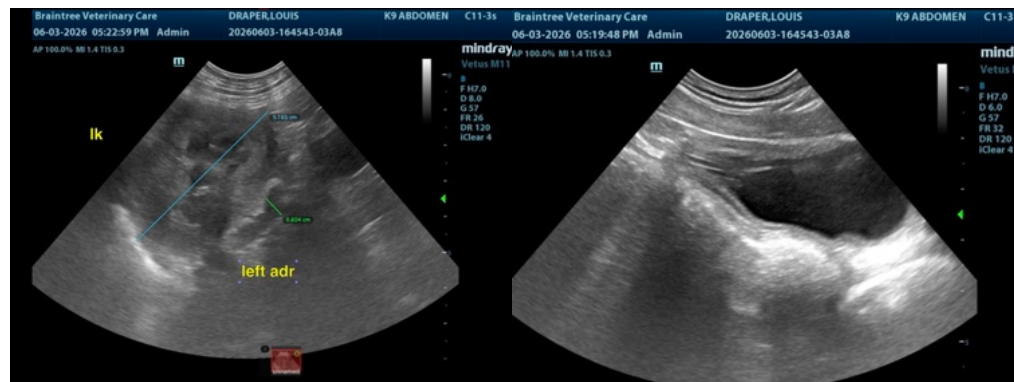
Dr. Capraro

INVOICE

78336

DATE

6/3/26





PATIENT

Louis Draper

SPECIES

Canine

BREED

Poodle

SEX

Neutered male

AGE

5 years

WEIGHT

53.2 lbs

INTERPRETED BY

Eric Lindquist, DMV
DABVP, Cert. IVUSS

IMAGING PERFORMED BY

Amy Capraro

HOSPITAL NAME

Braintree VC

REFERRING VET

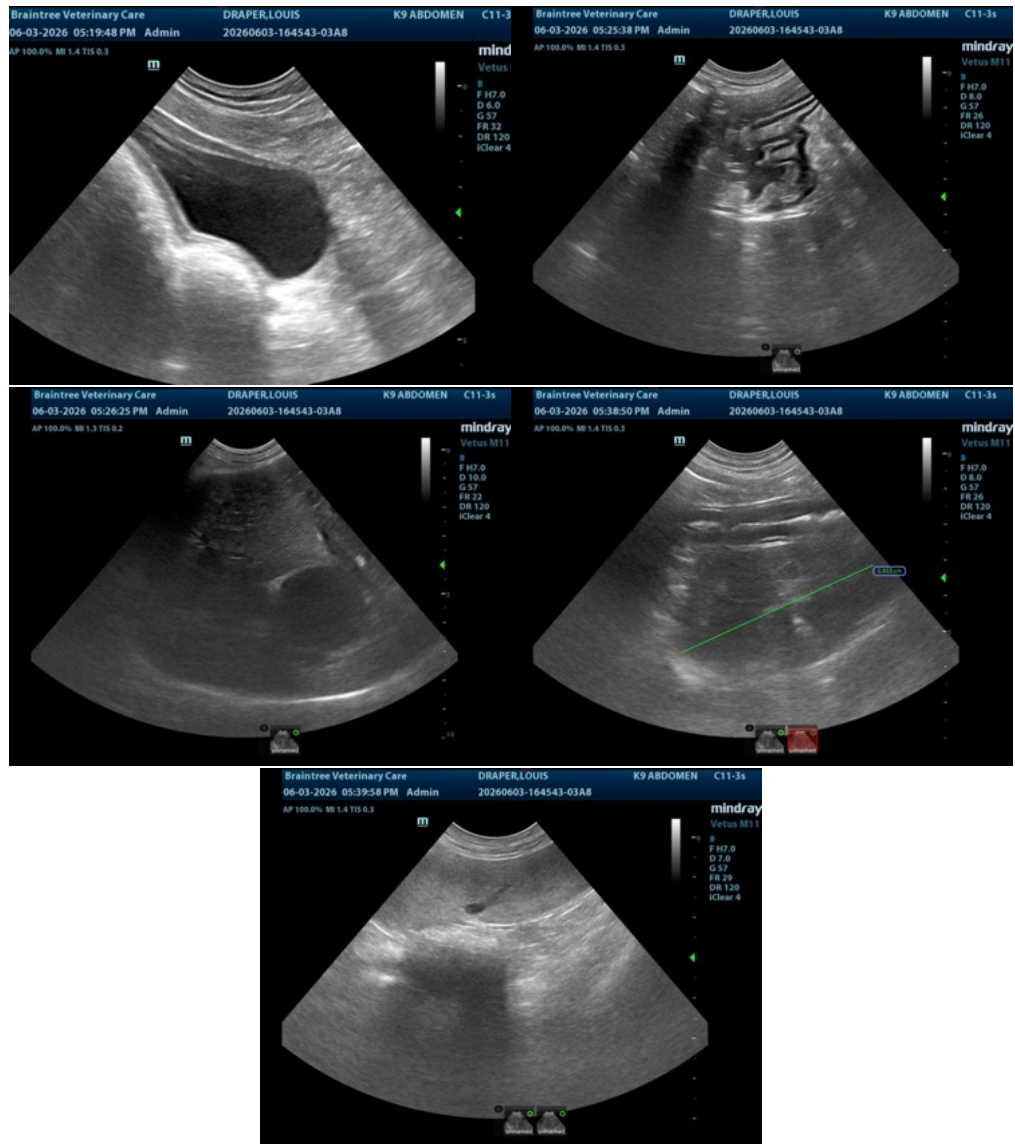
Dr. Capraro

INVOICE

78336

DATE

6/3/26



The information and recommendations provided are based on the images presented by the referring veterinarian/sonographer. No evaluation can be communicated regarding pathology that was not visible in the image/video clips provided.

Thank you for this referral. If the clinical or image interpretation does not parallel your findings or if I can be of any further assistance please contact me.

Eric Lindquist, DMV, DABVP (CFM), Cert. IVUSS, CEO of SonoPath.com

info@SonoPath.com