



PATIENT

Boba Kohly

SPECIES

Feline

BREED

DSH

SEX

Neutered Male

AGE

7 Years

WEIGHT

7.58 kg

INTERPRETED BY

Eric Lindquist, DMV,
DABVP(CFM), Cert.
IVUSS

IMAGING PERFORMED BY

Dr. Singh

HOSPITAL NAME

Balmy Beach Pet
Hospital

REFERRING VET

Dr. Singh

INVOICE

13607

DATE

06/03/26

PRESENTING CLINICAL SIGNS

Vomiting over the past week or so. Not eating canned food, still eating dry food. Not hiding and not lethargic.

Abnormal PE/Chem/CBC/UA Results: CBC shows mild reticulocytosis Chemistry shows elevated globulins

ULTRASONOGRAPHIC EXAMINATION OF THE ABDOMEN

Urinary System

The **urinary bladder**, trigone, and pelvic urethra presented normal thicknesses and normal tone. The ureters were not visible which is normal. No uroliths or sediment were visualized, and anechoic urine was present. No evidence of inflammatory or neoplastic changes were noted. Ureteral papillae were normal.

The **kidneys** revealed normal size and structure, corticomedullary definition and ratio for this age. The cortices presented largely uniform texture with normal echogenic relationship to liver and spleen. Medullary structure differed distinctly from the cortex and no evidence of pelvic dilation was present. The capsules were acceptably uniform without significant irregularities. The left kidney measured 4.3 cm in length. The right kidney measured 4.5 cm in length.

Adrenal Glands

Both **adrenal glands** were visualized and recognized as having normal shape, size, position and echogenicity for this breed. The phrenic vasculature, glandular echogenicity and detail were unremarkable. Capsule, cortex, and medullary definition were normal for this age patient. The left adrenal gland measured 0.3 cm width. The right adrenal gland measured 0.3 cm width.

Spleen

The **spleen** presented a smooth homogeneous parenchyma hyperechoic to liver and renal cortical parenchyma. The capsule was smooth without noticeable expansion or deviation from within the spleen or adjacent pathology. The splenic vasculature demonstrated normal volume without signs of congestion or thrombosis. No sonographic evidence of acute or chronic inflammatory, neoplastic, or infarctual changes were noted. The spleen measured 0.97 cm width.

Liver

The **liver** images submitted revealed subjectively normal liver size, contour, and structure. Parenchymal echogenicity was naturally coarse and hypoechoic to the spleen. Vascular and biliary tracts were of normal volume with no evidence of congestion. The gallbladder presented acceptably thin walls with primarily anechoic content. The cystic and common bile ducts were normal. No pathological hepatic lymphadenopathy was evident. No overt structural evidence of inflammatory, infiltrative or regenerative pathology was evident.

Gastrointestinal

There was some residual chyme and gas was noted in the **stomach**, yet not pathological. This is consistent with end post prandial presentation. The small intestine and colon were unremarkable.

Pancreas



PATIENT

Boba Kohly

SPECIES

Feline

BREED

DSH

SEX

Neutered Male

AGE

7 Years

WEIGHT

7.58 kg

INTERPRETED BY

Eric Lindquist, DMV,
DABVP(CFM), Cert.
IVUSS

IMAGING PERFORMED BY

Dr. Singh

HOSPITAL NAME

Balmy Beach Pet
Hospital

REFERRING VET

Dr. Singh

INVOICE

13607

DATE

06/03/26

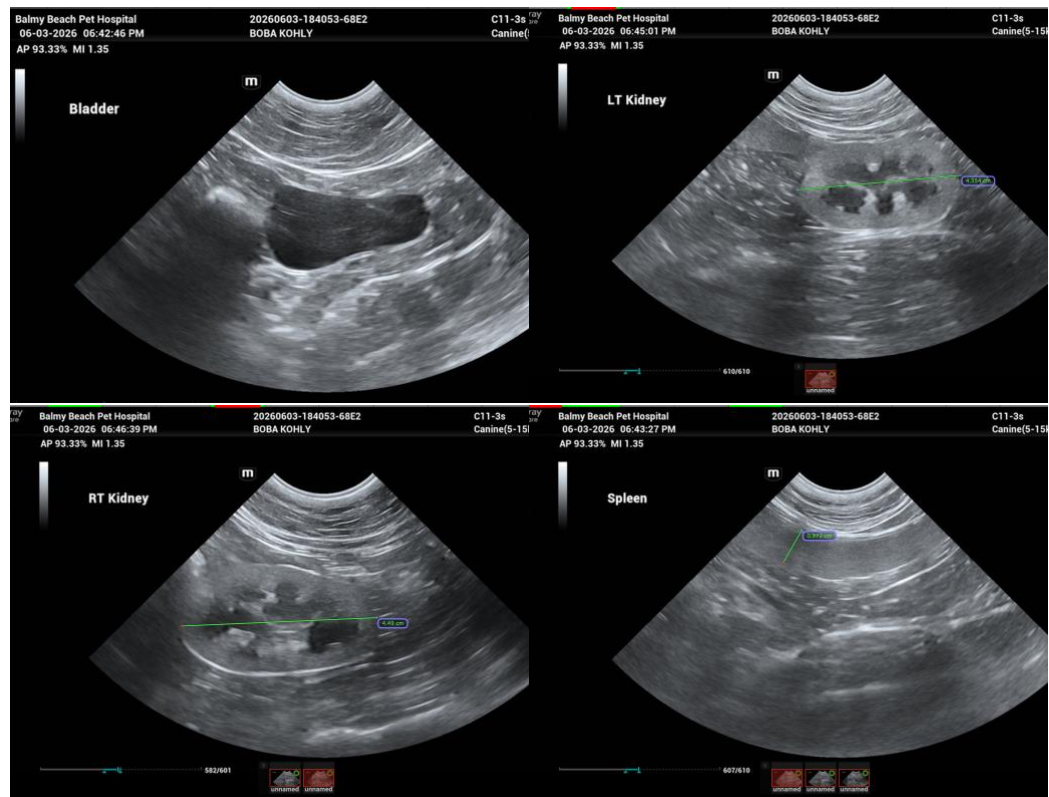
The base and limbs of the **pancreas** were observed to be largely isoechoic to surrounding omental fat. Pancreatic duct and capsular contour were acceptably normal and parenchyma respected normal curvilinear patterns. No overt evidence of active inflammatory or neoplastic disease was noted.

ULTRASONOGRAPHIC FINDINGS

- Structurally unremarkable abdomen.

INTERPRETATION OF THE FINDINGS & FURTHER RECOMMENDATIONS

No evidence of visceral pathology. Potential delayed outflow given the elevated globulins. FNA of the spleen could be considered for further definition.





PATIENT

Boba Kohly

SPECIES

Feline

BREED

DSH

SEX

Neutered Male

AGE

7 Years

WEIGHT

7.58 kg

INTERPRETED BY

Eric Lindquist, DMV,
DABVP(CFM), Cert.
IVUSS

IMAGING PERFORMED BY

Dr. Singh

HOSPITAL NAME

Balmy Beach Pet
Hospital

REFERRING VET

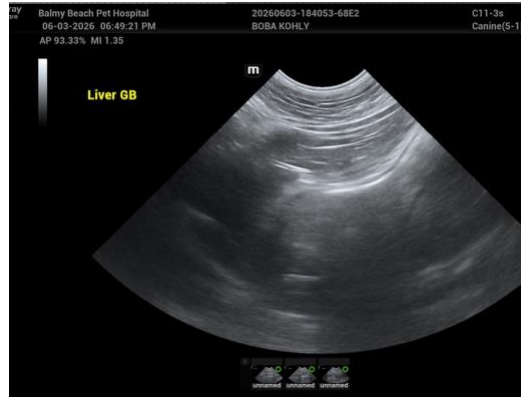
Dr. Singh

INVOICE

13607

DATE

06/03/26



The information and recommendations provided are based on the images presented by the referring veterinarian/sonographer. No evaluation can be communicated regarding pathology that was not visible in the image/video clips provided.

Thank you for this referral. If the clinical or image interpretation does not parallel your findings or if I can be of any further assistance, please contact me.

Eric Lindquist, DMV, DABVP(CFM), Cert. IVUSS,

CEO, Owner, Founder -- SonoPath.com

info@SonoPath.com