



PATIENT

Zoie Fedele

PRESENTING CLINICAL SIGNS

Recheck echo, last one performed on 4/29/22. Owner reports patient is improved on current meds. Current meds: Vetmedin, Enalapril, Spironolactone, and furosemide.

SPECIES

Canine

ULTRASONOGRAPHIC EXAMINATION OF THE HEART

BREED

Maltese

SEX

Spayed Female

AGE

15 Years

WEIGHT

9.9 Pounds

CANINE CARDIAC PARAMETERS	MR VMAX (m/s)	TR VMAX (m/s)	LA/AO (Boon method)	LA/AO (Heart Base; Swe)	FS (%)	EF (%)	EPSS (cm)
NORMAL PARAMETER	4.5-5.5	<2.7	1.3	<1.6	28-40	40-100	<0.6
PATIENT	5.8		NM	>2.5	44	77	0.1
CANINE CARDIAC PARAMETERS	HR (BPM)	AV VMAX (m/s)	PV MAX (m/s)	BODY WEIGHT (kg)	LA 2D short axis Base view (cm)	LVIDd Avg; 2D and m-mode short axis (cm)	LVIDs Avg; 2D and m-mode short axis (cm)
NORMAL PARAMETER	50-100	0.7-1.7	0.7-1.6	BELOW	BELOW	BELOW	BELOW
PATIENT	124	1.28	0.96		5.08	3.38	

Cardiac Presentation

The cardiac presentation revealed persistent severe volume overload of the left atrium and left ventricle with flail mitral valve. Tricuspid insufficiency also noted with arrhythmogenic activity. Hepatic veins were dilated, consistent with passive congestion.

INTERPRETED BY

Eric Lindquist, DMV

DABVP, Cert. IVUSS

ULTRASONOGRAPHIC FINDINGS

- C1-D1 valvular disease

IMAGING PERFORMED BY

Kelly Vazquez

INTERPRETATION OF THE FINDINGS & FURTHER RECOMMENDATIONS

HOSPITAL NAME

Parsippany AH

Recommend adding medication in this patient to the current protocol, increasing Lasix to 3-4 mg/kg BID, Vetmedin to 0.3 mg/kg TID, maxing out ACE inhibitor at 0.5 mg/kg BID, and continuing Spironolactone. This patient is at high risk for sudden death. Prognosis is poor.

REFERRING VET

Dr. Dulude

Torseamide rescue therapy can be considered with attentive dose management in respect to renal/urinary side effects.

INVOICE

38364

DATE

6/3/22



PATIENT

Zoie Fedele

SPECIES

Canine

BREED

Maltese

SEX

Spayed Female

AGE

15 Years

WEIGHT

9.9 Pounds

INTERPRETED BY

Eric Lindquist, DMV
DABVP, Cert. IVUS

IMAGING PERFORMED BY

Kelly Vazquez

HOSPITAL NAME

Parsippany AH

REFERRING VET

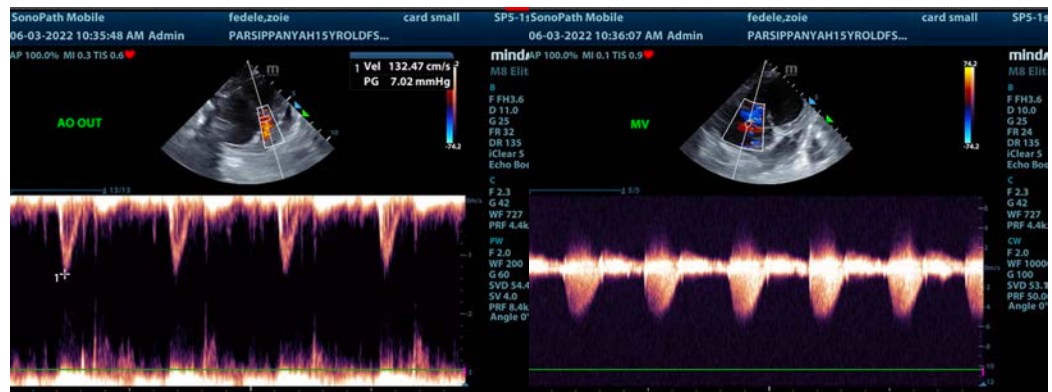
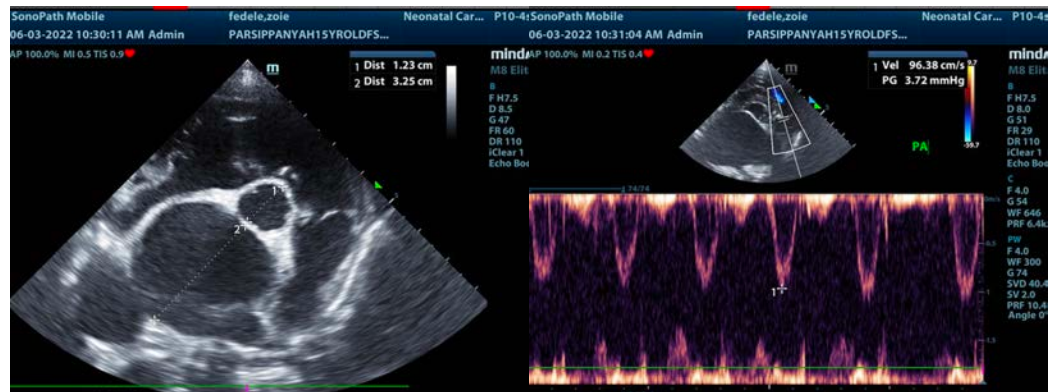
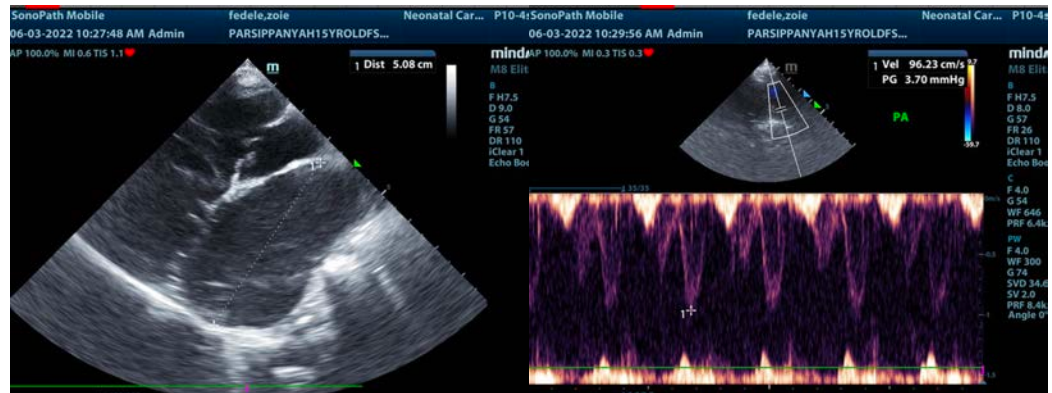
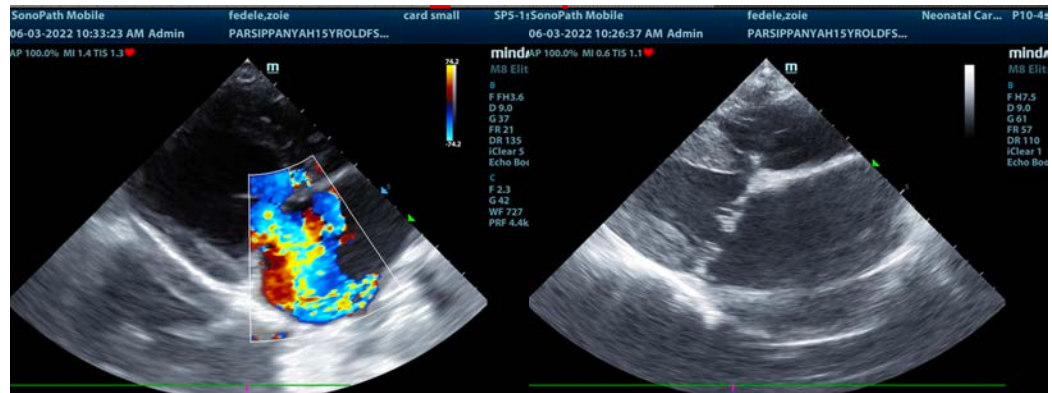
Dr. Dulude

INVOICE

38364

DATE

6/3/22





PATIENT

Zoie Fedele

SPECIES

Canine

BREED

Maltese

SEX

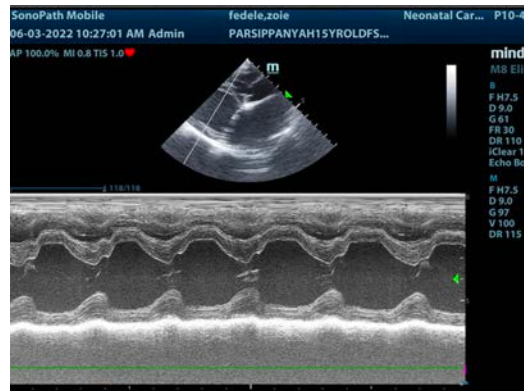
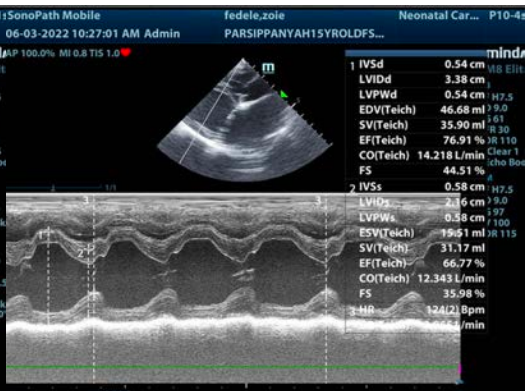
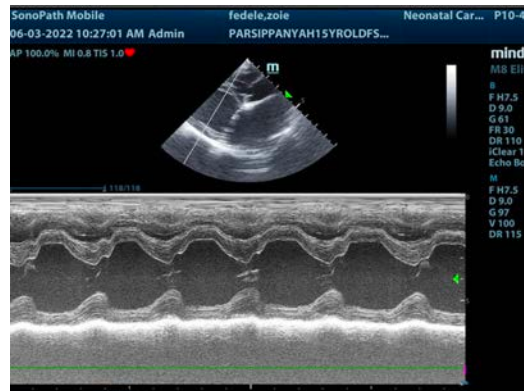
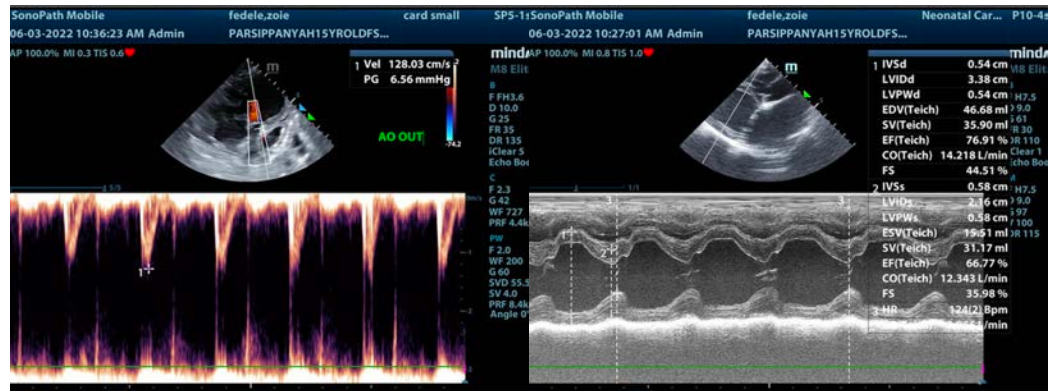
Spayed Female

AGE

15 Years

WEIGHT

9.9 Pounds



INTERPRETED BY

Eric Lindquist, DMV

DABVP, Cert. IVUSS

IMAGING PERFORMED BY

Kelly Vazquez

HOSPITAL NAME

Parsippany AH

REFERRING VET

Dr. Dulude

INVOICE

38364

DATE

6/3/22

The information and recommendations provided are based on the images presented by the referring veterinarian/sonographer. No evaluation can be communicated regarding pathology that was not visible in the image/video clips provided.

Thank you for this referral. If the clinical or image interpretation does not parallel your findings or if I can be of any further assistance please contact me.

Eric Lindquist, DMV, DABVP, Cert. IVUSS, CEO of SonoPath.com

info@SonoPath.com