



PATIENT

Padfoot McDermott

SPECIES

Feline

BREED

DSH

SEX

Spayed Female

AGE

4 Years

WEIGHT

9.5 Pounds

INTERPRETED BY

Eric Lindquist, DMV

DABVP, Cert. IVUSS

IMAGING PERFORMED BY

Dr. Karen Fowler

HOSPITAL NAME

Portland Veterinary Wellness Center

REFERRING VET

Dr. Karen Fowler

INVOICE

38379

DATE

6/3/22

PRESENTING CLINICAL SIGNS

Exam for v ongoing since last visit in January. At that time presented for softer stools with blood present and intermittent. At that time performed fecal, probiotic and gave profendor dewormer. V after eating especially if given too much. only able to hold down 10kibbles and 1 tsp of wets food. Constantly hungry Switched to grain free diet, tiny bits of wet food No D/S/C Drinking normal 1 other cat in home indoor/outdoor - keeping inside lately no meds had dewormer last time
Abnormal PE/Chem/CBC/UA Results: Decrease in weight from 11.89 lbs in January 2022 to 9.5 lbs GI malabsorption profile and UA pending

ULTRASONOGRAPHIC EXAMINATION OF THE ABDOMEN

Urinary System

The **urinary bladder**, trigone, and pelvic urethra presented normal thicknesses and normal tone. The ureters were not visible which is normal. No uroliths or sediment were visualized and anechoic urine was present. No evidence of inflammatory or neoplastic changes were noted. Ureteral papillae were normal. The pelvic urethra was imaged 1.0 cm beyond the cystourethral junction.

The **kidneys** revealed normal size and structure, corticomedullary definition and ratio for this age. The cortices presented largely uniform texture with normal echogenic relationship to liver and spleen. Medullary structure differed distinctly from the cortex and no evidence of pelvic dilation was present. The capsules were acceptably uniform without significant irregularities. The left kidney measured 3.5 cm. The right kidney measured 3.5 cm.

Adrenal Glands

The **left adrenal gland** was visualized and recognized as having normal shape, size, position and echogenicity for this breed. The phrenic vasculature, glandular echogenicity and detail were unremarkable. Capsule, cortex, and medullary definition were normal for this age patient. The left adrenal gland measured 0.40 cm.

The area of the **right adrenal gland** was unremarkable.

Spleen

The **spleen** presented a smooth homogeneous parenchyma hyperechoic to liver and renal cortical parenchyma. The capsule was smooth without noticeable expansion or deviation from within the spleen or adjacent pathology. The splenic vasculature demonstrated normal volume without signs of congestion or thrombosis. No sonographic evidence of acute or chronic inflammatory, neoplastic, or infarctual changes were noted.

Liver

The **liver** images submitted revealed subjectively normal liver size, contour, and structure. Parenchymal echogenicity was naturally coarse and hypoechoic to the spleen. Vascular and biliary tracts were of normal volume with no evidence of congestion. The gallbladder presented acceptably thin walls with primarily anechoic content. The cystic and common bile ducts were normal. No pathological hepatic lymphadenopathy was evident. No overt structural evidence of inflammatory, infiltrative or regenerative pathology was evident.

Gastrointestinal

Examination of the **gastrointestinal tract** revealed a stomach and intestine free of stasis, of normal wall thickness, acceptable curvilinear mural detail, and peristaltic activity. Small and large intestine



PATIENT

Padfoot McDermott

demonstrated normal luminal chyme and stool consistency respectively. No obstructive or overt infiltrative disease was noted. No associated abnormal lymphatic activity was noted.

Pancreas

SPECIES

Feline

The base and limbs of the **pancreas** were observed to be largely isoechoic to surrounding omental fat. Pancreatic duct and capsular contour were acceptably normal and parenchyma respected normal curvilinear patterns. No overt evidence of active inflammatory or neoplastic disease was noted.

BREED

DSH

ULTRASONOGRAPHIC FINDINGS

- Structurally normal abdomen

SEX

Spayed Female

INTERPRETATION OF THE FINDINGS & FURTHER RECOMMENDATIONS

No evidence of pathology. Structurally insignificant inflammatory bowel, malassimilation, dietary intolerance, occult parasitism all potentials in this case.

AGE

4 Years

WEIGHT

9.5 Pounds

INTERPRETED BY

Eric Lindquist, DMV

DABVP, Cert. IVUSS

IMAGING PERFORMED BY

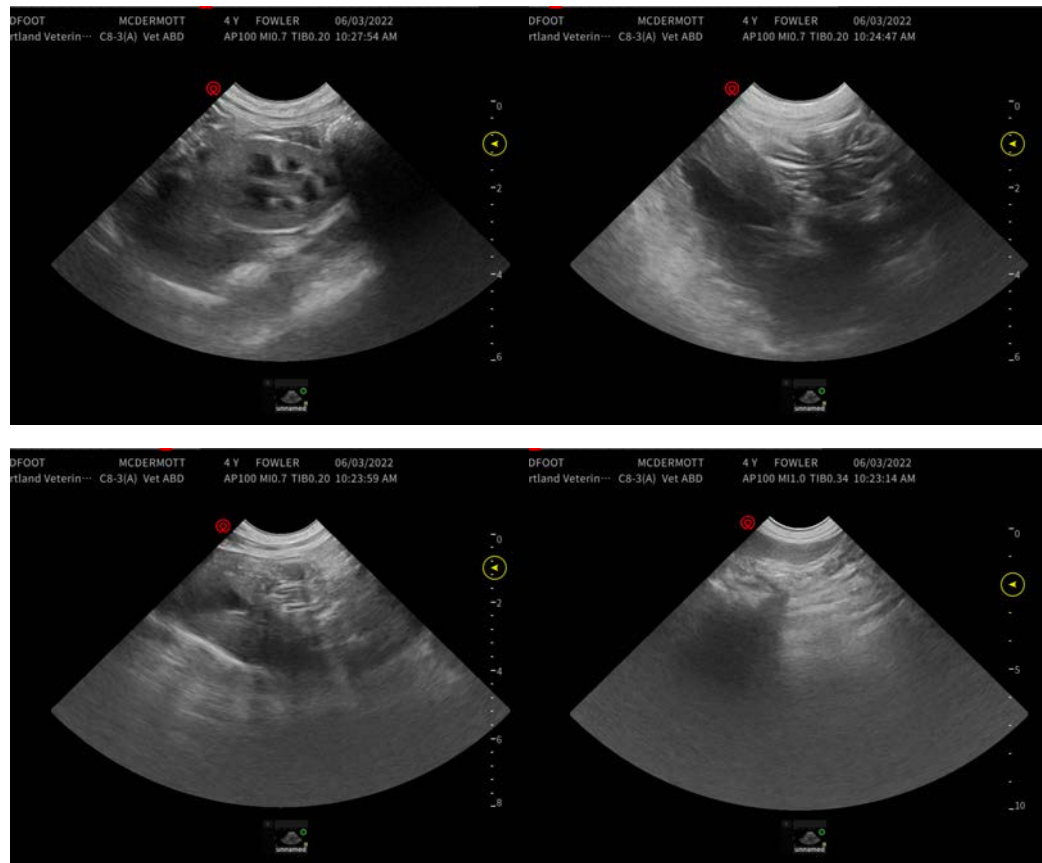
Dr. Karen Fowler

HOSPITAL NAME

Portland Veterinary Wellness Center

REFERRING VET

Dr. Karen Fowler



INVOICE

38379

DATE

6/3/22



PATIENT

Padfoot McDermott

SPECIES

Feline

BREED

DSH

SEX

Spayed Female

AGE

4 Years

WEIGHT

9.5 Pounds

INTERPRETED BY

Eric Lindquist, DMV

DABVP, Cert. IVUSS

IMAGING PERFORMED BY

Dr. Karen Fowler

HOSPITAL NAME

Portland Veterinary
Wellness Center

REFERRING VET

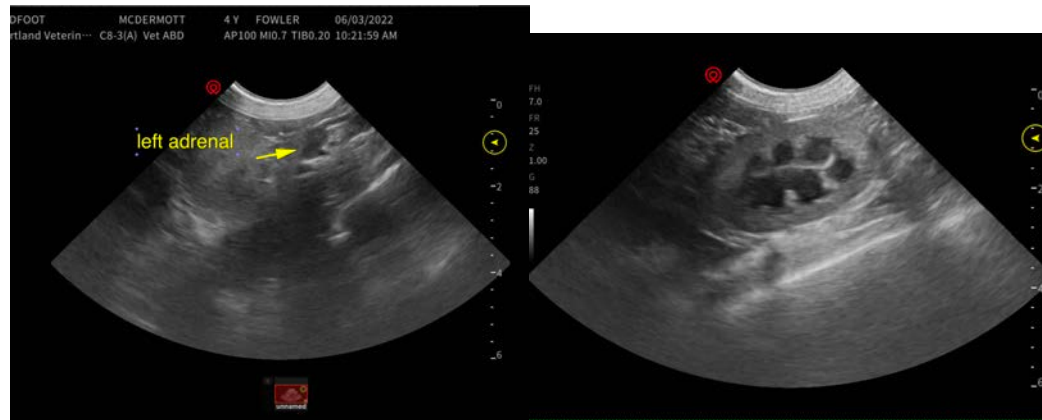
Dr. Karen Fowler

INVOICE

38379

DATE

6/3/22



The information and recommendations provided are based on the images presented by the referring veterinarian/sonographer. No evaluation can be communicated regarding pathology that was not visible in the image/video clips provided.

Thank you for this referral. If the clinical or image interpretation does not parallel your findings or if I can be of any further assistance please contact me.

Eric Lindquist, DMV, DABVP, Cert. IVUSS, CEO of SonoPath.com

info@SonoPath.com