

IMAGING PERFORMED BY

IntraPet.com



**SonoPath**

Clinical Sonography & Telecytology

EDUCATIONAL TELECONSULTATION SERVICES™

1-800-838-4268 info@sonopath.com SonoPath.com

**DATE**

6/3/22

**PATIENT**

Kaia Ballard

**SPECIES**

Canine

**BREED**

Labrador X

**SEX**

Spayed Female

**AGE**

10/30/08

**WEIGHT**

57 Pounds

**INTERPRETED BY**

Eric Lindquist, DMV  
DABVP, Cert. IVUSS

**IMAGING PERFORMED BY**

Stephanie Pearce  
RDCS, RVT

**HOSPITAL NAME**

Festival Vet Clinic

**REFERRING VET**

Dr. Ullman

**INVOICE**

38374

**PRESENTING CLINICAL SIGNS**

Moderate to severe dental calculus, Gingivitis, Generalized wearing. Around the rectal - irritated- Left anal gland empty, Right anal gland - mildly enlarged expressed normally, no masses appreciated in rectal  
Frank blood from rectal- looks a possible fissure on ventral part of tissue  
ears- wnl, h/l- bilateral increased Broncho vesicular sounds, s/c- wnl  
R/O pancreatitis , pancreatic cyst, pancreatic neoplasia. Due to proteinuria/high pressure will start benezpril

Current Medications: Benazapril 5mg 1 PO BID, Galliprant 60mg 1 PO QD.  
Lab Results: Increased BUN R/O prerenal ( dehydration vs GI bleeding) vs renal ( kidney, UTI) vs post.  
Increased ALT and ALKP ( R/O GI vs liver vs bone vs metabolic). Increased Amylase and lipase R/O  
pancreatic inflammation, CPLi snap test- positive R/O pancreatitis , pancreatic cyst, pancreatic neoplasia  
Date of Previous IntraPet Ultrasound: No previous.  
Sedation: Not required to complete full diagnostic ultrasound.  
Stat Report: Declined.

**ULTRASONOGRAPHIC EXAMINATION OF THE ABDOMEN**

**Urinary System**

The **urinary bladder**, trigone, and pelvic urethra presented normal thicknesses and normal tone. The ureters were not visible which is normal. No uroliths or sediment were visualized and anechoic urine was present. No evidence of inflammatory or neoplastic changes were noted. Ureteral papillae were normal. The pelvic urethra was imaged 3.0 cm beyond the cystourethral junction.

The **kidneys** revealed largely normal size and structure, corticomedullary definition and ratio (cortex 1/3 of medulla) were essentially maintained with some age-related loss of curvilinear patterns regarding the capsule and C/M junction. The cortices presented largely uniform texture with some increased echogenicity expected for his age patient. Medullary structure differed distinctly from that of the cortex. Pyelectasia noted in both kidneys. Right pyelectasia measured 1.67 cm x 0.40 cm. The right kidney measured 7.03 cm. Left pyelectasia measured 1.72 cm x 0.37 cm. The left kidney measured 7.27 cm.

**Adrenal Glands**

Both **adrenal glands** were visualized and recognized as having largely normal shape, size, position and acceptable echogenicity for this age group and breed. Some heterogeneity was noted within the adrenal parenchyma without concerning capsular distortion. These changes are likely age related but should be monitored by sonogram should the patient be suspected of having adrenal disease. The right adrenal gland measured 2.38 cm x 0.66 cm at the caudal pole and 0.80 cm at the cranial pole. The left adrenal gland was slightly enlarged, measuring 2.45 cm x 0.87 cm at the caudal pole and 0.86 cm at the cranial pole.

**Spleen**

The **spleen** was largely smooth with subtle heterogeneous parenchymal changes while maintaining normal echogenic relationship to the liver and kidney. These changes are consistent with normal age-related alteration. The capsule was smooth without noticeable impingement from within the spleen or from pathology in the adjacent abdomen. The splenic vasculature demonstrated normal volume without signs of congestion or significant contraction. No evidence of active acute or chronic inflammatory, neoplastic, or infarctual changes were noted.

**Liver**

The **liver** images from right and left intercostal as well as subcostal views revealed subjectively normal liver size, contour, and structure. Some age-related parenchymal remodeling was noted but likely not clinically significant at this time. Slight hyperechoic 1.4 cm nodule noted. Vascular and biliary tracts were of normal volume and no evidence of congestion was noted. The gallbladder presented some dependent debris with

essentially normal contour. The cystic and common bile ducts were normal. No overt evidence of active inflammatory, infiltrative or regenerative pathology was noted but should be paired with current or past LE elevations regarding any clinical significance to this presentation. The hepatic lymph nodes were unremarkable.

### ***Gastrointestinal***

Examination of the **gastrointestinal tract** revealed a stomach and intestine free of stasis, of normal wall thickness, acceptable curvilinear mural detail, and peristaltic activity. Small and large intestine demonstrated normal luminal chyme and stool consistency respectively. No obstructive or overt infiltrative disease was noted. No associated abnormal lymphatic activity was noted.

### ***Pancreas***

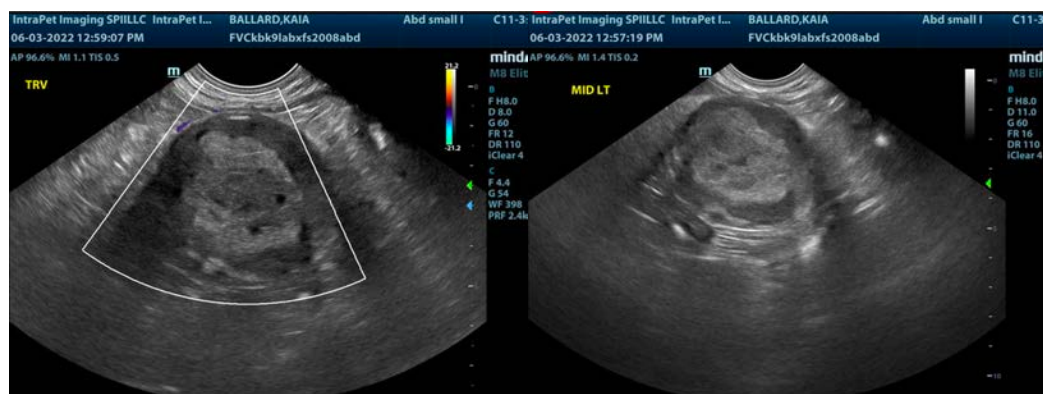A non-vascular 5.8 cm x 4.6 cm hypoechoic, marginated, mildly inflamed mass was noted in the left **pancreatic limb**. This is likely non-neoplastic necrosis or abscessation. Appears resectable. Heterogeneous, coarse architecture noted throughout the right and left pancreatic limbs, consistent with chronic active pancreatitis.

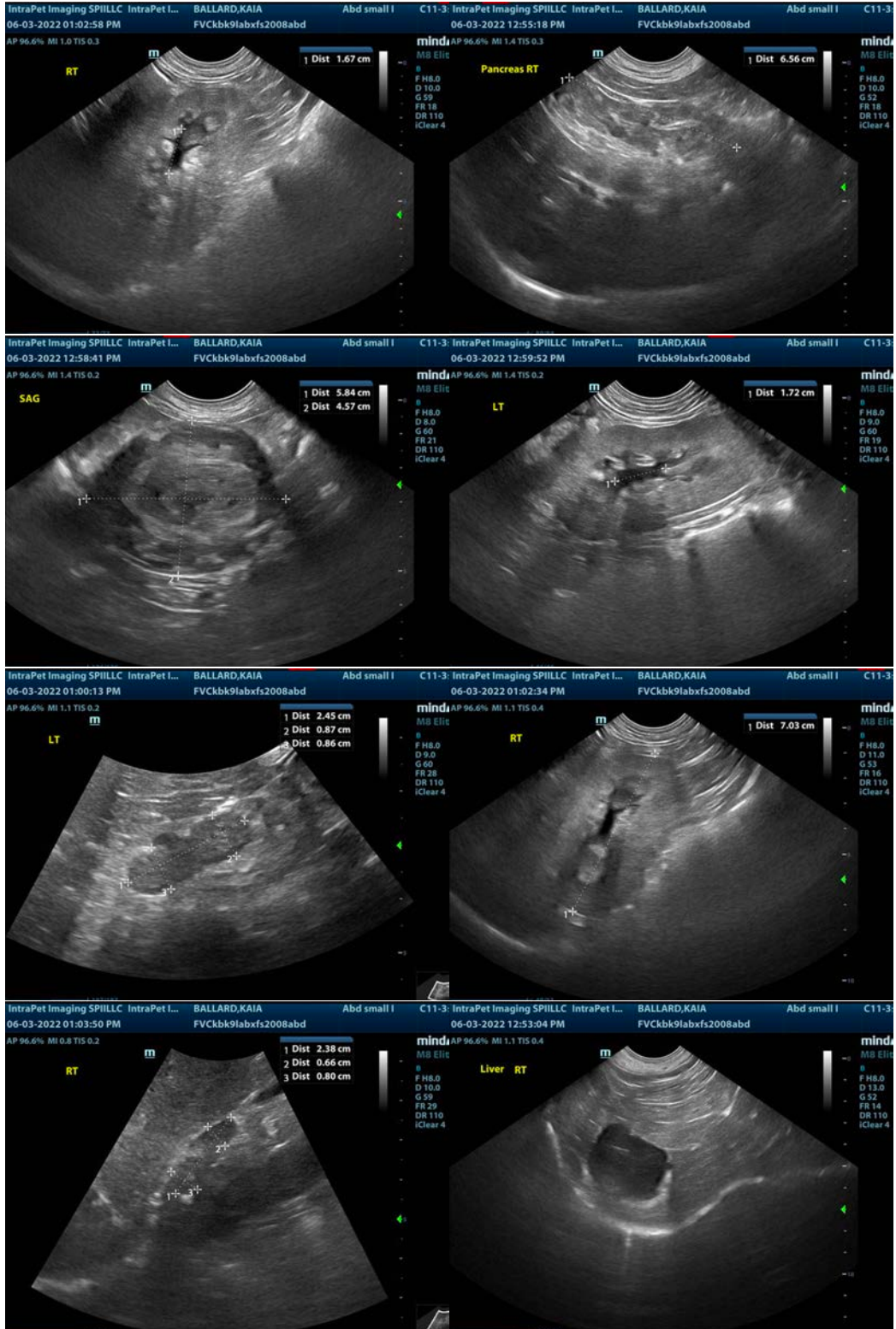
## **ULTRASONOGRAPHIC FINDINGS**

- Chronic active pancreatitis pattern with abscess or necrosis in the left pancreatic limb or omental origin
- Mild to moderate chronic degenerative renal changes with pyelectasia
- Benign appearing liver nodule

## **INTERPRETATION OF THE FINDINGS & FURTHER RECOMMENDATIONS**

Assessment for UTI indicated. 3-view chest radiographs and surgical exploratory with mass/necrosis/abscess removal from the left pancreatic limb. Biopsies of the general pancreas warranted for long-term management. Suspect chronic active lymphoplasmacytic pancreatitis, given the presentation.





**The information and recommendations provided are based on the images presented by the referring veterinarian/sonographer. No evaluation can be communicated regarding pathology that was not visible in the image/video clips provided.**

Thank you for this referral. If the clinical or image interpretation does not parallel your findings or if I can be of any further assistance please contact me.

**Eric Lindquist**, DMV, DABVP, Cert. IVUSS, CEO of SonoPath.com  
[info@SonoPath.com](mailto:info@SonoPath.com)