


PATIENT PRESENTING CLINICAL SIGNS

TITO GARVEN

 History: grade 4 heart murmur noted on clinical examination - left side pan systolic
 Chem/CBC WNL

SPECIES ULTRASONOGRAPHIC EXAMINATION OF THE HEART

Canine

The heart subjectively revealed normal volumes and contractility. The septal free wall thicknesses were normal. Some turbulence was noted at the left ventricular outflow tract; however, the source of the murmur is unclear. Further imaging is necessary, yet no specific therapy is recommended at this time.

BREED

American Bully

SEX

Male

AGE

6 months

WEIGHT

15 lbs

INTERPRETED BY

 Eric Lindquist, DMV
 DABVP, Cert. IVUSS

CANINE CARDIAC PARAMETERS	MR VMAX (m/s)	TR VMAX (m/s)	LA/AO (Boon method)	LA/AO (Heart Base;)	FS (%)	EF (%)	EPSS (cm)
NORMAL PARAMETER	4.5-5.5	<2.7	1.3	<1.6	28-40	40-100	<0.6
PATIENT			NM	1.4	45		0.1
CANINE CARDIAC PARAMETERS	HR (BPM)	AV VMAX (m/s)	PV MAX (m/s)	BODY WEIGHT	LA 2D short axis Base view (cm)	LVIDd Avg; 2D and m- mode short axis (cm)	LVIDs Avg; 2D and m-mode short axis (cm)
NORMAL PARAMETER	50-100	0.7-1.7	0.7-1.6	BELOW	BELOW	BELOW	BELOW
PATIENT				15 lbs		2.7	

IMAGING PERFORMED BY

Dr. Eamon

ULTRASONOGRAPHIC FINDINGS

Normal cardiac volume and global structure.

HOSPITAL NAME

 Advanced Veterinary
 Imaging

INTERPRETATION OF THE FINDINGS & FURTHER RECOMMENDATIONS

The cause of the murmur is unclear. Further imaging is necessary. No specific treatment is recommended.

REFERRING VET

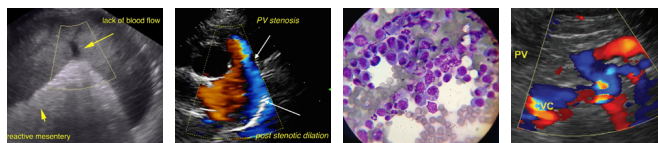
Dr. Eamon

INVOICE

45042

DATE

6/29/23



PATIENT

Tito Garven

SPECIES

Canine

BREED

American Bully

SEX

Male

AGE

6 months

WEIGHT

15 lbs

INTERPRETED BY

Eric Lindquist, DMV
DABVP, Cert. IVUSS

**IMAGING
PERFORMED BY**

Dr. Eamon

HOSPITAL NAME

Advanced Veterinary
Imaging

REFERRING VET

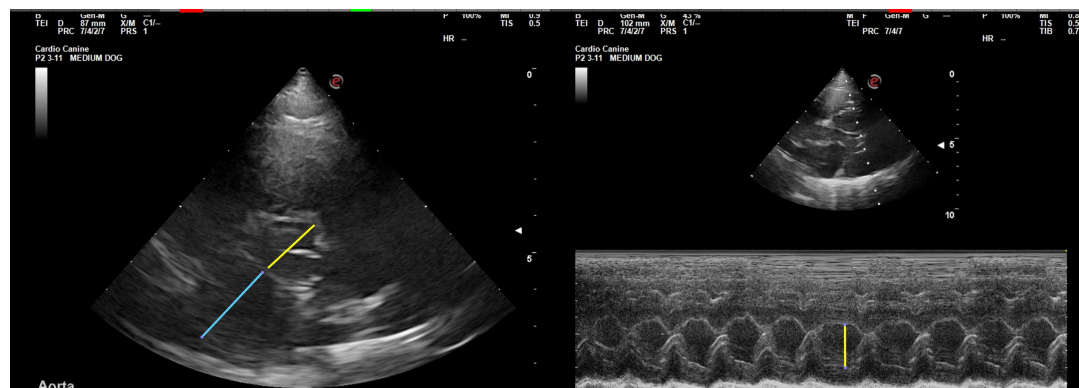
Dr. Eamon

INVOICE

45042

DATE

6/29/23



The information and recommendations provided are based on the images presented by the referring veterinarian/sonographer. No evaluation can be communicated regarding pathology that was not visible in the image/video clips provided.

Thank you for this referral. If the clinical or image interpretation does not parallel your findings or if I can be of any further assistance please contact me.

Eric Lindquist, DMV, DABVP, Cert. IVUSS, CEO of SonoPath.com
info@SonoPath.com