



PATIENT PRESENTING CLINICAL SIGNS

Ruger Wendt History: Previous echo evaluated by EH in April 2023

SPECIES ULTRASONOGRAPHIC EXAMINATION OF THE HEART

Feline

The echocardiogram in this patient presented minor left ventricular hypertrophy with mild myocardial remodeling. The contractility and internal volumes appeared normal. No pericardial or pleural effusion was noted.

BREED

Domestic Shorthair

SEX

Neutered male

AGE

4 years

WEIGHT

12 lbs

INTERPRETED BY

Eric Lindquist, DMV
DABVP, Cert. IVUS

IMAGING PERFORMED BY

Jill Rumachik

HOSPITAL NAME

Clarity Imaging LLC

REFERRING VET

CC SHledon

INVOICE

45045

DATE

6/29/23

FELINE CARDIAC PARAMETERS	BODY WEIGHT (kg)	HR (BPM)	IVSd (cm)	LVIDd (cm)	LVWd (cm)	FS (%)	EF (%)
NORMAL PARAMETER	-----	150-240	0.3-0.6	1.0-2.1	0.25-0.6	35-67	80-100
PATIENT		NM		1.3		50	90
FELINE CARDIAC PARAMETERS	LA/AO (Boon)	LA/AO HEART BASE (Sisson)	LA 2D 4-chamber long axis AS to FW (Sisson) (cm)	LVOT VEL. (m/s)	RVOT VEL. (m/s)	IVRT (m/)	
NORMAL PARAMETER	<1.5	0.88-1.79	0.7-1.7	<1.6	<1.3	40-60	
PATIENT	1.1	1.3	1.2 max				NM
Adapted from June Boon, Veterinary Echocardiography, 1998 Sisson D et al. JVIM 1991; 5: 232, Jacobs et al. Am J Vet Res 1985; 46:1705							

ULTRASONOGRAPHIC FINDINGS

Minor left ventricular hypertrophy and mild myocardial remodeling.

INTERPRETATION OF THE FINDINGS & FURTHER RECOMMENDATIONS

No therapy is recommended at this time. Recheck echocardiogram in 6-12 months or earlier if murmur grade increases. Blood pressure measurements and thyroid levels should be monitored carefully.



PATIENT

Ruger Wendt

SPECIES

Feline

BREED

Domestic Shorthair

SEX

Neutered male

AGE

4 years

WEIGHT

12 lbs

INTERPRETED BY

Eric Lindquist, DMV
DABVP, Cert. IVUS

IMAGING PERFORMED BY

Jill Rumachik

HOSPITAL NAME

Clarity Imaging LLC

REFERRING VET

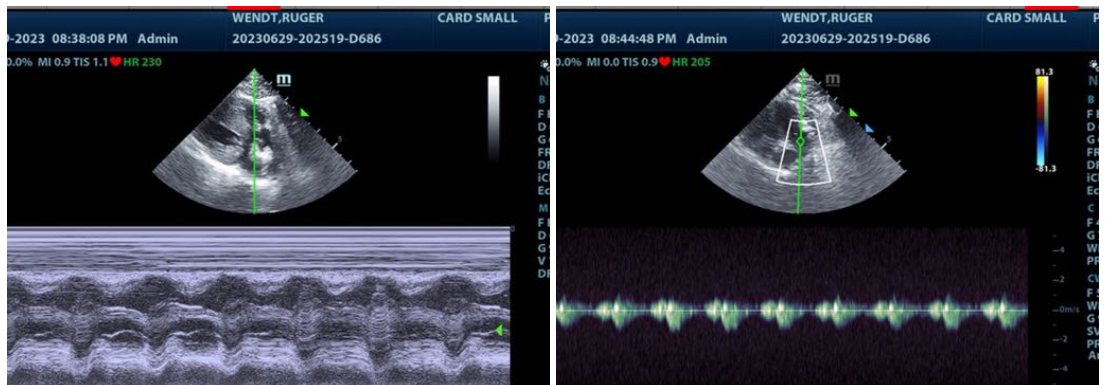
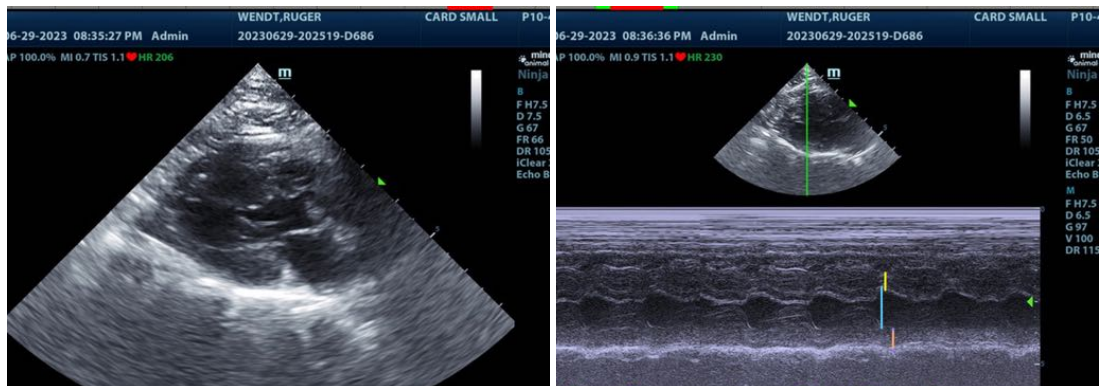
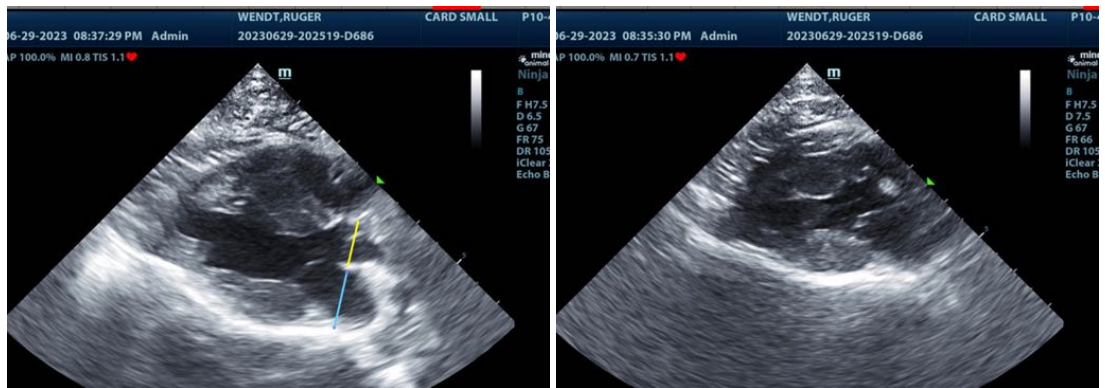
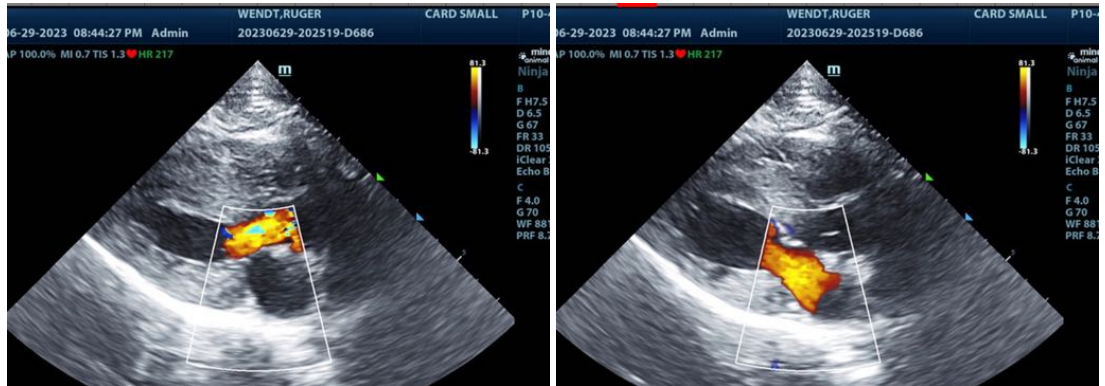
CC SHledon

INVOICE

45045

DATE

6/29/23





PATIENT

Ruger Wendt

The information and recommendations provided are based on the images presented by the referring veterinarian/sonographer. No evaluation can be communicated regarding pathology that was not visible in the image/video clips provided.

SPECIES

Feline

Thank you for this referral. If the clinical or image interpretation does not parallel your findings or if I can be of any further assistance please contact me.

BREED

Domestic Shorthair

Eric Lindquist, DMV, DABVP, Cert. IVUSS, CEO of SonoPath.com
info@SonoPath.com

SEX

Neutered male

AGE

4 years

WEIGHT

12 lbs

INTERPRETED BY

Eric Lindquist, DMV
DABVP, Cert. IVUSS

**IMAGING
PERFORMED BY**

Jill Rumachik

HOSPITAL NAME

Clarity Imaging LLC

REFERRING VET

CC SHledon

INVOICE

45045

DATE

6/29/23