

**PATIENT**

Optimus Prime Heath

**SPECIES**

Feline

**BREED**

DLH

**SEX**

Neutered Male

**AGE**

3 Years

**WEIGHT**

11 Pounds

**INTERPRETED BY**

Eric Lindquist, DMV,  
DABVP, Cert. IVUSS

**HOSPITAL NAME**

VCS Westmoreland AH

**REFERRING VET**

Dr. Baxter

**INVOICE NUMBER**

23119

**DATE**

6/29/23

**PRESENTING CLINICAL SIGNS**

History: -o will be moving/flying with pet on 6/30/23 -seen 4/6/23 for normal WHC no concern for lump at that time -seen 6/23/23 for lump noticed on R side abd, no other concerns, pet acting normal -on PE: mass felt in cranial abd, suspect nodular spleen -R/O splenic neoplasia, abscess, foreign body, other...

Abnormal PE/Chem/CBC/UA Results: ABNORMAL Laboratory Findings most recent labs emailed Current Medications gabapentin, will be sedated with something Radiographic Findings no rads to send

**ULTRASONOGRAPHIC EXAMINATION OF THE ABDOMEN**

**Urinary System**

The **urinary bladder**, trigone, and pelvic urethra presented normal thicknesses and normal tone. The ureters were not visible which is normal. No uroliths or sediment were visualized and anechoic urine was present. No evidence of inflammatory or neoplastic changes were noted. Ureteral papillae were normal.

The **kidneys** revealed normal size and structure, corticomedullary definition and ratio for this age. The cortices presented largely uniform texture with normal echogenic relationship to liver and spleen. Medullary structure differed distinctly from the cortex and no evidence of pelvic dilation was present. The capsules were acceptably uniform without significant irregularities. The right kidney measured 4.45 cm. The left kidney measured 3.95 cm.

**Adrenal Glands**

Both **adrenal glands** were visualized and recognized as having normal shape, size, position and echogenicity for this breed. The phrenic vasculature, glandular echogenicity and detail were unremarkable. Capsule, cortex, and medullary definition were normal for this age patient. The left adrenal gland measured 0.49 cm. The right adrenal gland measured 0.42 cm.

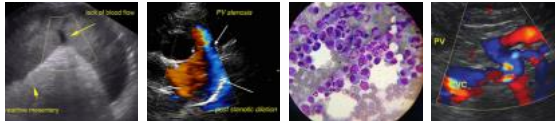
**Spleen**

The **spleen** presented a smooth homogeneous parenchyma hyperechoic to liver and renal cortical parenchyma. The capsule was smooth without noticeable expansion or deviation from within the spleen or adjacent pathology. The splenic vasculature demonstrated normal volume without signs of congestion or thrombosis. No sonographic evidence of acute or chronic inflammatory, neoplastic, or infarctual changes were noted. The spleen measured 0.92 cm.

**Liver**

The **liver** images submitted revealed subjectively normal liver size, contour, and structure. Parenchymal echogenicity was naturally coarse and hypoechoic to the spleen. Vascular and biliary tracts were of normal volume with no evidence of congestion. The gallbladder presented acceptably thin walls with primarily anechoic content. The cystic and common bile ducts were normal. No pathological hepatic lymphadenopathy was evident. No overt structural evidence of inflammatory, infiltrative or regenerative pathology was evident.

**Gastrointestinal**



**PATIENT** The **stomach** was filled with progressively shadowing material. If any vommiting or anorexia is an issue, then im concerned for foreign matter or very dense hair ball. Serpentine pattern to the small intestine was noted in this patient. I cannot rule out a linked linear foreign body to the gastric material.

Optimus Prime Heath

**SPECIES** **Pancreas**  
The base and limbs of the **pancreas** were observed to be largely isoechoic to surrounding omental fat. Pancreatic duct and capsular contour were acceptably normal and parenchyma respected normal curvilinear patterns. No overt evidence of active inflammatory or neoplastic disease was noted.

Feline

**BREED** **ULTRASONOGRAPHIC FINDINGS**  
DLH  
• Shadowing gastric material

**SEX** **INTERPRETATION OF THE FINDINGS & FURTHER RECOMMENDATIONS**

Neutered Male Assuming the patient was NPO at the time of the sonogram, concern for fairly dense foreign body or very dense hair ball is possible. The material occupied the majority of the stomach, extending caudally and may be palpable in the cranial abdomen. I recommend exploratory surgery, assuming the patient was NPO at the time of the sonogram. GI biopsies are warranted to rule out underlying disease.

**AGE**  
3 Years

**WEIGHT**  
11 Pounds

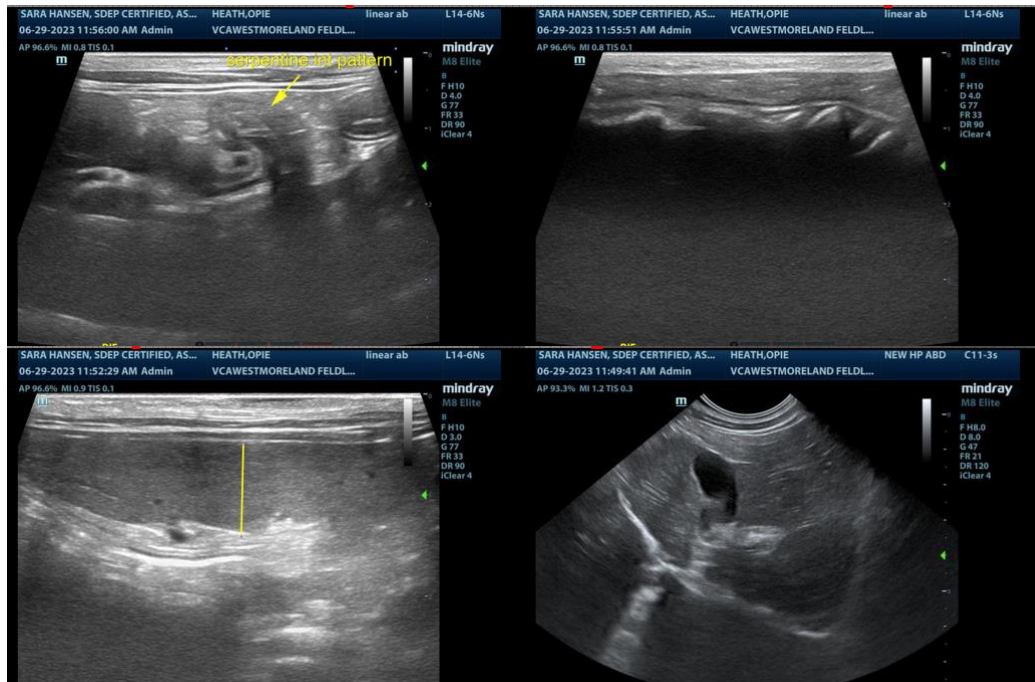
**INTERPRETED BY**  
Eric Lindquist, DMV,  
DABVP, Cert. IVUSS

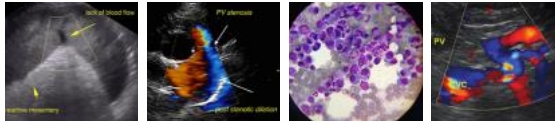
**HOSPITAL NAME**  
VCS Westmoreland AH

**REFERRING VET**  
Dr. Baxter

**INVOICE NUMBER**  
23119

**DATE**  
6/29/23





**PATIENT**

Optimus Prime Heath

**SPECIES**

Feline

**BREED**

DLH

**SEX**

Neutered Male

**AGE**

3 Years

**WEIGHT**

11 Pounds

**INTERPRETED BY**

Eric Lindquist, DMV,  
DABVP, Cert. IVUSS

**HOSPITAL NAME**

VCS Westmoreland AH

**REFERRING VET**

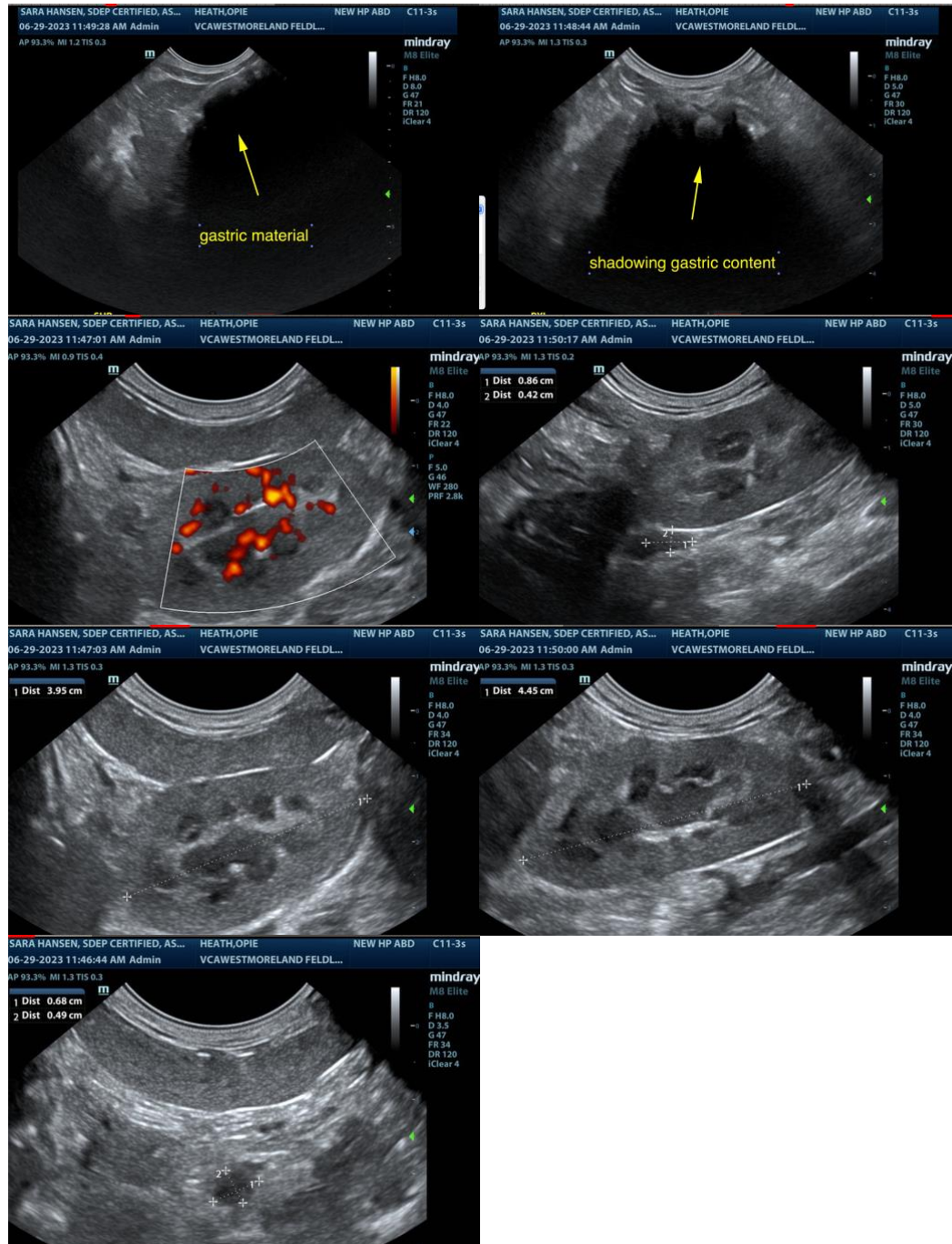
Dr. Baxter

**INVOICE NUMBER**

23119

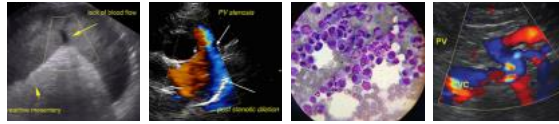
**DATE**

6/29/23



**The information and recommendations provided are based on the images presented by the referring veterinarian. No evaluation can be communicated regarding pathology that was not visible in the image/video clips provided.**

Thank you for this referral. If the clinical or image interpretation does not parallel your findings or if I can be of any further assistance please contact me.



**PATIENT**

Optimus Prime Heath **Eric Lindquist, DMV, DABVP, Cert. IVUSS, CEO of SonoPath.com**  
info@SonoPath.com

**SPECIES**

Feline

**BREED**

DLH

**SEX**

Neutered Male

**AGE**

3 Years

**WEIGHT**

11 Pounds

**INTERPRETED BY**

Eric Lindquist, DMV,  
DABVP, Cert. IVUSS

**HOSPITAL NAME**

VCS Westmoreland AH

**REFERRING VET**

Dr. Baxter

**INVOICE NUMBER**

23119

**DATE**

6/29/23