


PATIENT PRESENTING CLINICAL SIGNS

Nala Butler

 History: grade 3 left hand side pansystolic murmur noted on routine clinical examination. Hoping to breed from this dog.
 CBC/Chem WNL

SPECIES ULTRASONOGRAPHIC EXAMINATION OF THE HEART

Canine

An occasional arrhythmia was noted in this patient. The cardiac presentation revealed fairly normal volumes and contractility. There was no pericardial or pleural effusion noted.

BREED

American Bulldog

SEX

Female

AGE

6 months

WEIGHT

15 kg

INTERPRETED BY

 Eric Lindquist, DMV
 DABVP, Cert. IVUSS

CANINE CARDIAC PARAMETERS	MR VMAX (m/s)	TR VMAX (m/s)	LA/AO (Boon method)	LA/AO (Heart Base;)	FS (%)	EF (%)	EPSS (cm)
NORMAL PARAMETER	4.5-5.5	<2.7	1.3	<1.6	28-40	40-100	<0.6
PATIENT			1.1	1.4	45		0.1
CANINE CARDIAC PARAMETERS	HR (BPM)	AV VMAX (m/s)	PV MAX (m/s)	BODY WEIGHT (kg)	LA 2D short axis Base view (cm)	LVIDd Avg; 2D and m- mode short axis (cm)	LVIDs Avg; 2D and m- mode short axis (cm)
NORMAL PARAMETER	50-100	0.7-1.7	0.7-1.6	BELOW	BELOW	BELOW	BELOW
PATIENT				15 kg		3.7	

IMAGING PERFORMED BY

Dr. Eamon

ULTRASONOGRAPHIC FINDINGS

Unremarkable heart.

HOSPITAL NAME

 Advanced Veterinary
 Imaging

REFERRING VET

Dr. Eamon

INTERPRETATION OF THE FINDINGS & FURTHER RECOMMENDATIONS

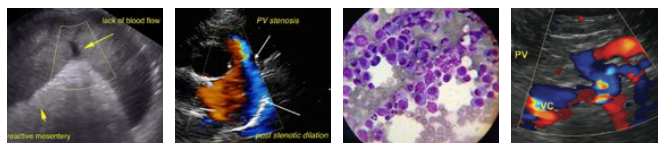
However, the cause of the murmur is unclear. Given the age and breed I do not recommend breeding this patient until further images are obtained as the grade III murmur would suggest a congenital lesion that needs further definition, yet no treatment or volume overload was noted at this time.

INVOICE

45043

DATE

6/29/23



PATIENT

Nala Butler

SPECIES

Canine

BREED

American Bulldog

SEX

Female

AGE

6 months

WEIGHT

15 kg

INTERPRETED BY

Eric Lindquist, DMV
DABVP, Cert. IVUSS

IMAGING PERFORMED BY

Dr. Eamon

HOSPITAL NAME

Advanced Veterinary
Imaging

REFERRING VET

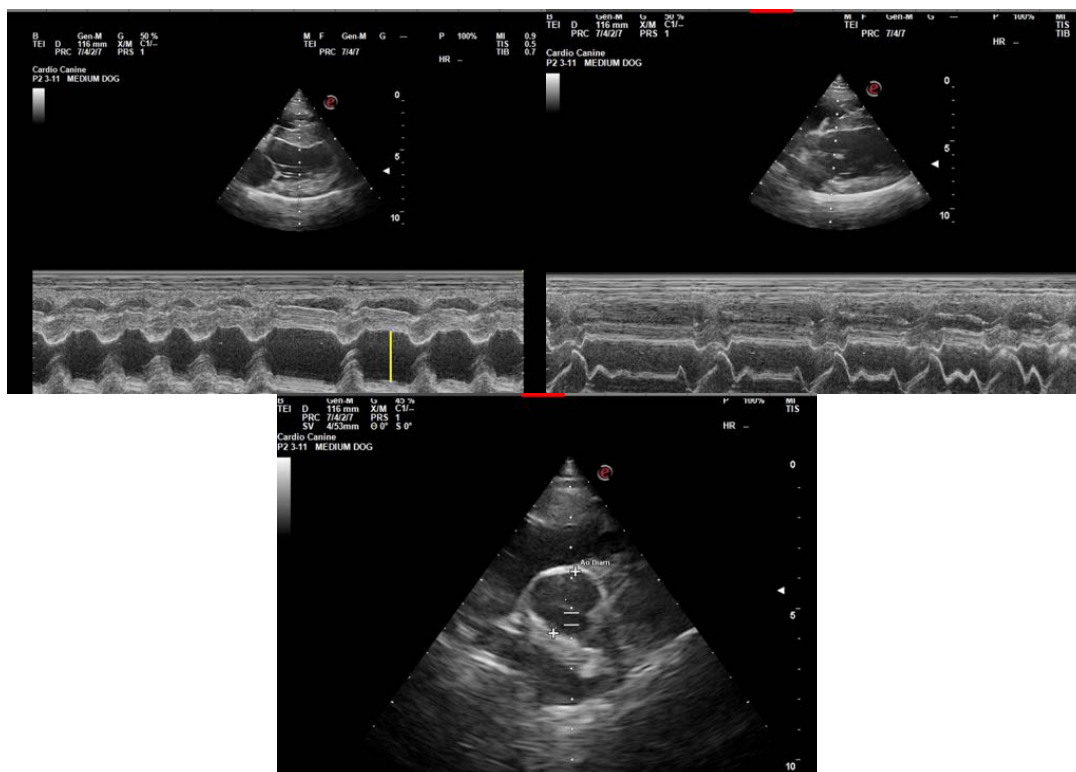
Dr. Eamon

INVOICE

45043

DATE

6/29/23



The information and recommendations provided are based on the images presented by the referring veterinarian/sonographer. No evaluation can be communicated regarding pathology that was not visible in the image/video clips provided.

Thank you for this referral. If the clinical or image interpretation does not parallel your findings or if I can be of any further assistance please contact me.

Eric Lindquist, DMV, DABVP, Cert. IVUSS, CEO of SonoPath.com
info@SonoPath.com