

**DATE PRESENTING CLINICAL SIGNS**

6/29/23

History: Patient presented for brown urine. Regenerative anemia and bilirubinemia were noted on bloodwork. Pt was started on Doxycycline and urine has since improved in color. Pt is energetic and acting normally, eating normally.

PATIENT

Max Meyer

Current Medications: Fluids, Prednisone, Doxycycline.

Lab Results: See attached.

SPECIES

Date of Previous IntraPet Ultrasound: No previous.

Sedation: Patient sedated with Torbugesic.

Canine

Stat Report: Requested by DVM.

BREED

Imaging Performed By: Andi Parkinson, RDMS.

Mixed Breed

ULTRASONOGRAPHIC EXAMINATION OF THE ABDOMEN**SEX****Urinary System**

Neutered Male

The **urinary bladder**, trigone, and pelvic urethra presented normal thicknesses and normal tone. The ureters were not visible which is normal. No uroliths or sediment were visualized and anechoic urine was present. No evidence of inflammatory or neoplastic changes were noted. Ureteral papillae were normal.

AGE

5/24/13

The **kidneys** revealed largely normal size and structure, corticomedullary definition and ratio (cortex 1/3 of medulla) were essentially maintained with some mild age-related loss of curvilinear patterns regarding the capsule and C/M junction. The cortices presented largely uniform texture with some increased echogenicity expected for his age patient. Medullary structure differed distinctly from that of the cortex and no evidence of pelvic dilation was present. The left kidney measured 6.58 cm. The right kidney measured 6.13 cm.

WEIGHT

61.5 Pounds

Adrenal Glands**INTERPRETED BY**

Both **adrenal glands** were visualized and recognized as having normal shape, size, position and echogenicity for this breed. The phrenic vasculature, glandular echogenicity and detail were unremarkable. Capsule, cortex, and medullary definition were normal for this age patient. The right adrenal gland measured 2.44 cm x 0.7 cm at the cranial pole and 0.79 cm at the caudal pole. The left adrenal gland measured 0.63 cm.

Eric Lindquist, DMV
DABVP, Cert. IVUSS**HOSPITAL NAME**

Bayside AMC

Spleen

The **spleen** revealed a moderately complex cystic and parenchymal mass, measuring approximately 10 cm. No abdominal rupture was noted. No overt organ metastasis was present.

REFERRING VET

Dr. Sims

Liver

The **liver** images submitted revealed subjectively normal liver size, contour, and structure. Parenchymal echogenicity was naturally coarse and hypoechoic to the spleen. Vascular and biliary tracts were of normal volume with no evidence of congestion. The gallbladder presented acceptably thin walls with primarily anechoic content. The cystic and common bile ducts were normal. No pathological hepatic lymphadenopathy was evident. No overt structural evidence of inflammatory, infiltrative or regenerative pathology was evident.

INVOICE

23132

Gastrointestinal

Examination of the **gastrointestinal tract** revealed a stomach and intestine free of stasis, of normal wall thickness, acceptable curvilinear mural detail, and peristaltic activity. Small and large intestine demonstrated

normal luminal chyme and stool consistency respectively. No obstructive or overt infiltrative disease was noted. No associated abnormal lymphatic activity was noted.

Pancreas

The base and limbs of the **pancreas** were observed to be largely isoechoic to surrounding omental fat. Pancreatic duct and capsular contour were acceptably normal and parenchyma respected normal curvilinear patterns. No overt evidence of active inflammatory or neoplastic disease was noted.

Other

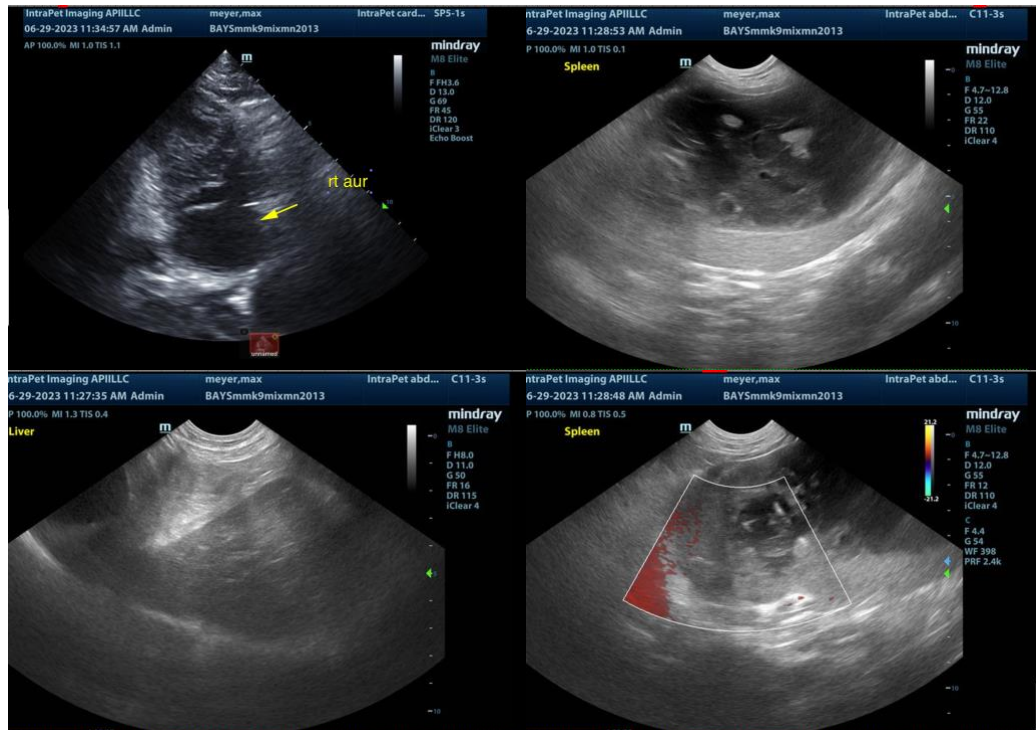
A rapid view of the **heart** revealed no evident pathology in the right auricle or pericardium. Normal contractility was noted.

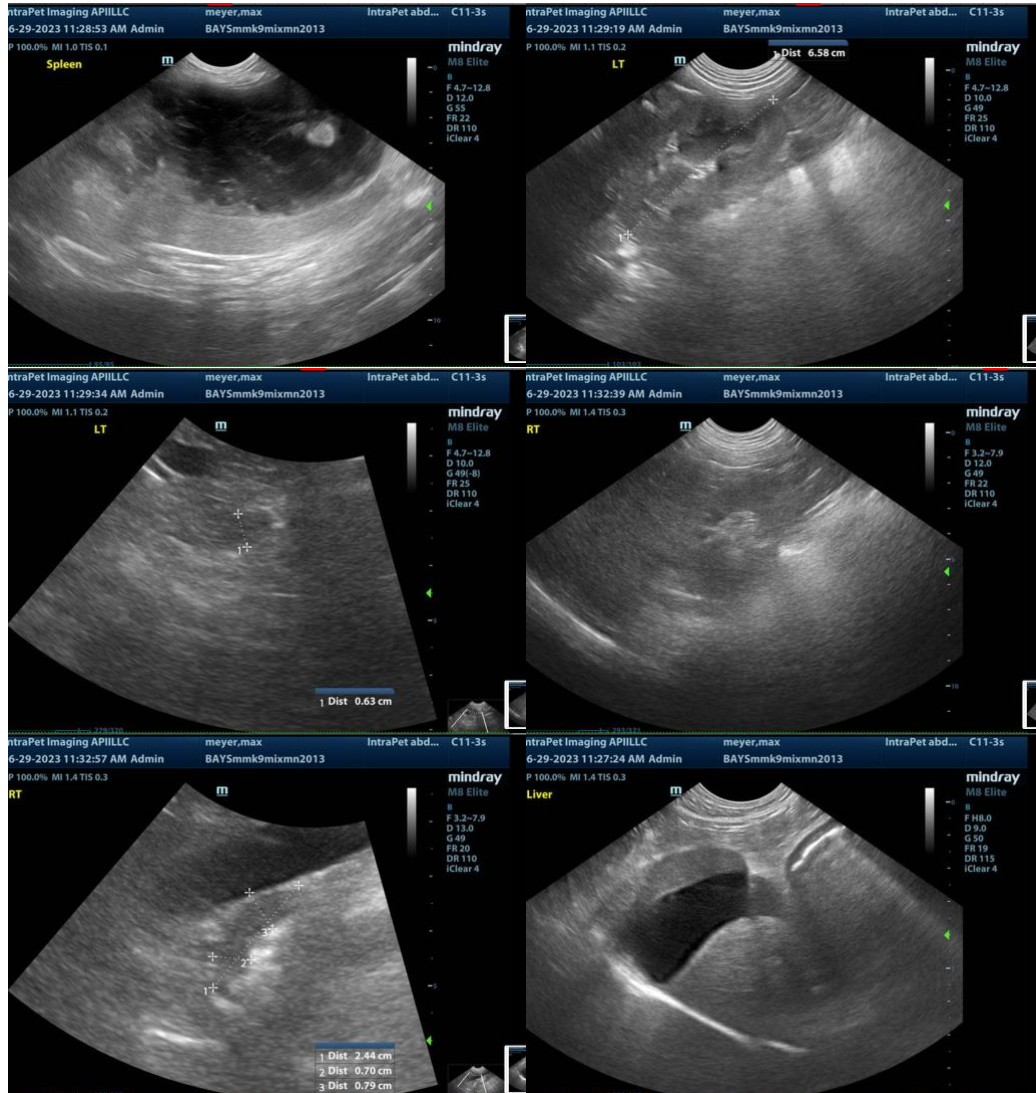
ULTRASONOGRAPHIC FINDINGS

- Splenic mass/hematoma- appears isolated with no obvious organ metastasis. This may be a pathologically benign change, however, is highly precarious.
- Age-related renal changes

INTERPRETATION OF THE FINDINGS & FURTHER RECOMMENDATIONS

Chest radiographs, followed by direct splenectomy, liver inspection and biopsy are indicated. I strongly encourage surgical intervention in this patient, as the histopathology may be benign. Hemangiosarcoma, of course, is a potential. Round cell neoplasia is unlikely. Hyperplasia with degenerative or traumatic based hematoma/clot is possible.





The information and recommendations provided are based on the images presented by the referring veterinarian. No evaluation can be communicated regarding pathology that was not visible in the image/video clips provided.

Thank you for this referral. If the clinical or image interpretation does not parallel your findings or if I can be of any further assistance please contact me.

Eric Lindquist, DMV, DABVP, Cert. IVUSS, CEO of SonoPath.com
 info@SonoPath.com