



**PATIENT PRESENTING CLINICAL SIGNS**

Madonna Wood

pDVM had px scheduled for a spay with me, but after reviewing the chart I noted that px has been examined multiple times for failure to grow/gain weight and her lab work had a mildly elevated ALP 282 (5-131). Performed pre and post prandial bile acids: Pre and post prandial bile acids Pre - 98.6 (H) Post - 23.5 Recommended postponing OVH for further w/u, r/o portosystemic shunt.

**SPECIES**

Canine

**ULTRASONOGRAPHIC EXAMINATION OF THE ABDOMEN**

**BREED**

Chihuahua

**Urinary System**

**SEX**

Female

The **urinary bladder**, trigone, and pelvic urethra presented normal thicknesses and normal tone. The ureters were not visible which is normal. No uroliths or sediment were visualized and anechoic urine was present. No evidence of inflammatory or neoplastic changes were noted. Ureteral papillae were normal.

**AGE**

10 Months

The **kidneys** revealed normal size and structure, corticomedullary definition and ratio for this age. The cortices presented largely uniform texture with normal echogenic relationship to liver and spleen. Medullary structure differed distinctly from the cortex and no evidence of pelvic dilation was present. The capsules were acceptably uniform without significant irregularities. The right kidney measured 3.0 cm. The left kidney measured 2.63 cm.

**WEIGHT**

1.8 kg

**Adrenal Glands**

**INTERPRETED BY**

Eric Lindquist, DMV

Both **adrenal glands** were visualized and recognized as having normal shape, size, position and echogenicity for this breed. The phrenic vasculature, glandular echogenicity and detail were unremarkable. Capsule, cortex, and medullary definition were normal for this age patient. The left adrenal gland measured 0.27 cm at the cranial pole and 0.25 cm at the caudal pole.

DABVP, Cert. IVUSS

**Spleen**

**IMAGING PERFORMED BY**

Loetitia Saint-Jacques, LVT

The **spleen** presented a smooth homogeneous parenchyma hyperechoic to liver and renal cortical parenchyma. The capsule was smooth without noticeable expansion or deviation from within the spleen or adjacent pathology. The splenic vasculature demonstrated normal volume without signs of congestion or thrombosis. No sonographic evidence of acute or chronic inflammatory, neoplastic, or infarctual changes were noted.

**HOSPITAL NAME**

Truckee Meadows VH

**Liver**

**REFERRING VET**

Dr. Rachel Kuester

The **liver** was slightly subnormal in size. Intrahepatic vascularity revealed normal volume. No evidence of intrahepatic shunting. However, at the level of the portal hilus, a dorsally directed vessel was present in the position of a spleno-azygos shunt as it bypassed the vena cava, measuring approximately 0.4 cm in maximum width. It appeared to traverse the aortic hiatus, creating a double aorta sign. The portal vein was subnormal in size at 0.30 cm. The vena cava measured 0.40 cm. Aorta measured 0.40 cm.

**INVOICE**

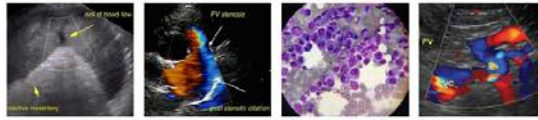
43629

**Gastrointestinal**

**DATE**

6/29/23

Examination of the **gastrointestinal tract** revealed a stomach and intestine free of stasis, of normal wall thickness, acceptable curvilinear mural detail, and peristaltic activity. Small and large intestine demonstrated normal luminal chyme and stool consistency respectively. No obstructive or overt infiltrative disease was noted. No associated abnormal lymphatic activity was noted.



**PATIENT** *Pancreas*

Madonna Wood

The base and limbs of the **pancreas** were observed to be largely isoechoic to surrounding omental fat. Pancreatic duct and capsular contour were acceptably normal and parenchyma respected normal curvilinear patterns. No overt evidence of active inflammatory or neoplastic disease was noted.

**SPECIES**

Canine

**ULTRASONOGRAPHIC FINDINGS**

**BREED**

Chihuahua

- Extrahepatic portosystemic shunt with normal vena cava to aortic ratio, subnormal portal vein to vena cava and subnormal portal vein to aortic ratio – consistent with spleno-azygos shunting with microhepatica.

**SEX**

Female

**INTERPRETATION OF THE FINDINGS & FURTHER RECOMMENDATIONS**

The position of the shunt would suggest azygos shunt, likely splenic vein origin/spleno-azygos shunting. CT with contrast indicated for confirmation as well as surgical consult.

**AGE**

10 Months

**Hepatic Support for Bile Acid Elevation +/- Hepatic Encephalopathy**

**WEIGHT**

1.8 kg

**Royal Canin Hepatic Support diet or Hills L/D, Metronidazole (7.5 mg/kg PO bid) over the next 14 days, Lactulose (Oral: 3.1-3.7 g/5 ml lactulose in a syrup base) long term to target 2-3 soft stools/day, with a high-quality protein supplement of minor amount of yogurt or cheddar cheese. Monitor bile acids, with attention paid to dropping albumin, BUN or cholesterol. SAME and nutraceuticals as needed. Ursodiol (10-15 mg/kg p.o. q24h) can be considered as hepatoprotectant and to enhance bile flow. Zinc serum level keep between 200–500 ug/dl. If deficient then Tx zinc acetate 1-3 mg/kg/day. Gastrointestinal protectants are recommended if the patient is anorexic.**

**INTERPRETED BY**

Eric Lindquist, DMV

DABVP, Cert. IVUSS

**IMAGING PERFORMED BY**

Loetitia Saint-Jacques, LVT

**HOSPITAL NAME**

Truckee Meadows VH

**REFERRING VET**

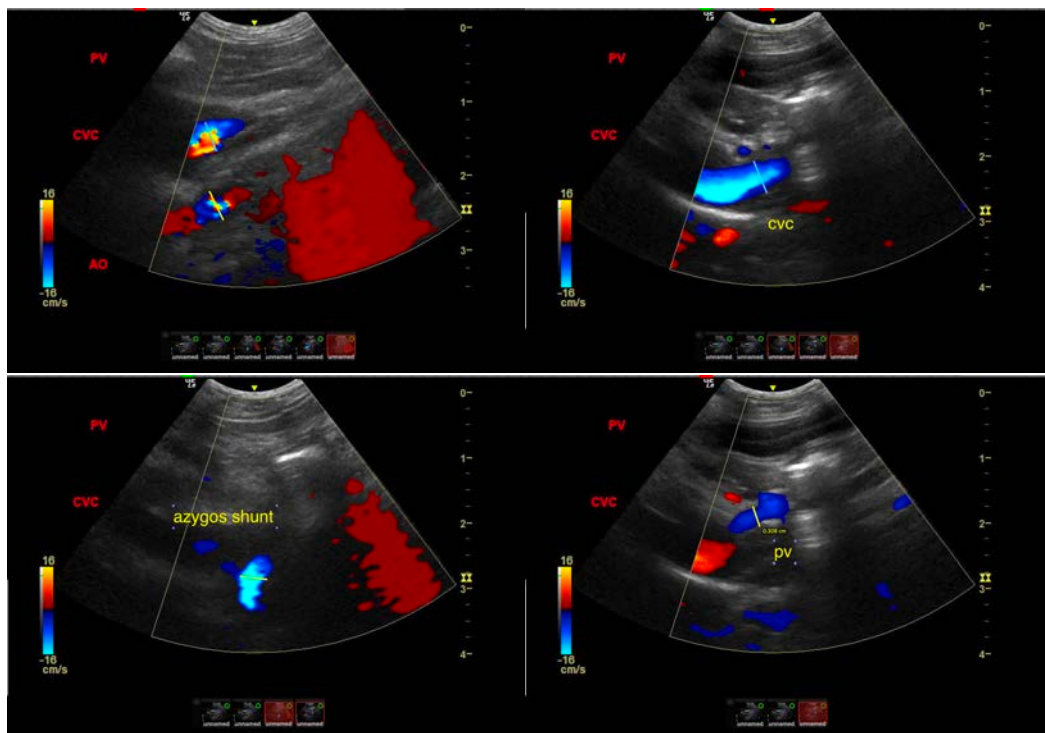
Dr. Rachel Kuester

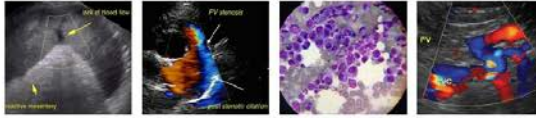
**INVOICE**

43629

**DATE**

6/29/23





**PATIENT**

Madonna Wood

**SPECIES**

Canine

**BREED**

Chihuahua

**SEX**

Female

**AGE**

10 Months

**WEIGHT**

1.8 kg

**INTERPRETED BY**

Eric Lindquist, DMV  
DABVP, Cert. IVUSS

**IMAGING PERFORMED BY**

Loetitia Saint-Jacques,  
LVT

**HOSPITAL NAME**

Truckee Meadows VH

**REFERRING VET**

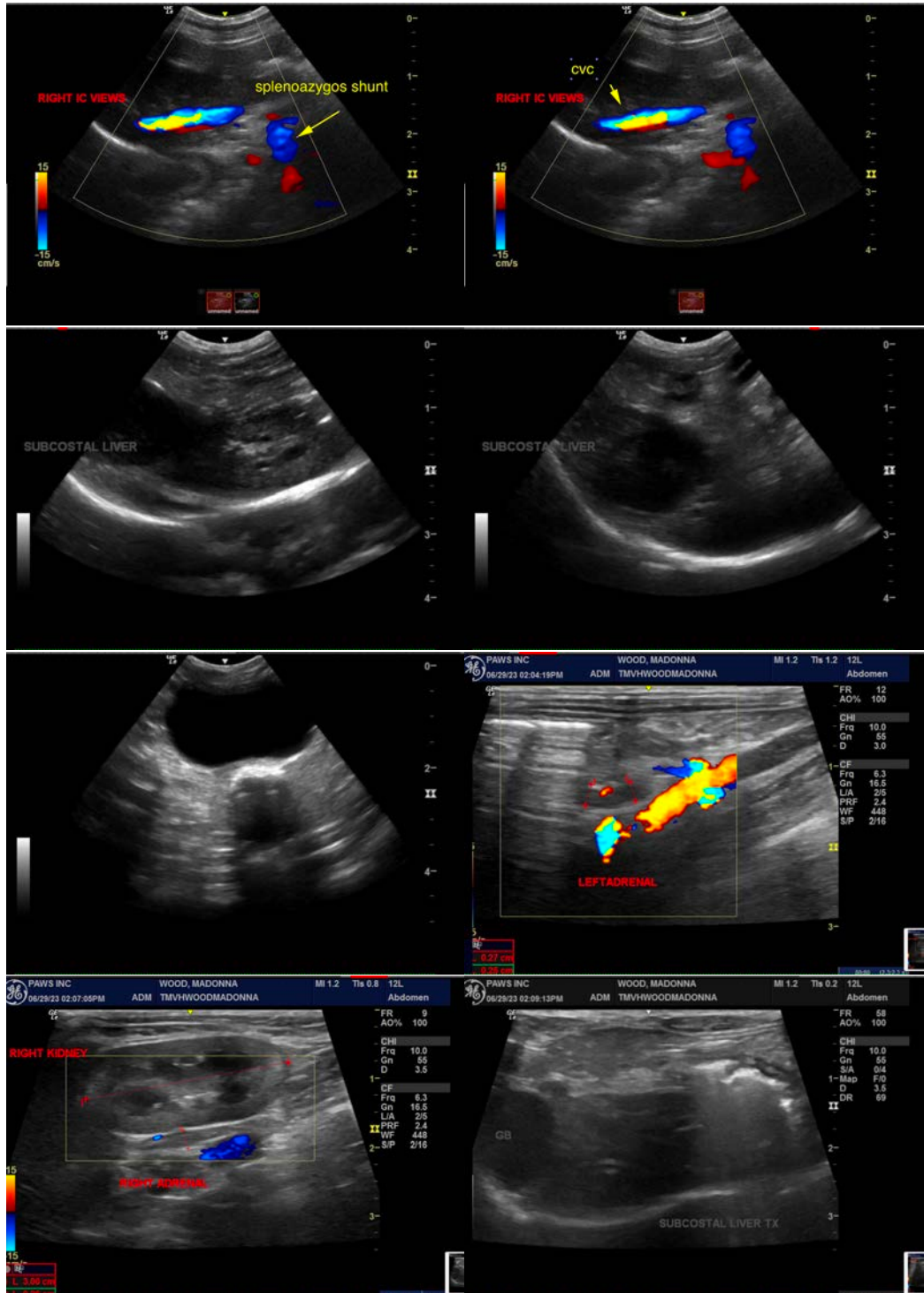
Dr. Rachel Kuester

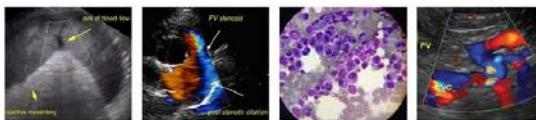
**INVOICE**

43629

**DATE**

6/29/23





**PATIENT**

Madonna Wood

**SPECIES**

Canine

**BREED**

Chihuahua

**SEX**

Female

**AGE**

10 Months

**WEIGHT**

1.8 kg

**INTERPRETED BY**

Eric Lindquist, DMV  
DABVP, Cert. IVUSS

**IMAGING PERFORMED BY**

Loetitia Saint-Jacques,  
LVT

**HOSPITAL NAME**

Truckee Meadows VH

**REFERRING VET**

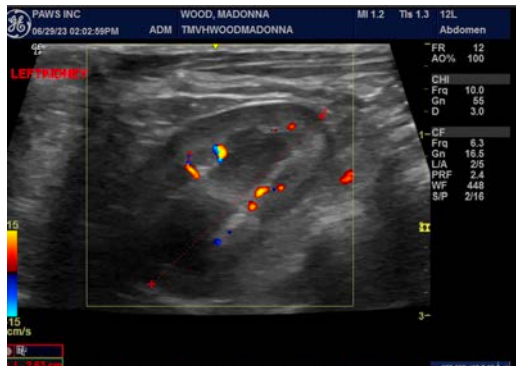Dr. Rachel Kuester

**INVOICE**

43629

**DATE**

6/29/23



The information and recommendations provided are based on the images presented by the referring veterinarian/sonographer. No evaluation can be communicated regarding pathology that was not visible in the image/video clips provided.

Thank you for this referral. If the clinical or image interpretation does not parallel your findings or if I can be of any further assistance please contact me.

Eric Lindquist, DMV, DABVP, Cert. IVUSS, CEO of SonoPath.com  
[info@SonoPath.com](mailto:info@SonoPath.com)