



PATIENT

Luciano Langley

SPECIES

Feline

BREED

Sphynx

SEX

Neutered Male

AGE

6 Years

WEIGHT

6 kg

INTERPRETED BY

Eric Lindquist, DMV

DABVP, Cert. IVUSS

IMAGING PERFORMED BY

Dr. Matthew Olcha

HOSPITAL NAME

East Meadow VC

REFERRING VET

Dr. Matthew Olcha

INVOICE

43490

DATE

6/28/23

PRESENTING CLINICAL SIGNS

Presented for acute onset of lethargy and anorexia. Vomited 2-3 times this am. No environmental changes, known exposures, etc. Pathologist review of CBC, UA, FIV/FeLV pending.

Abnormal PE/Chem/CBC/UA Results: Thrombocytopenia, suspect nRBCs, ALT 135

ULTRASONOGRAPHIC EXAMINATION OF THE ABDOMEN

Urinary System

The **urinary bladder**, trigone, and pelvic urethra presented normal thicknesses and normal tone. The ureters were not visible which is normal. No uroliths or sediment were visualized and anechoic urine was present. No evidence of inflammatory or neoplastic changes were noted. Ureteral papillae were normal.

The **kidneys** revealed largely normal size and structure, corticomedullary definition and ratio (cortex 1/3 of medulla) were essentially maintained with some age-related loss of curvilinear patterns regarding the capsule and C/M junction. The cortices presented largely uniform texture with some increased echogenicity expected for his age patient. Medullary structure differed distinctly from that of the cortex and no evidence of pelvic dilation was present. The left kidney measured 3.15 cm. The right kidney measured 4.04 cm.

Adrenal Glands

The regions of the **adrenal glands** were unremarkable.

Spleen

The **spleen** presented a smooth homogeneous parenchyma hyperechoic to liver and renal cortical parenchyma. The capsule was smooth without noticeable expansion or deviation from within the spleen or adjacent pathology. The splenic vasculature demonstrated normal volume without signs of congestion or thrombosis. No sonographic evidence of acute or chronic inflammatory, neoplastic, or infarctual changes were noted.

Liver

The **liver** images submitted revealed subjectively normal liver size, contour, and structure. Parenchymal echogenicity was naturally coarse and hypoechoic to the spleen. Vascular and biliary tracts were of normal volume with no evidence of congestion. The gallbladder presented acceptably thin walls with primarily anechoic content. The cystic and common bile ducts were normal. No pathological hepatic lymphadenopathy was evident. No overt structural evidence of inflammatory, infiltrative or regenerative pathology was evident.

Gastrointestinal

Examination of the **gastrointestinal tract** revealed a stomach and intestine free of stasis, of normal wall thickness, acceptable curvilinear mural detail, and peristaltic activity. Small and large intestine demonstrated normal luminal chyme and stool consistency respectively. No obstructive or overt infiltrative disease was noted. No associated abnormal lymphatic activity was noted.

Pancreas

The base and limbs of the **pancreas** were observed to be largely isoechoic to surrounding omental fat. Pancreatic duct and capsular contour were acceptably normal and parenchyma respected normal curvilinear patterns. No overt evidence of active inflammatory or neoplastic disease was noted.



PATIENT

Luciano Langley

SPECIES

Feline

BREED

Sphynx

SEX

Neutered Male

AGE

6 Years

WEIGHT

6 kg

INTERPRETED BY

Eric Lindquist, DMV
DABVP, Cert. IVUSS

IMAGING PERFORMED BY

Dr. Matthew Olcha

HOSPITAL NAME

East Meadow VC

REFERRING VET

Dr. Matthew Olcha

INVOICE

43490

DATE

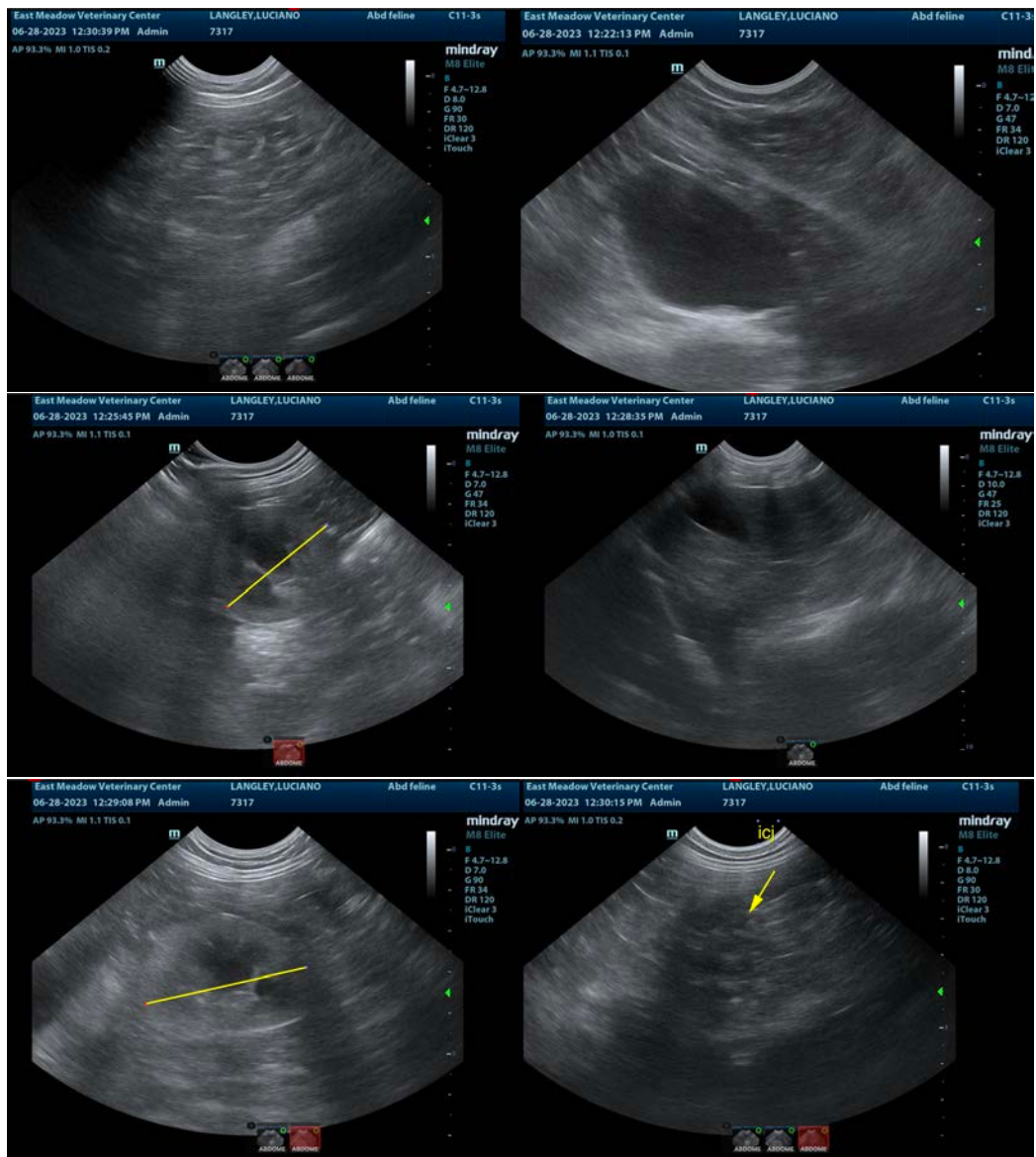
6/28/23

ULTRASONOGRAPHIC FINDINGS

- Structurally unremarkable abdomen

INTERPRETATION OF THE FINDINGS & FURTHER RECOMMENDATIONS

No evidence of visceral pathology. Supportive care should prove effective. CBC path review +/- bone marrow aspirate regarding the thrombocytopenia. Infectious agents should be considered.





PATIENT

Luciano Langley

SPECIES

Feline

BREED

Sphynx

SEX

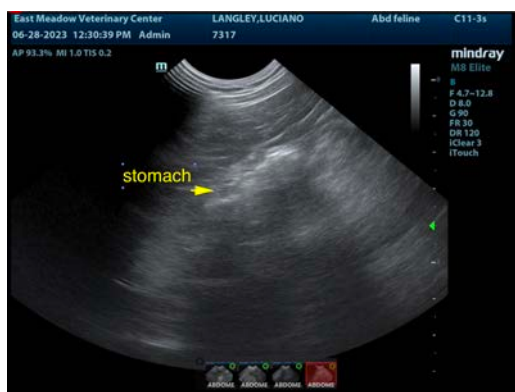Neutered Male

AGE

6 Years

WEIGHT

6 kg



The information and recommendations provided are based on the images presented by the referring veterinarian/sonographer. No evaluation can be communicated regarding pathology that was not visible in the image/video clips provided.

Thank you for this referral. If the clinical or image interpretation does not parallel your findings or if I can be of any further assistance please contact me.

Eric Lindquist, DMV, DABVP, Cert. IVUSS, CEO of SonoPath.com

info@SonoPath.com

INTERPRETED BY

Eric Lindquist, DMV

DABVP, Cert. IVUSS

IMAGING PERFORMED BY

Dr. Matthew Olcha

HOSPITAL NAME

East Meadow VC

REFERRING VET

Dr. Matthew Olcha

INVOICE

43490

DATE

6/28/23