



PATIENT

Elsie Davis

SPECIES

Feline

BREED

Domestic Shorthair

SEX

Spayed female

AGE

8 years

WEIGHT

8.6 lbs

INTERPRETED BY

Eric Lindquist, DMV
DABVP, Cert. IVUS

IMAGING PERFORMED BY

Chaley Hunt LVT

HOSPITAL NAME

Relief Scan LLC

REFERRING VET

Dr. Withers

INVOICE

45024

DATE

6/28/23

PRESENTING CLINICAL SIGNS

History: Rule out pancreatic lesions Weight loss over the past 6 months, good appetite, having occasional bouts of diarrhea Starting Vitamin B injections, on PancreaPlus Powder Included thoracic/abdomen radiographs taken 6/23/23

Abnormal PE/Chem/CBC/UA Results: decreased TLI (6.5; n=12-82) decreased cobalamin (<150; n=290-1500);

ULTRASONOGRAPHIC EXAMINATION OF THE ABDOMEN

Urinary System

The **urinary bladder**, trigone, and pelvic urethra presented normal thicknesses and normal tone. The ureters were not visible which is normal. No uroliths or sediment were visualized and anechoic urine was present. No evidence of inflammatory or neoplastic changes was noted. Ureteral papillae were normal.

The **kidneys** revealed normal size and structure, corticomedullary definition and ratio for this age. The cortices presented largely uniform texture with normal echogenic relationship to liver and spleen. Medullary structure differed distinctly from the cortex and no evidence of pelvic dilation was present. The capsules were acceptably uniform without significant irregularities. The left kidney measured 3.8 cm and the right kidney measured 3.83 cm.

Adrenal Glands

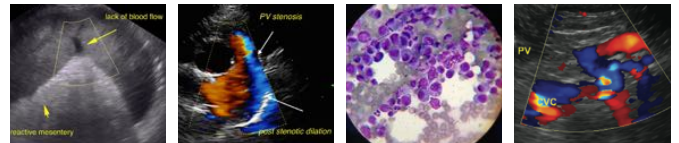
Both **adrenal glands** were visualized and recognized as having normal shape, size, position and echogenicity for this breed. The phrenic vasculature, glandular echogenicity and detail were unremarkable. Capsule, cortex, and medullary definition were normal for this age patient. The left adrenal gland measured 0.38 cm.

Spleen

The **spleen** presented a smooth homogeneous parenchyma hyperechoic to liver and renal cortical parenchyma. The capsule was smooth without noticeable expansion or deviation from within the spleen or adjacent pathology. The splenic vasculature demonstrated normal volume without signs of congestion or thrombosis. No sonographic evidence of acute or chronic inflammatory, neoplastic, or infarctual changes was noted.

Liver

The **liver** images submitted revealed subjectively normal liver size, contour, and structure. Parenchymal echogenicity was naturally coarse and hypoechoic to the spleen. Vascular and biliary tracts were of normal volume with no evidence of congestion. The gallbladder presented acceptably thin walls with primarily anechoic content. The cystic and common bile ducts were normal. No pathological hepatic lymphadenopathy was evident. No overt structural evidence of inflammatory, infiltrative or regenerative pathology was evident.



PATIENT

Gastrointestinal

Elsie Davis

The stomach revealed fluid filled gastric lumen and hyperperistalsis. The gastrointestinal presentation revealed mild uniform prominence of the gastric mucosa as well as areas of "ropey" small intestinal wall with slight disruption of the normal 1:3 muscularis/mucosal ratio. The intestinal submucosa was slightly irregular, thickened and hyperechoic suggestive of low grade, chronic disease. No concerning lymphadenopathy was visible. No evidence of obstruction was present. Chronic inflammatory bowel disease is likely with a low possibility of an early neoplastic event such as lymphoma. Full thickness tissue biopsies via open laparotomy, ideally guided by intraoperative ultrasound in order to obtain the most representative mural sample, would be necessary to rule out this possibility.

SPECIES

Feline

BREED

Domestic Shorthair

SEX

Spayed female

Pancreas

The base and limbs of the **pancreas** were observed to be largely isoechoic to surrounding omental fat. Pancreatic duct and capsular contour were acceptably normal and parenchyma respected normal curvilinear patterns. No overt evidence of active inflammatory or neoplastic disease was noted.

AGE

8 years

ULTRASONOGRAPHIC FINDINGS

Unremarkable abdomen.

WEIGHT

8.6 lbs

Minor, non-specific intestinal thickening.

INTERPRETATION OF THE FINDINGS & FURTHER RECOMMENDATIONS

INTERPRETED BY

Eric Lindquist, DMV
DABVP, Cert. IVUSS

The cause of weight loss is not evident. There was no structural evidence of neoplasia. Maldigestion panel, three view chest radiographs and full CNS examination is recommended to examine for occult disease that could be responsible for the weight loss. Evaluation for competitive eating environments should also be considered.

IMAGING PERFORMED BY

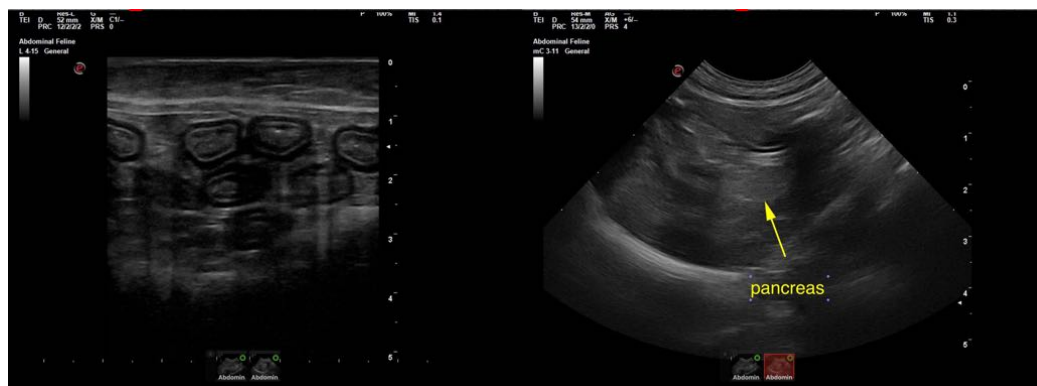
Chaley Hunt LVT

HOSPITAL NAME

Relief Scan LLC

REFERRING VET

Dr. Withers



INVOICE

45024

DATE

6/28/23



PATIENT

Elsie Davis

SPECIES

Feline

BREED

Domestic Shorthair

SEX

Spayed female

AGE

8 years

WEIGHT

8.6 lbs

INTERPRETED BY

Eric Lindquist, DMV
DABVP, Cert. IVUSS

IMAGING PERFORMED BY

Chaley Hunt LVT

HOSPITAL NAME

Relief Scan LLC

REFERRING VET

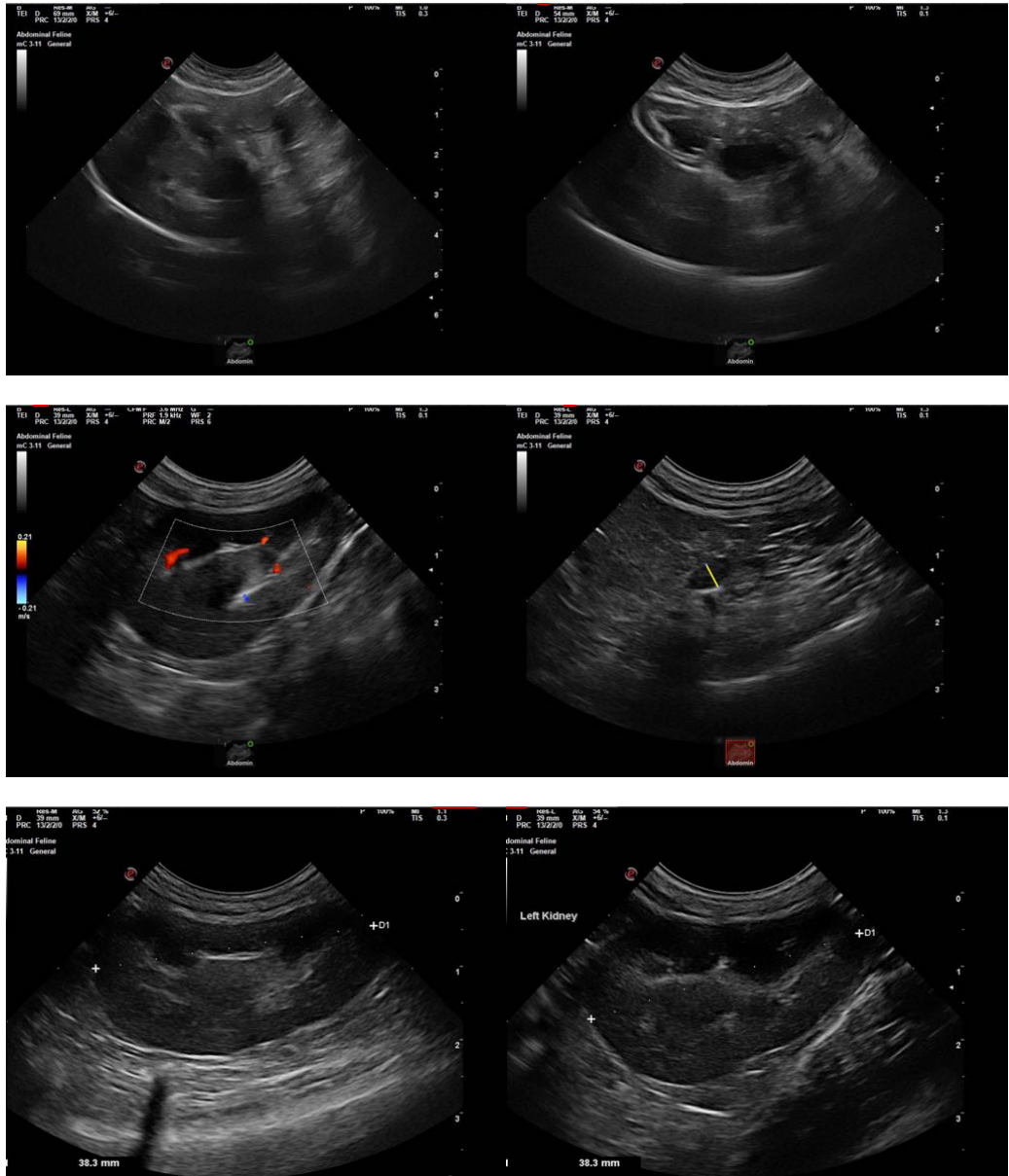
Dr. Withers

INVOICE

45024

DATE

6/28/23



The information and recommendations provided are based on the images presented by the referring veterinarian/sonographer. No evaluation can be communicated regarding pathology that was not visible in the image/video clips provided.

Thank you for this referral. If the clinical or image interpretation does not parallel your findings or if I can be of any further assistance please contact me.

Eric Lindquist, DMV, DABVP, Cert. IVUSS, CEO of SonoPath.com
info@SonoPath.com