



**PATIENT PRESENTING CLINICAL SIGNS**

**Bella Landis**  
History: 4.6 yo FS Maltese Mix 9.75 # Sedated with Butorphanol Hx of kidney enzyme elevations found on routine yearly labwork. Had 1 prior incident of hematuria and rod type bacteria, responsive to clavamox 6 months prior. Bloodwork at yearly: SDMA 14 BUN 81 (H) Creat 2.3 (H) Phos 4.9 Albumin 2.5 (L). Lyme positive, low Quant c6 < 10. UA - USG 1.026, 500 mg/dL proteinuria, cocci, RBC, WBC. Treated with 2 week course amoxi/clav then recheck. Recheck UA USG 1.020 with inactive sediment.  
**Canine**  
Recheck KP creat 2.1 (H), BUN 54 (H), Phos 6.2. UPC 3.62. BP normal. Started on kidney supplement (naraquin with phos binder) and set up for AUS as next step.

**BREED**

Maltese Mix

**ULTRASONOGRAPHIC EXAMINATION OF THE ABDOMEN**

**Urinary System**

**SEX**

Spayed female

The **urinary bladder**, trigone, and pelvic urethra presented normal thicknesses and normal tone. The ureters were not visible which is normal. No uroliths or sediment were visualized and anechoic urine was present. No evidence of inflammatory or neoplastic changes was noted. Ureteral papillae were normal.

**AGE**

4 ½ years

The right **kidney** measured 3.76 cm with increased cortical echogenicity and cortical remodeling with microinfarcts. The left kidney revealed mild changes, yet was less dramatic and measured 3.48 cm. Blood flow to the kidneys appeared to be adequate on Power Doppler assessment.

**WEIGHT**

9.75 lbs

**Adrenal Glands**

**INTERPRETED BY**

Eric Lindquist, DMV  
DABVP, Cert. IVUSS

Both **adrenal glands** were visualized and recognized as having normal shape, size, position and echogenicity for this breed. The phrenic vasculature, glandular echogenicity and detail were unremarkable. Capsule, cortex, and medullary definition were normal for this age patient. The left adrenal gland measured 1.31 x 0.39 cm at the caudal pole and 0.33 cm at the cranial pole. The right adrenal gland measured 1.93 x 0.83 cm at the cranial pole and 0.44 cm at the caudal pole.

**IMAGING PERFORMED BY**

Dr. Carpenter

**Spleen**

**HOSPITAL NAME**

Penridge AH

The **spleen** presented a smooth homogeneous parenchyma hyperechoic to liver and renal cortical parenchyma. The capsule was smooth without noticeable expansion or deviation from within the spleen or adjacent pathology. The splenic vasculature demonstrated normal volume without signs of congestion or thrombosis. No sonographic evidence of acute or chronic inflammatory, neoplastic, or infarctual changes was noted.

**REFERRING VET**

Dr. Depew

**Liver**

**INVOICE**

45033

The **liver** images submitted revealed subjectively normal liver size, contour, and structure. Parenchymal echogenicity was naturally coarse and hypoechoic to the spleen. The portal vein to vena cava ratio was 1:1. There was no evidence of portosystemic shunting. The gallbladder presented acceptably thin walls with primarily anechoic content. The cystic and common bile ducts were normal. No pathological hepatic lymphadenopathy was evident. No overt structural evidence of inflammatory, infiltrative or regenerative pathology was evident.

**DATE**

6/28/23



**PATIENT**

**Gastrointestinal**

Bella Landis

Examination of the **gastrointestinal tract** revealed a stomach and intestine free of stasis, of normal wall thickness, acceptable curvilinear mural detail, and peristaltic activity. Small and large intestine demonstrated normal luminal chyme and stool consistency respectively. No obstructive or overt infiltrative disease was noted. No associated abnormal lymphatic activity was noted.

**SPECIES**

Canine

**Pancreas**

**BREED**

Maltese Mix

The base and limbs of the **pancreas** were observed to be largely isoechoic to surrounding omental fat. Pancreatic duct and capsular contour were acceptably normal and parenchyma respected normal curvilinear patterns. No overt evidence of active inflammatory or neoplastic disease was noted.

**SEX**

Spayed female

**ULTRASONOGRAPHIC FINDINGS**

**AGE**

4 ½ years

Mild to moderate chronic renal changes and infarcts in the right kidney, minor on the left. Increased cortical echogenicity, consistent with interstitial nephrosis. The changes were not end stage.

**INTERPRETATION OF THE FINDINGS & FURTHER RECOMMENDATIONS**

**WEIGHT**

9.75 lbs

Acute insult such as Leptospirosis is possible. However, the changes are not end stage. Acute insult such as Leptospirosis or toxin exposure should be considered. The remainder of the abdomen was unremarkable. There is a strong potential for Lyme nephritis. Renal biopsy would be necessary for further definition. 72- hour IV fluid protocol, blood pressure measurements +/- urine culture are all indicated.

**INTERPRETED BY**

Eric Lindquist, DMV  
DABVP, Cert. IVUSS

**IMAGING PERFORMED BY**

Dr. Carpenter

**HOSPITAL NAME**

Pennridge AH

**REFERRING VET**

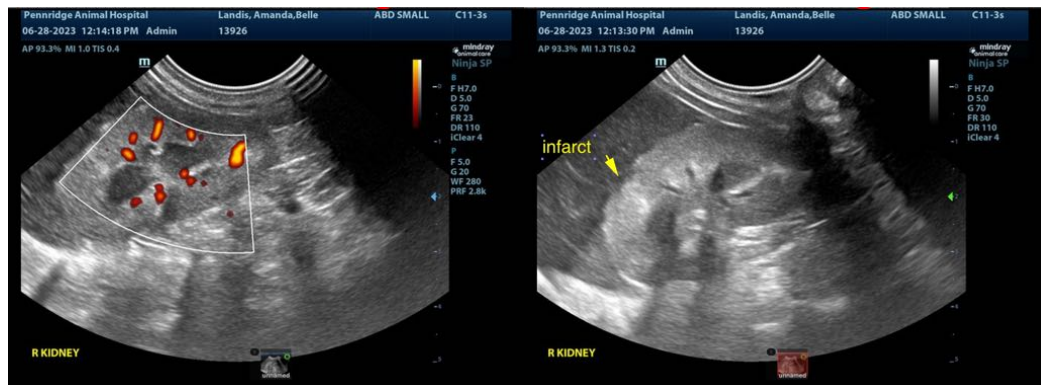
Dr. Depew

**INVOICE**

45033

**DATE**

6/28/23





**PATIENT**

Bella Landis

**SPECIES**

Canine

**BREED**

Maltese Mix

**SEX**

Spayed female

**AGE**

4 ½ years

**WEIGHT**

9.75 lbs

**INTERPRETED BY**

Eric Lindquist, DMV  
DABVP, Cert. IVUSS

**IMAGING PERFORMED BY**

Dr. Carpenter

**HOSPITAL NAME**

Pennridge AH

**REFERRING VET**

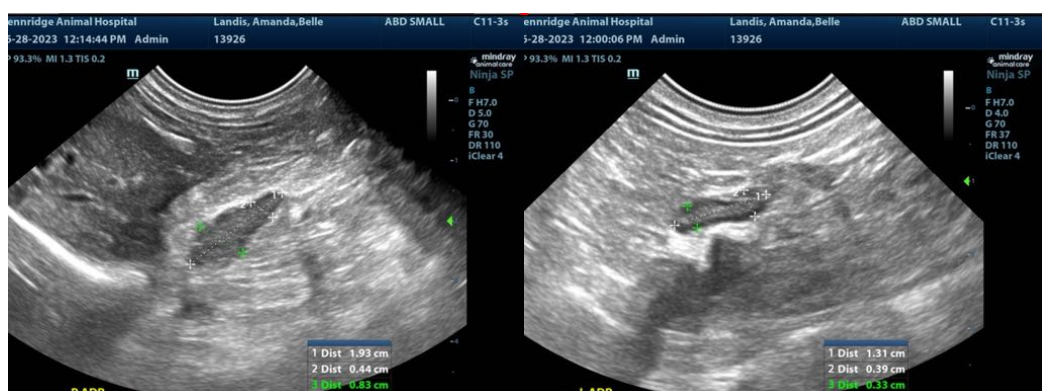
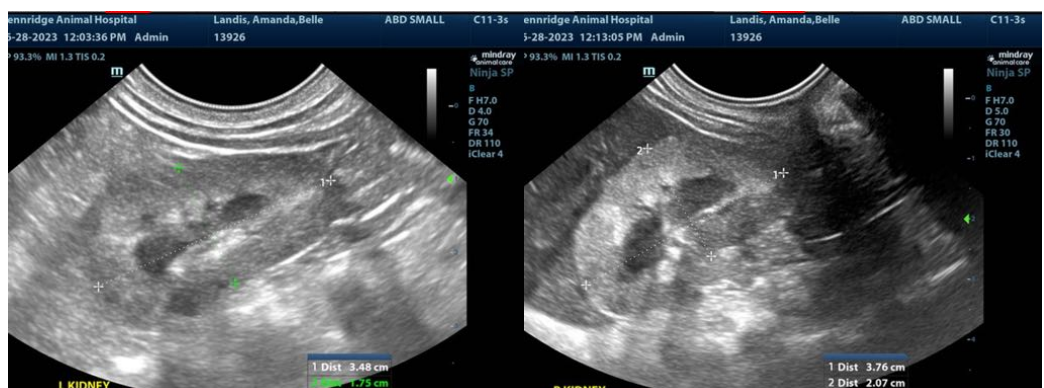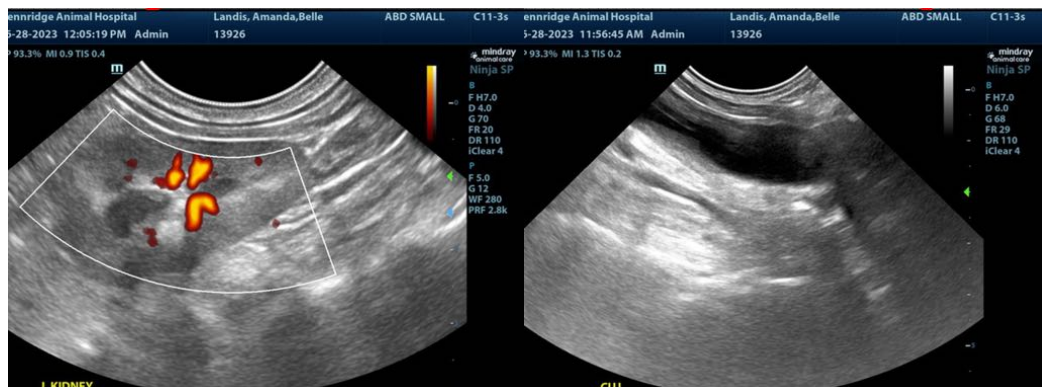
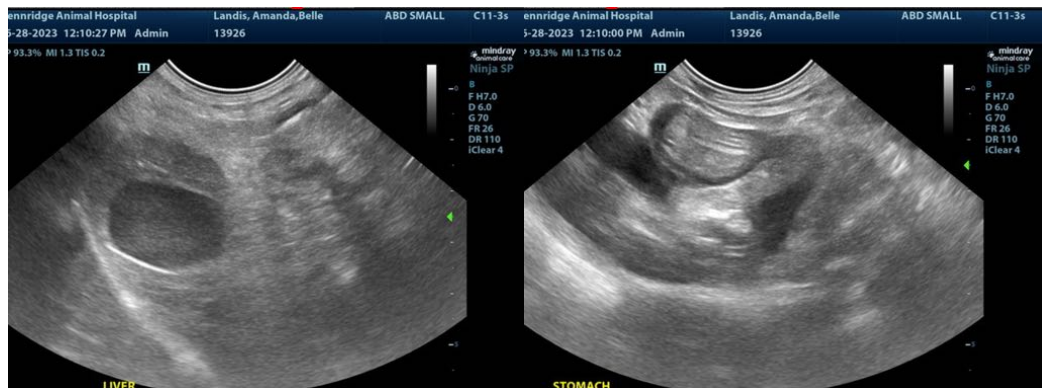
Dr. Depew

**INVOICE**

45033

**DATE**

6/28/23





**PATIENT**

Bella Landis

The information and recommendations provided are based on the images presented by the referring veterinarian/sonographer. No evaluation can be communicated regarding pathology that was not visible in the image/video clips provided.

**SPECIES**

Canine

Thank you for this referral. If the clinical or image interpretation does not parallel your findings or if I can be of any further assistance please contact me.

**BREED**

Maltese Mix

**Eric Lindquist**, DMV, DABVP, Cert. IVUSS, CEO of SonoPath.com  
info@SonoPath.com

**SEX**

Spayed female

**AGE**

4 ½ years

**WEIGHT**

9.75 lbs

**INTERPRETED BY**

Eric Lindquist, DMV  
DABVP, Cert. IVUSS

**IMAGING  
PERFORMED BY**

Dr. Carpenter

**HOSPITAL NAME**

Pennridge AH

**REFERRING VET**

Dr. Depew

**INVOICE**

45033

**DATE**

6/28/23