



PATIENT PRESENTING CLINICAL SIGNS

Sky Avery HAs had urinary incontinence since 1 yer of age. Proin at 1-2 times a day has worked. Now uncontrolled incontinence when sleeping. HHave tried Proin 50 mg TID, Incurin 1 mg SID , DES 05. mg PO SID x 5 days then 1 day off.

SPECIES Abnormal PE/Chem/CBC/UA Results: USG 1.025, No other abnormalities, BW WNL

Canine

ULTRASONOGRAPHIC EXAMINATION OF THE ABDOMEN

BREED *Urinary System*

Mix The **urinary bladder** and trigone presented normal thicknesses. The pelvic urethra revealed subjectively poor tone. The ureters were not visible which is normal. No uroliths or sediment were visualized and anechoic urine was present. No evidence of inflammatory or neoplastic changes was noted. Ureteral papillae were normal.

SEX

Spayed Female The uterine stump was unremarkable and measured 0.4 cm in width.

AGE

10 years The **kidneys** revealed normal size and structure, corticomedullary definition and ratio for this age. The cortices presented largely uniform texture with normal echogenic relationship to liver and spleen. Medullary structure differed distinctly from the cortex and no evidence of pelvic dilation was present. The capsules were acceptably uniform without significant irregularities. The left kidney measured 6.27 cm. The right kidney measured 6.15 cm.

WEIGHT

60 lbs

ULTRASONOGRAPHIC FINDINGS

Structurally normal urinary tract with subjectively poor urethral tone.

INTERPRETED BY

Eric Lindquist, DMV
DABVP, Cert. IVUSS

INTERPRETATION OF THE FINDINGS & FURTHER RECOMMENDATIONS

Primary incontinence is suspected. Predisposing issues such as recessed vulva or urine pooling in the vaginal vault should be considered. There was no evidence of structural disease.

IMAGING PERFORMED BY

Dr. Ammeraal

HOSPITAL NAME

Sova AH

REFERRING VET

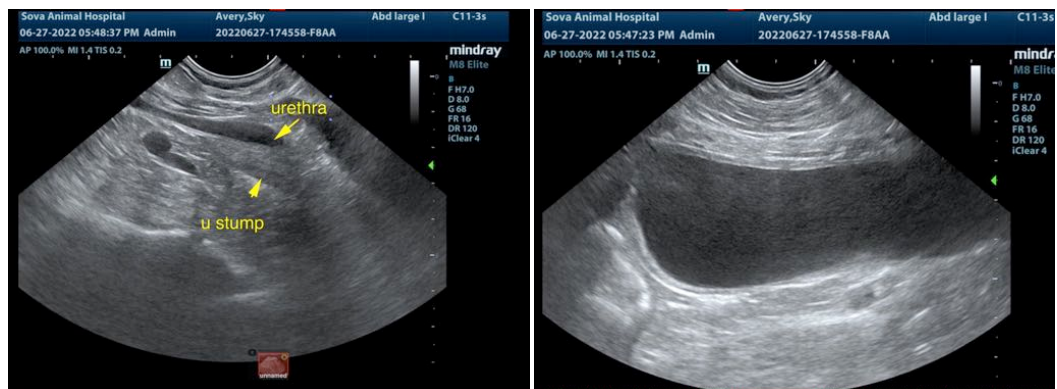
Dr. Ammeraal

INVOICE

31302

DATE

6/27/22





PATIENT

Sky Avery

SPECIES

Canine

BREED

Mix

SEX

Spayed Female

AGE

10 years

WEIGHT

60 lbs

INTERPRETED BY

Eric Lindquist, DMV
DABVP, Cert. IVUSS

**IMAGING
PERFORMED BY**

Dr. Ammeraal

HOSPITAL NAME

Sova AH

REFERRING VET

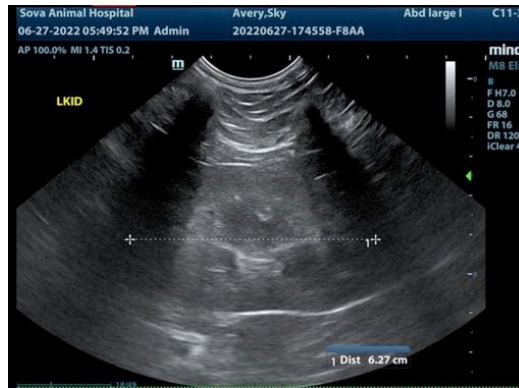
Dr. Ammeraal

INVOICE

31302

DATE

6/27/22



The information and recommendations provided are based on the images presented by the referring veterinarian/sonographer. No evaluation can be communicated regarding pathology that was not visible in the image/video clips provided.

Thank you for this referral. If the clinical or image interpretation does not parallel your findings or if I can be of any further assistance please contact me.

Eric Lindquist, DMV, DABVP, Cert. IVUSS, CEO of SonoPath.com
info@SonoPath.com