



PATIENT

Owen Miller

SPECIES

Canine

BREED

Border Collie Mix

SEX

Neutered male

AGE

7 years

WEIGHT

62 lbs

INTERPRETED BY

Eric Lindquist, DMV
DABVP, Cert. IVUSS

IMAGING PERFORMED BY

Dr. Bartus

HOSPITAL NAME

Valley Veterinary
Service

REFERRING VET

Dr. Bartus

INVOICE

31303

DATE

6/28/22

PRESENTING CLINICAL SIGNS

Owner noticed drooling, poor appetite 3 wk ago, but then it passed after one day. Yesterday, owner noticed drooling again, and he won't eat at all. Per owner, he makes a different noise when panting. He extends his neck when swallowing. Acts as though his throat is sore, per owner. NO history of chewing sticks.

ALT 158 (10-125), has been elevated more (167) in April 2022. Rest of bloodwork is WNL, including T4. Firm swelling is palpable on the right side of the trachea. Looked at tonsils under sedation with Propofol, and they are not enlarged and the throat area does not appear inflamed.

ULTRASONOGRAPHIC EXAMINATION OF THE CERVICAL REGION

Multiple images were submitted of the trachea, thyroid and esophageal region. The orientation was not defined but the thyroid and parathyroid tissues were normal. There were no overt masses involved. The cranial esophagus appeared unremarkable. The trachea, visible salivary glands and regional tissues were unremarkable. However, one view revealed a portion of esophagus that appeared to be somewhat thickened at approximately 1.0 cm. Depending upon the clinical palpation aspects are this may reveal underlying esophageal pathology. However, further imaging would be necessary. No overt masses are present.

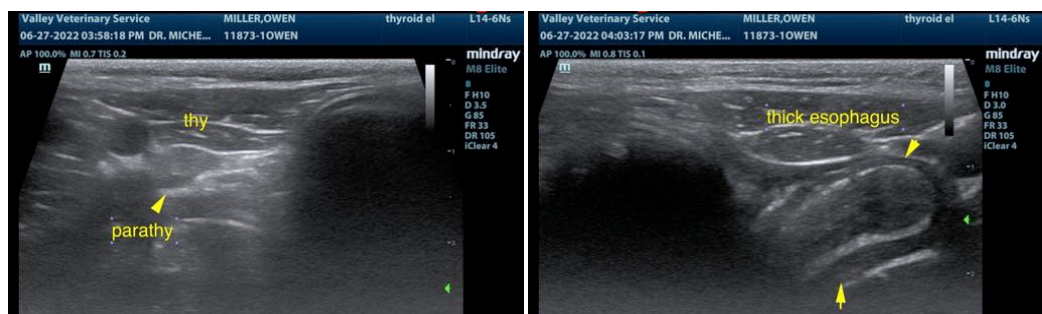
ULTRASONOGRAPHIC FINDINGS

Subjectively thickened esophagus.

Normal thyroid and parathyroid areas.

INTERPRETATION OF THE FINDINGS & FURTHER RECOMMENDATIONS

Given the patient's history endoscopy is warranted for esophagitis. There is no evidence of foreign body or obvious neoplasia. CT of the cervical region would also be helpful.





PATIENT

Owen Miller

SPECIES

Canine

BREED

Border Collie Mix

SEX

Neutered male

AGE

7 years

WEIGHT

62 lbs

INTERPRETED BY

Eric Lindquist, DMV
DABVP, Cert. IVUSS

IMAGING PERFORMED BY

Dr. Bartus

HOSPITAL NAME

Valley Veterinary
Service

REFERRING VET

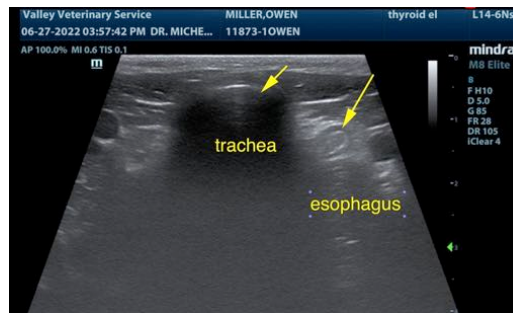
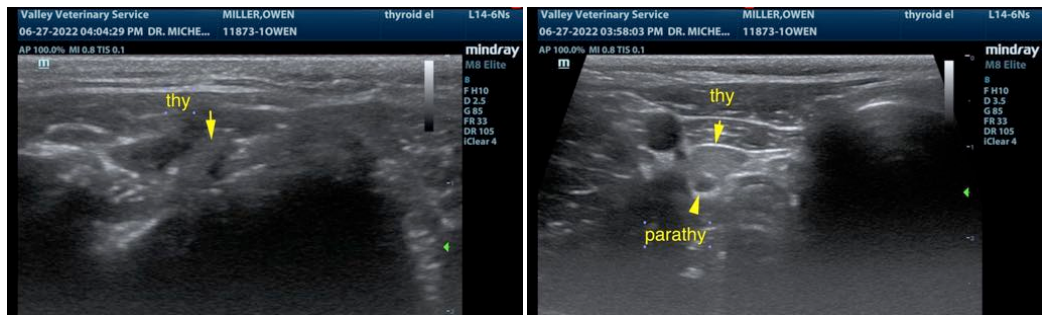
Dr. Bartus

INVOICE

31303

DATE

6/28/22



The information and recommendations provided are based on the images presented by the referring veterinarian/sonographer. No evaluation can be communicated regarding pathology that was not visible in the image/video clips provided.

Thank you for this referral. If the clinical or image interpretation does not parallel your findings or if I can be of any further assistance please contact me.

Eric Lindquist, DMV, DABVP, Cert. IVUSS, CEO of SonoPath.com
info@SonoPath.com