



PATIENT

Charlie Locatelli

PRESENTING CLINICAL SIGNS

History: ongoing gastrointestinal symptoms, including vomiting and diarrhea Had hx of giardia, which has been cleared.
Abnormal PE/Chem/CBC/UA Results: CBC shows neutrophilia with left shift and monocytosis.

SPECIES

Canine

ULTRASONOGRAPHIC EXAMINATION OF THE ABDOMEN

Urinary System

The **urinary bladder**, trigone, and pelvic urethra presented normal thicknesses and normal tone. The ureters were not visible which is normal. No uroliths or sediment were visualized and anechoic urine was present. No evidence of inflammatory or neoplastic changes was noted. Ureteral papillae were normal.

BREED

Welsh Corgi

SEX

Male

The **kidneys** revealed normal size and structure, corticomedullary definition and ratio for this age. The cortices presented largely uniform texture with normal echogenic relationship to liver and spleen. Medullary structure differed distinctly from the cortex and no evidence of pelvic dilation was present. The capsules were acceptably uniform without significant irregularities. The kidneys both measured 6.0 cm.

AGE

6 months

WEIGHT

9.6 kg

Adrenal Glands

The **adrenal glands** were not visualized.

INTERPRETED BY

Eric Lindquist, DMV
DABVP, Cert. IVUSS

Spleen

The **spleen** presented a smooth homogeneous parenchyma hyperechoic to liver and renal cortical parenchyma. The capsule was smooth without noticeable expansion or deviation from within the spleen or adjacent pathology. The splenic vasculature demonstrated normal volume without signs of congestion or thrombosis. No sonographic evidence of acute or chronic inflammatory, neoplastic, or infarctual changes was noted.

IMAGING PERFORMED BY

Dr. Singh

HOSPITAL NAME

Balmy Beach Pet
Hospital

Liver

The **liver** images submitted revealed subjectively normal liver size, contour, and structure. Parenchymal echogenicity was naturally coarse and hypoechoic to the spleen. Vascular and biliary tracts were of normal volume with no evidence of congestion. The gallbladder presented acceptably thin walls with primarily anechoic content. The cystic and common bile ducts were normal. No pathological hepatic lymphadenopathy was evident. No overt structural evidence of inflammatory, infiltrative or regenerative pathology was evident.

REFERRING VET

Dr. Singh

INVOICE

31277

Gastrointestinal

DATE

6/27/22

Examination of the **gastrointestinal tract** revealed a stomach and intestine free of stasis, of normal wall thickness, acceptable curvilinear mural detail, and peristaltic activity. Small and large intestine



PATIENT

Charlie Locatelli

demonstrated normal luminal chyme and stool consistency respectively. No obstructive or overt infiltrative disease was noted. The mesenteric lymph node was enlarged and measured 0.9 x 0.78 cm.

SPECIES

Canine

Pancreas

The base and limbs of the **pancreas** were observed to be largely isoechoic to surrounding omental fat. Pancreatic duct and capsular contour were acceptably normal and parenchyma respected normal curvilinear patterns. No overt evidence of active inflammatory or neoplastic disease was noted.

BREED

Welsh Corgi

ULTRASONOGRAPHIC FINDINGS

SEX

Male

Minor mesenteric lymphadenopathy, reactive.

AGE

6 months

INTERPRETATION OF THE FINDINGS & FURTHER RECOMMENDATIONS

Lymph node enlargement is normal for this age patient. There is no evidence of structural disease.

WEIGHT

9.6 kg

INTERPRETED BY

Eric Lindquist, DMV
DABVP, Cert. IVUSS

IMAGING PERFORMED BY

Dr. Singh

HOSPITAL NAME

Balmy Beach Pet
Hospital

REFERRING VET

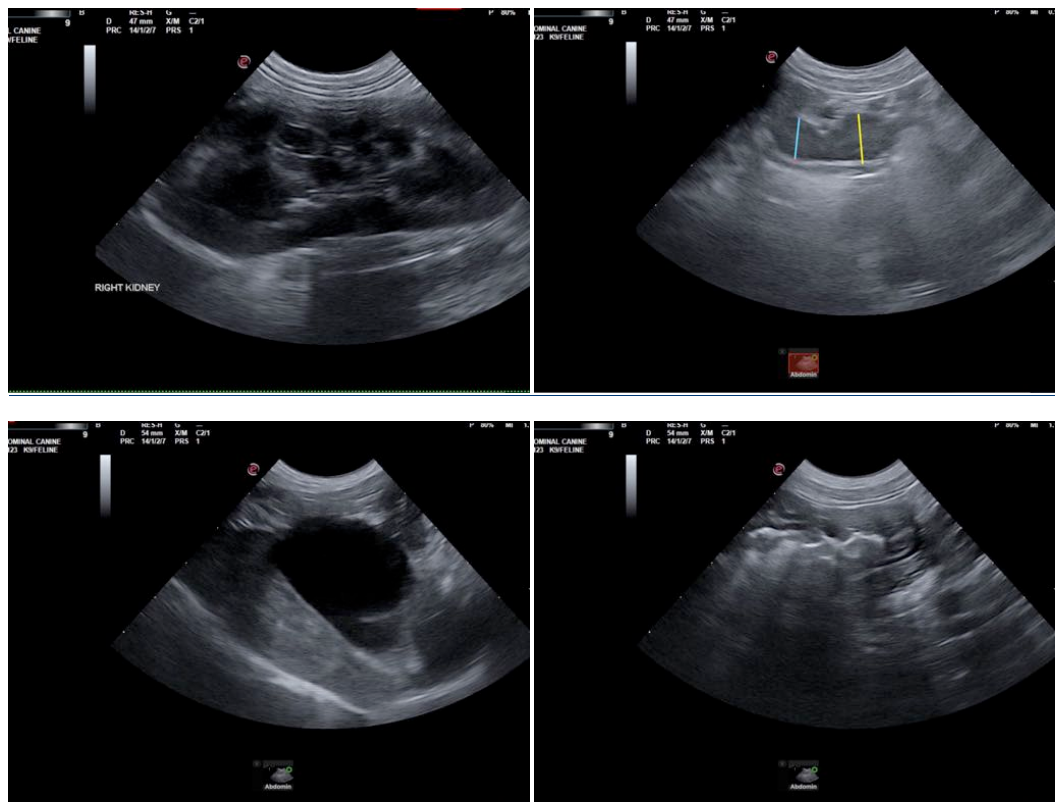
Dr. Singh

INVOICE

31277

DATE

6/27/22





PATIENT

Charlie Locatelli

SPECIES

Canine

BREED

Welsh Corgi

SEX

Male

AGE

6 months

WEIGHT

9.6 kg

INTERPRETED BY

Eric Lindquist, DMV
DABVP, Cert. IVUSS

**IMAGING
PERFORMED BY**

Dr. Singh

HOSPITAL NAME

Balmy Beach Pet
Hospital

REFERRING VET

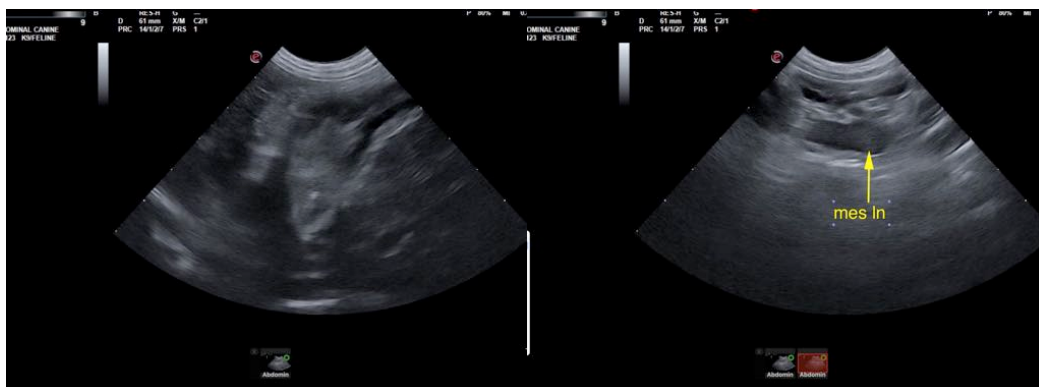
Dr. Singh

INVOICE

31277

DATE

6/27/22



The information and recommendations provided are based on the images presented by the referring veterinarian/sonographer. No evaluation can be communicated regarding pathology that was not visible in the image/video clips provided.

Thank you for this referral. If the clinical or image interpretation does not parallel your findings or if I can be of any further assistance please contact me.

Eric Lindquist, DMV, DABVP, Cert. IVUSS, CEO of SonoPath.com
info@SonoPath.com