

PATIENT

Luna Ghelli

PRESENTING CLINICAL SIGNS

History: re check from 6/22 showed shadowing material in stomach

SPECIES

Canine

LIMITED ULTRASONOGRAPHIC EXAMINATION

The **stomach** was empty in this patient. No further delayed outflow pattern was noted. The small intestine and colon were unremarkable.

BREED

Lab Mix

ULTRASONOGRAPHIC FINDINGS

- Normalized GI tract

SEX

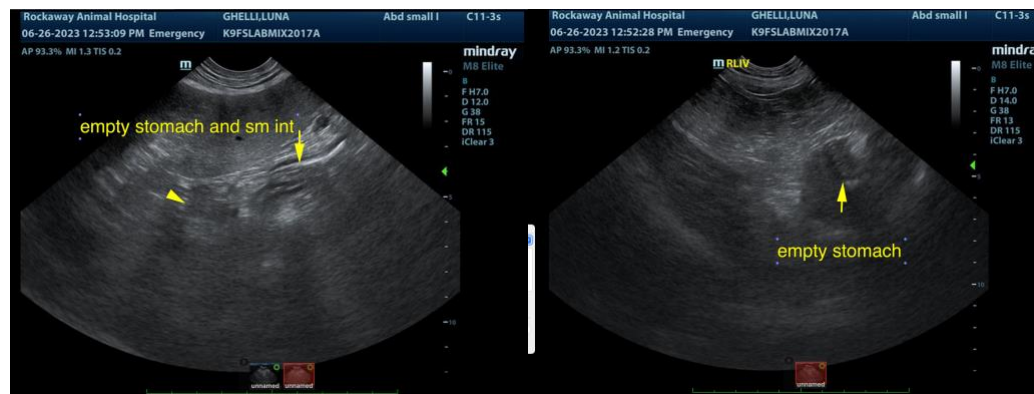
Spayed Female

INTERPRETATION OF THE FINDINGS & FURTHER RECOMMENDATIONS

No evidence of residual GI pathology.

AGE

5



WEIGHT

75

INTERPRETED BY

Eric Lindquist, DMV
DABVP, Cert. IVUSS

The information and recommendations provided are based on the images presented by the referring veterinarian. No evaluation can be communicated regarding pathology that was not visible in the image/video clips provided.

IMAGING PERFORMED BY

Jenn

Thank you for this referral. If the clinical or image interpretation does not parallel your findings or if I can be of any further assistance please contact me.

HOSPITAL NAME

Rockaway AH

Eric Lindquist, DMV, DABVP, Cert. IVUSS, CEO of SonoPath.com
info@SonoPath.com

REFERRING VET

Dr. Maniar

INVOICE

23077

DATE

6/26/23