

**PATIENT**

Luna Morel

**SPECIES**

Canine

**BREED**

Boxer

**SEX**

Spayed Female

**AGE**

9 Years

**WEIGHT**

33.4 kg

**INTERPRETED BY**

Eric Lindquist, DMV  
DABVP, Cert. IVUSS

**IMAGING PERFORMED BY**

Erin Wicks

**HOSPITAL NAME**

Shores VEC

**REFERRING VET**

Dr. Monroe

**INVOICE**

23067

**DATE**

6/25/23

**PRESENTING CLINICAL SIGNS**

History: Presented at our hospital for panting and dry heaving at home. P has been panting and uncomfortable since Thursday and stomach has been making gurgling noises. P head always hanging low, panting, and could not pass BM. P had 5 episodes of dry heaving and waking up in the middle of the night uncomfortable. P V+ twice on the way here yellow bile. Previous Health Concerns: Elevated liver enzymes Current Medications: Thyroid, Ursodiol (2 ½ weeks ago), Denamarin

Abnormal PE/Chem/CBC/UA Results: Respiratory: increase BV sounds; some increase abdominal component Abdominal: full/tender rads- age related pulmonary changes(?) questionable sternal lymph node enlargement; Abd- mild decreased detail( effusion vs inflammation) no obvious fb/ obstruction; vertebral spondylosis ( thoracic) BW- CBC relative and absolute lymphocytosis( 6.19K, 53.5%) ; relative neutropenia( 44.1%)/ eosinopenia( 0.04k) Chem- ALT 169(H) ALP >993(H) lipase unreadable Amylase 2244(H) EPOC- K+ 3.4(L) iCa+ 1.11(L) Hct 60% (H)

**ULTRASONOGRAPHIC EXAMINATION OF THE ABDOMEN**

**Urinary System**

The **urinary bladder**, trigone, and pelvic urethra presented normal thicknesses and normal tone. The ureters were not visible which is normal. No uroliths or sediment were visualized and anechoic urine was present. No evidence of inflammatory or neoplastic changes were noted. Ureteral papillae were normal.

The **left kidney** was normal in size and contour. The left kidney measured 7.6 cm.

The **right kidney** was enlarged and irregular in contour, in two different views, primarily at the cranial pole. It appeared to have a mass formation; however, angular, irregular swelling could not be ruled out. The right kidney measured 8.45 cm.

**Adrenal Glands**

The **adrenal glands** were not visualized.

**Spleen**

The **spleen** was enlarged and irregular with scalloping contour.

**Liver**

The **liver** was swollen and mildly irregular. The gallbladder and common bile duct were unremarkable. No evidence of passive congestion.

**Gastrointestinal**

The **upper gastrointestinal tract** was enveloped by the multiple areas of nodular irregular parenchymal changes in the pancreas. Variable intestinal thickening was noted. No loss of mural detail was noted.

**Pancreas**

The **pancreas** was enveloped by multiple areas of nodular, irregular parenchymal changes, suggestive for inflammation, enveloping the upper gastrointestinal tract.

**Free Abdomen**



**PATIENT**

Luna Morel

The cranial abdomen revealed a significant amount of reactive **mesentery**. Echogenic free fluid was noted throughout the cranial abdomen as well, suggestive for inflammatory or neoplastic event.

**ULTRASONOGRAPHIC FINDINGS**

**SPECIES**

Canine

- Strong concern for infiltrative disease- mastocytosis, lymphomatosis or similar vs abdominal inflammatory event involving the spleen, kidneys (primarily the right kidney), liver, free fluid, omentum and pancreas.

**BREED**

Boxer

- Variable intestinal thickening

**SEX**

Spayed Female

**INTERPRETATION OF THE FINDINGS & FURTHER RECOMMENDATIONS**

Abdominocentesis and cytospin of the free fluid, FNA of the spleen, liver and cranial pole of the right kidney are all indicated. Prognosis is very guarded, depending upon cytology results and responsiveness to therapy. This more than a typical pancreatitis case given the multiple organs involved.

**AGE**

9 Years

**WEIGHT**

33.4 kg

**INTERPRETED BY**

Eric Lindquist, DMV  
DABVP, Cert. IVUSS

**IMAGING PERFORMED BY**

Erin Wicks

**HOSPITAL NAME**

Shores VEC

**REFERRING VET**

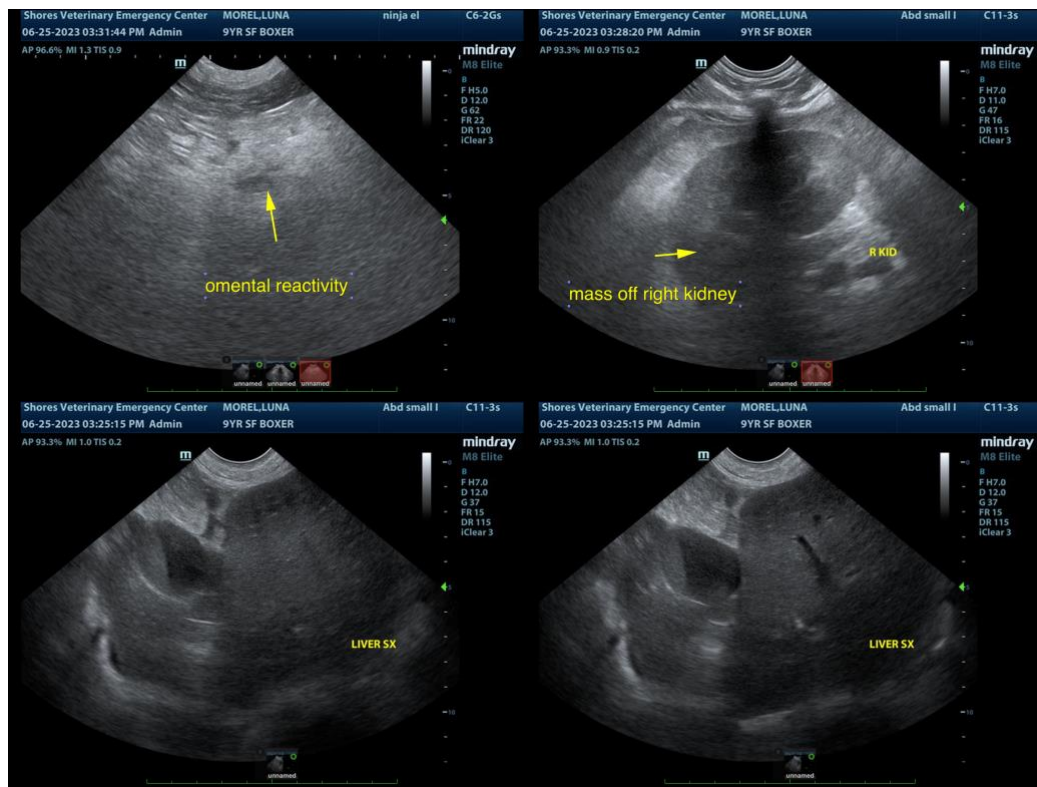Dr. Monroe

**INVOICE**

23067

**DATE**

6/25/23





**PATIENT**

Luna Morel

**SPECIES**

Canine

**BREED**

Boxer

**SEX**

Spayed Female

**AGE**

9 Years

**WEIGHT**

33.4 kg

**INTERPRETED BY**

Eric Lindquist, DMV  
DABVP, Cert. IVUSS

**IMAGING PERFORMED BY**

Erin Wicks

**HOSPITAL NAME**

Shores VEC

**REFERRING VET**

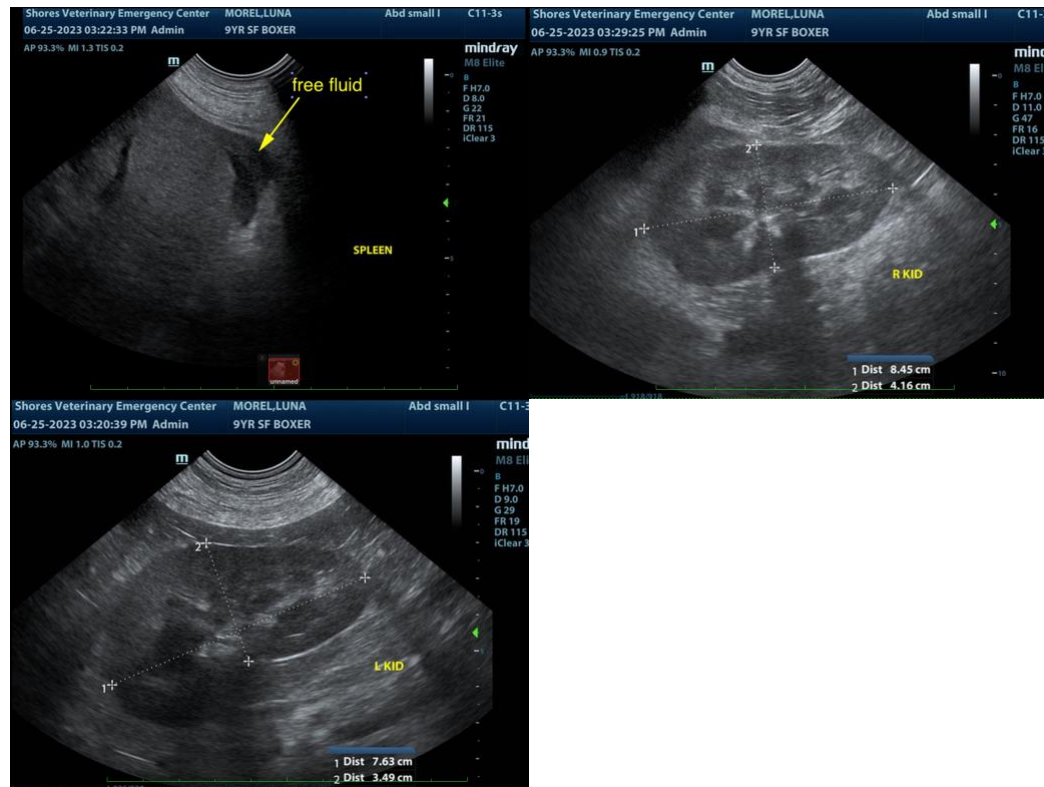
Dr. Monroe

**INVOICE**

23067

**DATE**

6/25/23



The information and recommendations provided are based on the images presented by the referring veterinarian. No evaluation can be communicated regarding pathology that was not visible in the image/video clips provided.

Thank you for this referral. If the clinical or image interpretation does not parallel your findings or if I can be of any further assistance please contact me.

**Eric Lindquist**, DMV, DABVP, Cert. IVUSS, CEO of SonoPath.com  
info@SonoPath.com