



PATIENT

Orejas Lainez

SPECIES

Canine

BREED

Beagle

SEX

Neutered Male

AGE

8 Years

WEIGHT

30 Pounds

INTERPRETED BY

Eric Lindquist, DMV
DABVP, Cert. IVUSS

IMAGING PERFORMED BY

Kyoung Han

HOSPITAL NAME

Tenafly VC

REFERRING VET

Dr. Kyoung Han

INVOICE

16287

DATE

6/24/22

PRESENTING CLINICAL SIGNS

History: elevated globulin (7.6) and white blood cell count. His vital signs are normal today. 4dx - negative and other chemistry is normal. p has bloody diarrhea 3 days ago and he got improved with metro / clavamox / probiotic

ULTRASONOGRAPHIC EXAMINATION OF THE ABDOMEN

Urinary System

The **urinary bladder**, trigone, and pelvic urethra presented normal thicknesses and normal tone. The ureters were not visible which is normal. No uroliths or sediment were visualized, and anechoic urine was present. No evidence of inflammatory or neoplastic changes were noted. Ureteral papillae were normal.

The **kidneys** revealed normal size and structure, corticomedullary definition and ratio for this age. The cortices presented largely uniform texture with normal echogenic relationship to liver and spleen. Medullary structure differed distinctly from the cortex and no evidence of pelvic dilation was present. The capsules were acceptably uniform without significant irregularities. The right kidney measured 4.0 cm. The left kidney measured 4.0 cm.

Adrenal Glands

The regions of the **adrenal glands** were imaged and revealed no evidence of pathology.

Spleen

The **spleen** was uniform. Cranial folding of the spleen was noted. Minor heterogeneous parenchyma changes were noted.

Liver

The **liver** images submitted revealed subjectively normal liver size, contour, and structure. Parenchymal echogenicity was naturally coarse and hypoechoic to the spleen. Vascular and biliary tracts were of normal volume with no evidence of congestion. The gallbladder presented acceptably thin walls with primarily anechoic content. The cystic and common bile ducts were normal. No pathological hepatic lymphadenopathy was evident. No overt structural evidence of inflammatory, infiltrative or regenerative pathology was evident.

Gastrointestinal

Examination of the **gastrointestinal tract** revealed a stomach and intestine free of stasis, of normal wall thickness, acceptable curvilinear mural detail, and peristaltic activity. Small and large intestine demonstrated normal luminal chyme and stool consistency respectively. No obstructive or overt infiltrative disease was noted. No associated abnormal lymphatic activity was noted. Minor excessive GI gas was noted yet no evidence of structural disease.

Pancreas

The base and limbs of the **pancreas** were observed to be largely isoechoic to surrounding omental fat. Pancreatic duct and capsular contour were acceptably normal and parenchyma respected normal curvilinear patterns. No overt evidence of active inflammatory or neoplastic disease was noted.

ULTRASONOGRAPHIC FINDINGS



PATIENT

Orejas Lainez

- Structurally unremarkable abdomen
- Heterogeneous spleen with splenic folding

INTERPRETATION OF THE FINDINGS & FURTHER RECOMMENDATIONS

SPECIES

Canine

Supportive care should prove effective. No evidence of structural disease. Screening for Addisons may be appropriate.

BREED

Beagle

SEX

Neutered Male

AGE

8 Years

WEIGHT

30 Pounds

INTERPRETED BY

Eric Lindquist, DMV
DABVP, Cert. IVUSS

IMAGING PERFORMED BY

Kyoung Han

HOSPITAL NAME

Tenafly VC

REFERRING VET

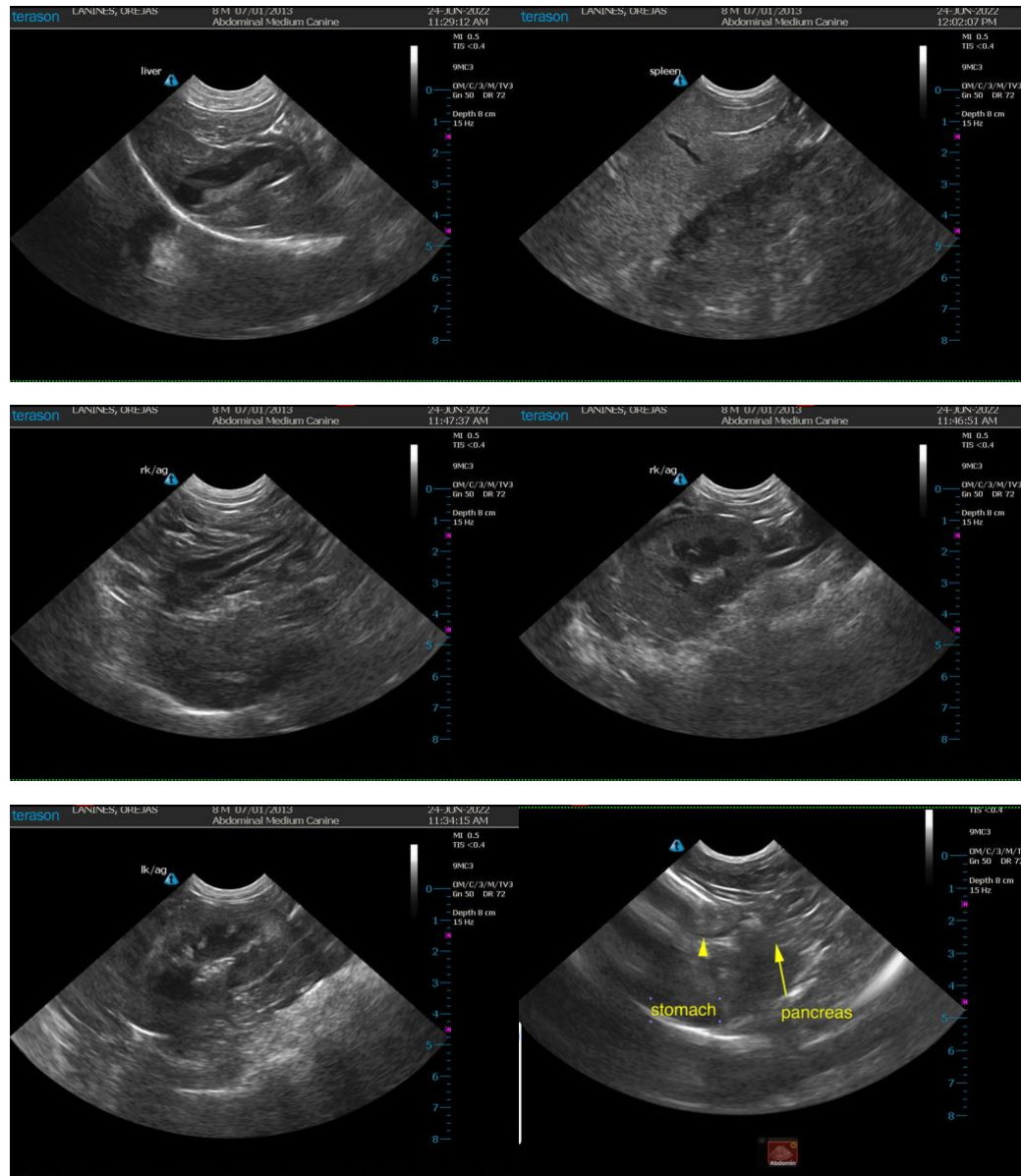
Dr. Kyoung Han

INVOICE

16287

DATE

6/24/22



The information and recommendations provided are based on the images presented by the referring veterinarian. No evaluation can be communicated regarding pathology that was not visible in the image/video clips provided.

Thank you for this referral. If the clinical or image interpretation does not parallel your findings or if I can be of any further assistance please contact me.



PATIENT

Orejas Lainez

Eric Lindquist, DMV, DABVP, Cert. IVUSS, CEO of SonoPath.com
info@SonoPath.com

SPECIES

Canine

BREED

Beagle

SEX

Neutered Male

AGE

8 Years

WEIGHT

30 Pounds

INTERPRETED BY

Eric Lindquist, DMV
DABVP, Cert. IVUSS

**IMAGING
PERFORMED BY**

Kyoung Han

HOSPITAL NAME

Tenaflly VC

REFERRING VET

Dr. Kyoung Han

INVOICE

16287

DATE

6/24/22