



**PATIENT PRESENTING CLINICAL SIGNS**

Maible Dixon

History: unable to hold urine in bladder post sx, just small amounts frequently (was able to hold full bladder prior to sx), straining to urinate. urogenital u/s post ectopic ureter sx, check for extra membrane in bladder as seen at cystoscopy. Was at referral clinic for surgery for ectopic ureter surgery and then they discovered an extra membrane in bladder which was also corrected. Not responding to antibiotics and pain meds. Has had small accidents in the house, squatting constantly. simplicef + metacam  
Abnormal PE/Chem/CBC/UA Results: Last ultrasound(pre surgical) was with us April 1, 2022.

**SPECIES**

Canine

**BREED**

Standard Poodle

**ULTRASONOGRAPHIC EXAMINATION OF THE ABDOMEN**

**Urinary System**

**SEX**

Intact Female

The **urinary bladder** presented a large amount of sand and suspended debris, nonobstructive at the time of the sonogram. A mild amount of urine was present. Overt calculi were noted in the cystourethral junction. No evidence of ectopic ureters.

**AGE**

8 Months

The **uterus** was unremarkable, measuring 4.0 mm.

**WEIGHT**

18 kg

The **kidneys** revealed normal size and structure, corticomedullary definition and ratio for this age. The cortices presented largely uniform texture with normal echogenic relationship to liver and spleen. Medullary structure differed distinctly from the cortex and no evidence of pelvic dilation was present. The capsules were acceptably uniform without significant irregularities. The right kidney measured 4.6 cm. The left kidney measured 5.7 cm.

**Adrenal Glands**

**INTERPRETED BY**

Eric Lindquist, DMV  
DABVP, Cert. IVUSS

Both **adrenal glands** were visualized and recognized as having normal shape, size, position and echogenicity for this breed. The phrenic vasculature, glandular echogenicity and detail were unremarkable. Capsule, cortex, and medullary definition were normal for this age patient. The left adrenal gland measured 1.87 cm x 0.3 cm at the caudal pole and 0.35 cm at the cranial pole. The right adrenal gland measured 1.66 cm x 0.43 cm at the caudal pole and 0.73 cm at the cranial pole.

**IMAGING PERFORMED BY**

Crystal Hill

**Spleen**

**HOSPITAL NAME**

Buck AH

The **spleen** presented a smooth homogeneous parenchyma hyperechoic to liver and renal cortical parenchyma. The capsule was smooth without noticeable expansion or deviation from within the spleen or adjacent pathology. The splenic vasculature demonstrated normal volume without signs of congestion or thrombosis. No sonographic evidence of acute or chronic inflammatory, neoplastic, or infarctual changes were noted.

**REFERRING VET**

Dr. Galbraith

**Liver**

**INVOICE**

16288

The **liver** images submitted revealed subjectively normal liver size, contour, and structure. Parenchymal echogenicity was naturally coarse and hypoechoic to the spleen. Vascular and biliary tracts were of normal volume with no evidence of congestion. The gallbladder presented acceptably thin walls with primarily anechoic content. The cystic and common bile ducts were normal. No pathological hepatic lymphadenopathy was evident. No overt structural evidence of inflammatory, infiltrative or regenerative pathology was evident.

**DATE**

6/24/22

**Gastrointestinal**



**PATIENT**

Maible Dixon

Examination of the **gastrointestinal tract** revealed a stomach and intestine free of stasis, of normal wall thickness, acceptable curvilinear mural detail, and peristaltic activity. Small and large intestine demonstrated normal luminal chyme and stool consistency respectively. No obstructive or overt infiltrative disease was noted. No associated abnormal lymphatic activity was noted.

**SPECIES**

Canine

**Pancreas**

The base and limbs of the **pancreas** were observed to be largely isoechoic to surrounding omental fat. Pancreatic duct and capsular contour were acceptably normal and parenchyma respected normal curvilinear patterns. No overt evidence of active inflammatory or neoplastic disease was noted.

**BREED**

Standard Poodle

**ULTRASONOGRAPHIC FINDINGS**

**SEX**

Intact Female

- Bladder sand and debris, UTI and urolithiasis are evident
- Normal uterus and kidneys

**INTERPRETATION OF THE FINDINGS & FURTHER RECOMMENDATIONS**

**AGE**

8 Months

If ovariohysterectomy is scheduled for this patient, then cystotomy, bladder lavage and sand analysis could be considered. No evidence of ectopic ureters. Otherwise, medical management of urine culture and sensitivity and possible diet change warranted. Structurally, other than the bladder sand and debris, the bladder itself and proximal urethra appeared normal.

**WEIGHT**

18 kg

For an additional charge, internal medicine consult can be utilized through Sonopath.com. You can select the internal medicine drop down at <http://spa.sonopath.com/>.

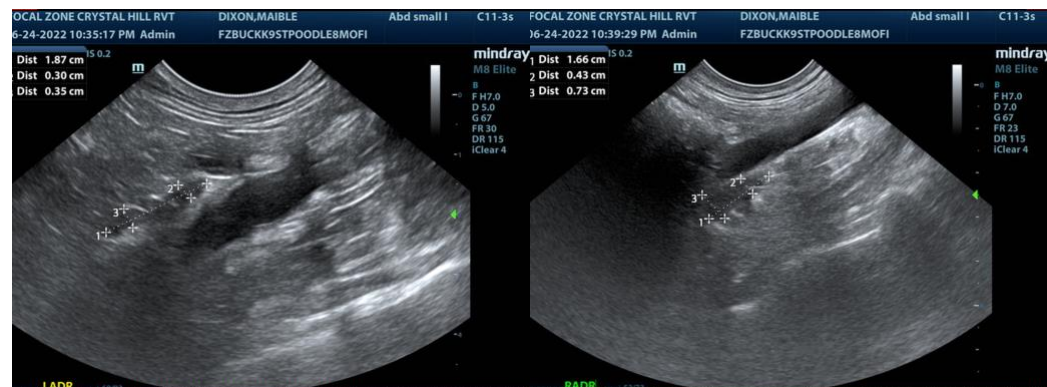
**INTERPRETED BY**

Eric Lindquist, DMV  
DABVP, Cert. IVUSS

One of the world's top internists & SonoPath associate Dr. Remo Lobetti BVSc, MMedVet, PhD, DECVIM can evaluate your case through SonoPath. <https://sonopath.com/resources/sonopath-services/internal-medicine-teleconsultation-services>

**IMAGING PERFORMED BY**

Crystal Hill



**HOSPITAL NAME**

Buck AH

**REFERRING VET**

Dr. Galbraith

**INVOICE**

16288

**DATE**

6/24/22



**PATIENT**

Maible Dixon

**SPECIES**

Canine

**BREED**

Standard Poodle

**SEX**

Intact Female

**AGE**

8 Months

**WEIGHT**

18 kg

**INTERPRETED BY**

Eric Lindquist, DMV  
DABVP, Cert. IVUSS

**IMAGING  
PERFORMED BY**

Crystal Hill

**HOSPITAL NAME**

Buck AH

**REFERRING VET**

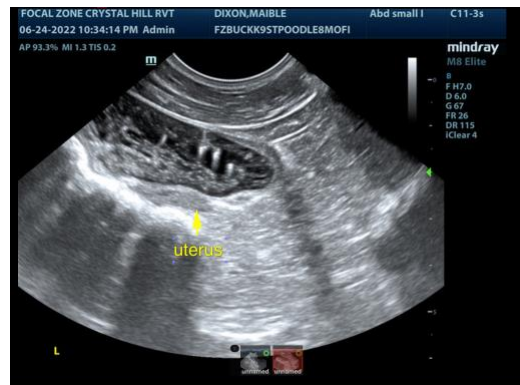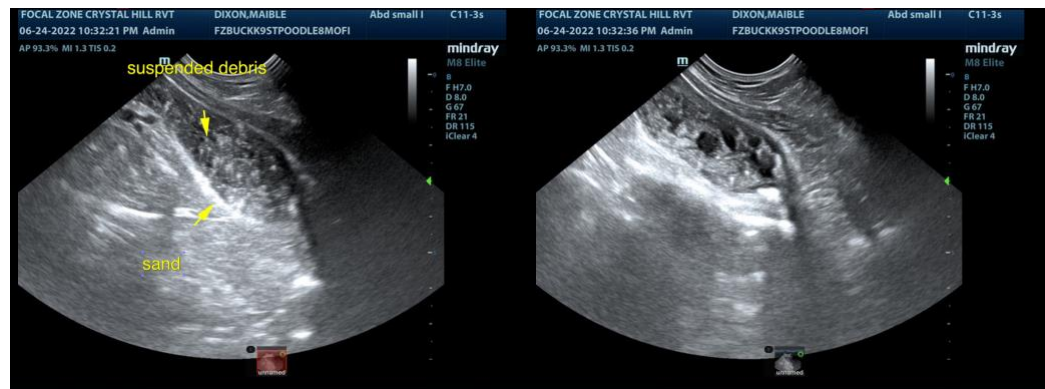
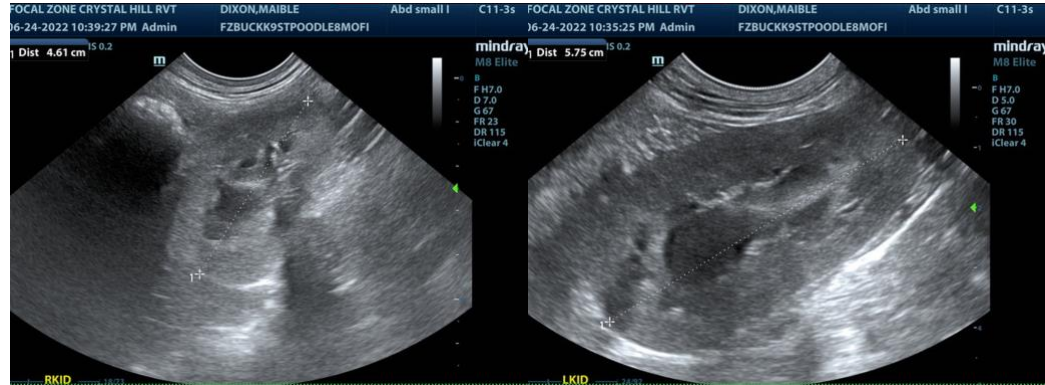
Dr. Galbraith

**INVOICE**

16288

**DATE**

6/24/22



The information and recommendations provided are based on the images presented by the referring veterinarian. No evaluation can be communicated regarding pathology that was not visible in the image/video clips provided.

Thank you for this referral. If the clinical or image interpretation does not parallel your findings or if I can be of any further assistance please contact me.

**Eric Lindquist**, DMV, DABVP, Cert. IVUSS, CEO of SonoPath.com  
Eric.Lindquist@SonoPath.com