



PATIENT

PRESENTING CLINICAL SIGNS

Umber Vanbergen

Ever since a pup, eats very rapidly and then loud burps. Using slow feed bowl, slowed her down a little, but doesn't seem to help the burping. Will also randomly vomit a meal during the day-not predictable which meal. undigested and will eat it. otherwise, normal. started the vomiting daily for 4 days which is why the owners level of concern increased. While on cerenia stopped vomiting. Within 2 days started again. stool is always normal. on low fat gastro diet RC for a long time. Doesn't pass foreign material in her stool-occasional possible mild ingestion of fluff from toys.

SPECIES

Canine

BREED

Shiba Inu

Abnormal PE/Chem/CBC/UA Results: Dog is physically normal in appearance. TPR normal. amylase low 399 (500-1500), rest of chem 17 is normal. Low MCV 52.7 (61.6-73.5), low MCH 19.4 (21.2-25.9)

SEX

ULTRASONOGRAPHIC EXAMINATION OF THE ABDOMEN

Intact Female

Urinary System

AGE

8 Months

The **urinary bladder**, trigone, and pelvic urethra presented normal thicknesses and normal tone. The ureters were not visible which is normal. No uroliths or sediment were visualized and anechoic urine was present. No evidence of inflammatory or neoplastic changes were noted. Ureteral papillae were normal.

WEIGHT

8.5

The **kidneys** revealed normal size and structure, corticomedullary definition and ratio for this age. The cortices presented largely uniform texture with normal echogenic relationship to liver and spleen. Medullary structure differed distinctly from the cortex and no evidence of pelvic dilation was present. The capsules were acceptably uniform without significant irregularities. The left kidney measured 4.4 cm. The right kidney measured 4.4 cm.

INTERPRETED BY

Eric Lindquist, DMV

DABVP, Cert. IVUSS

Adrenal Glands

Both **adrenal glands** were visualized and recognized as having normal shape, size, position and echogenicity for this breed. The phrenic vasculature, glandular echogenicity and detail were unremarkable. Capsule, cortex, and medullary definition were normal for this age patient. The left adrenal gland measured 0.43 cm at the cranial pole and 0.44 cm at the caudal pole.

IMAGING PERFORMED BY

Dr. Judy McFarlen

Spleen

HOSPITAL NAME

Van Isle VH

The **spleen** presented a smooth homogeneous parenchyma hyperechoic to liver and renal cortical parenchyma. The capsule was smooth without noticeable expansion or deviation from within the spleen or adjacent pathology. The splenic vasculature demonstrated normal volume without signs of congestion or thrombosis. No sonographic evidence of acute or chronic inflammatory, neoplastic, or infarctual changes were noted.

REFERRING VET

Dr. Judy McFarlen

INVOICE

23020

DATE

6/23/23

Liver

The **liver** images submitted revealed subjectively normal liver size, contour, and structure. Parenchymal echogenicity was naturally coarse and hypoechoic to the spleen. Vascular and biliary tracts were of normal volume with no evidence of congestion. The gallbladder presented acceptably thin walls with primarily anechoic content. The cystic and common bile ducts were normal. No pathological hepatic lymphadenopathy was evident. No overt structural evidence of inflammatory, infiltrative or regenerative pathology was evident. Portal vein to vena cava ratio was 1:1. No evidence of intrahepatic or extrahepatic shunting.

Gastrointestinal



PATIENT

Umber Vanbergen

The **stomach** revealed a minor amount of ingesta and slight shadowing structures consistent with kibble or pills or possible small foreign bodies were noted. The gastric wall, pylorus and duodenum appear unremarkable. The descending colon presented normal stool consistency.

SPECIES

Pancreas

Canine

The base and limbs of the **pancreas** were observed to be largely isoechoic to surrounding omental fat. Pancreatic duct and capsular contour were acceptably normal and parenchyma respected normal curvilinear patterns. No overt evidence of active inflammatory or neoplastic disease was noted.

BREED

Shiba Inu

Free Abdomen

SEX

The epigastric **lymph nodes** were slightly enlarged (4.0 mm), reactive, consistent with inflammation.

Intact Female

ULTRASONOGRAPHIC FINDINGS

AGE

8 Months

- Slight soft shadowing structures in the pyloric outflow. Postprandial presentation or oral medications are suspected. There is a possibility of small foreign matter.
- Slightly enlarged epigastric lymph nodes

WEIGHT

8.5

INTERPRETATION OF THE FINDINGS & FURTHER RECOMMENDATIONS

INTERPRETED BY

Eric Lindquist, DMV

Assessment of the stomach should be paired with feeding and oral medication history, if any. Diet change and coverage for helicobacter could be considered. If clinical signs persist, then endoscopy is indicated. However, if the patient was not fully NPO, then recheck of the pyloric outflow/SDEP-3 and full NPO for an 18hr period would be indicated.

DABVP, Cert. IVUSS

IMAGING PERFORMED BY

Dr. Judy McFarlen

HOSPITAL NAME

Van Isle VH

REFERRING VET

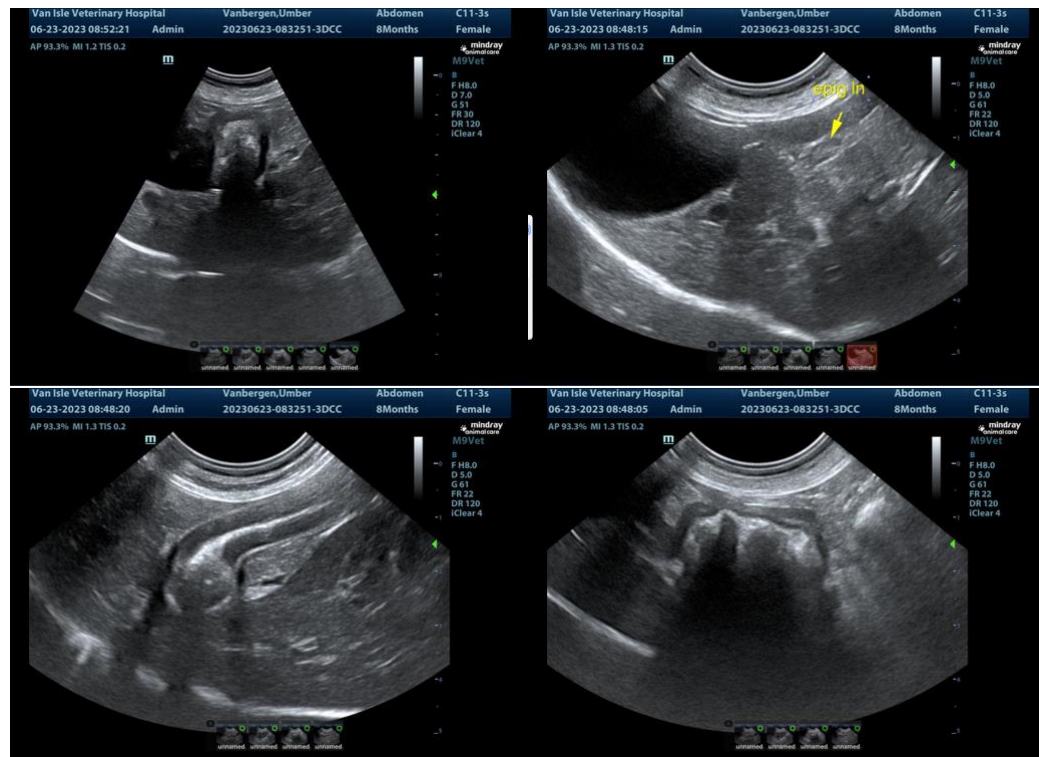
Dr. Judy McFarlen

INVOICE

23020

DATE

6/23/23





PATIENT

Umber Vanbergen

SPECIES

Canine

BREED

Shiba Inu

SEX

Intact Female

AGE

8 Months

WEIGHT

8.5

INTERPRETED BY

Eric Lindquist, DMV

DABVP, Cert. IVUSS

IMAGING PERFORMED BY

Dr. Judy McFarlen

HOSPITAL NAME

Van Isle VH

REFERRING VET

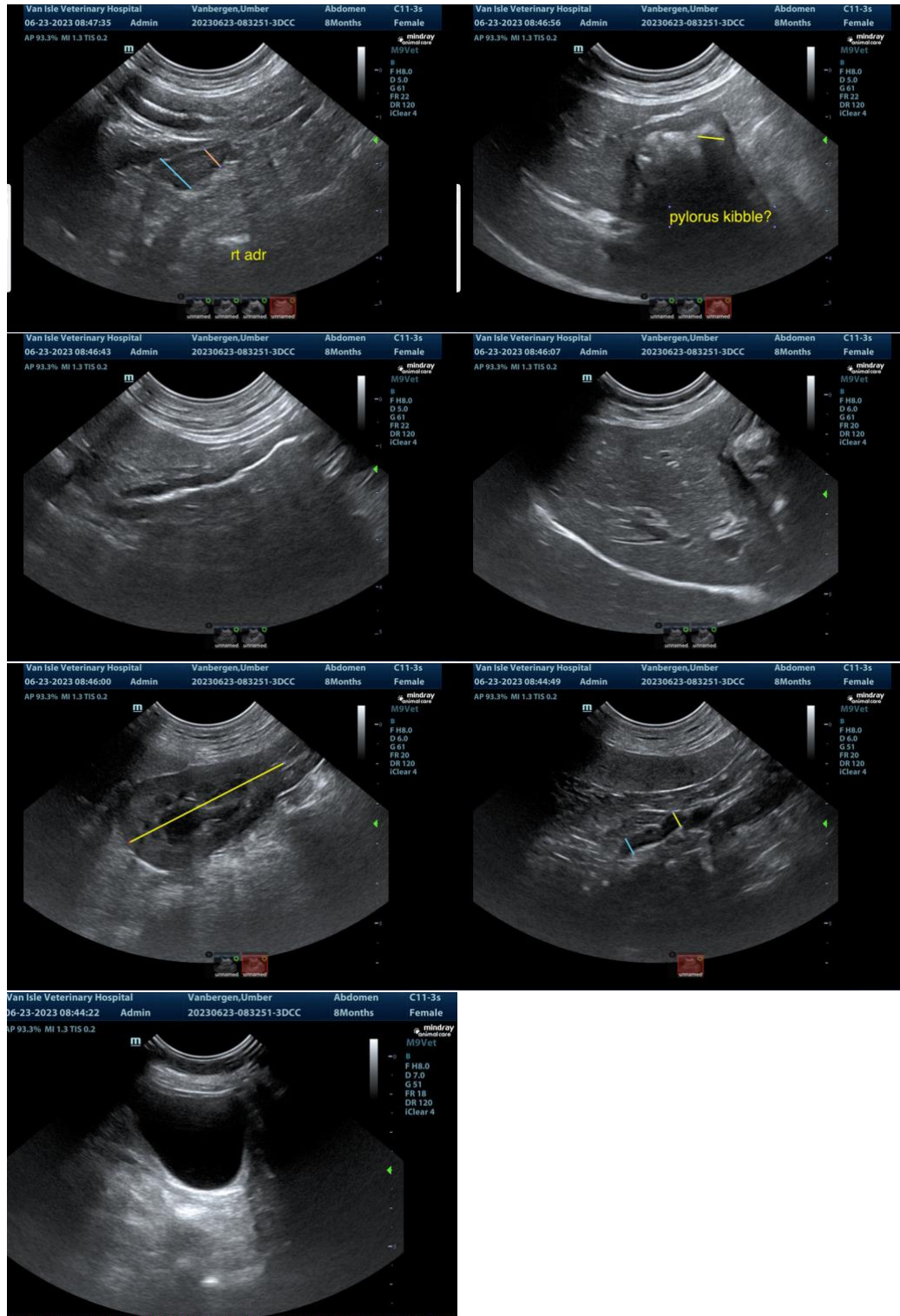
Dr. Judy McFarlen

INVOICE

23020

DATE

6/23/23



The information and recommendations provided are based on the images presented by the referring veterinarian/sonographer. No evaluation can be communicated regarding pathology that was not visible in the image/video clips provided.



PATIENT

Umber Vanbergen

SPECIES

Canine

BREED

Shiba Inu

SEX

Intact Female

AGE

8 Months

WEIGHT

8.5

INTERPRETED BY

Eric Lindquist, DMV

DABVP, Cert. IVUSS

**IMAGING
PERFORMED BY**

Dr. Judy McFarlen

HOSPITAL NAME

Van Isle VH

REFERRING VET

Dr. Judy McFarlen

INVOICE

23020

DATE

6/23/23

Thank you for this referral. If the clinical or image interpretation does not parallel your findings or if I can be of any further assistance please contact me.

Eric Lindquist, DMV, DABVP, Cert. IVUSS, CEO of SonoPath.com

info@SonoPath.com