



PATIENT

Little One Simon
Worodec

SPECIES

Feline

BREED

Domestic Shorthair

SEX

Spayed female

AGE

14 years

WEIGHT

2.74 lbs

INTERPRETED BY

Eric Lindquist, DMV
DABVP, Cert. IVUSS

IMAGING PERFORMED BY

Danielle Jaspar RVT

HOSPITAL NAME

Orchard VC

REFERRING VET

Dr. Antonopoulos

INVOICE

47924

DATE

6/22/23

PRESENTING CLINICAL SIGNS

History: referral US to our clinic. Chronic intermittent diarrhea for 1 year duration. Chem overall WNL, Originally responsive to prednisolone and novel protein diet in June 2022. Owner restarted pred in Feb 2023 with partial response.

ULTRASONOGRAPHIC EXAMINATION OF THE ABDOMEN

Urinary System

The **urinary bladder**, trigone, and pelvic urethra presented normal thicknesses and normal tone. The ureters were not visible which is normal. No uroliths or sediment were visualized and anechoic urine was present. No evidence of inflammatory or neoplastic changes was noted. Ureteral papillae were normal.

The **kidneys** revealed largely normal size and structure, corticomedullary definition and ratio (cortex 1/3 of medulla) were essentially maintained with some age-related loss of curvilinear patterns regarding the capsule and C/M junction. The cortices presented largely uniform texture with some increased echogenicity expected for his age patient. Medullary structure differed distinctly from that of the cortex and no evidence of pelvic dilation was present. The left kidney measured 3.9 cm with pinpoint mineralization noted.

Adrenal Glands

Both **adrenal glands** were visualized and recognized as having normal shape, size, position and echogenicity for this breed. The phrenic vasculature, glandular echogenicity and detail were unremarkable. Capsule, cortex, and medullary definition were normal for this age patient.

Spleen

The **spleen** was mildly enlarged with uniform, but subtly micronodular parenchyma, and undulating capsular contour. This is consistent with reactive spleen owing to immune stimulus or early infiltrative disease such as mast cell disease or lymphoma. 25-gauge FNA would be ideal if weight loss is an issue to differentiate early round cell neoplasia versus splenitis or reactive spleen all of which can present in this manner. The spleen measured 1.01 cm.

Liver

The **liver** images submitted revealed subjectively normal liver size, contour, and structure. Parenchymal echogenicity was naturally coarse and hypoechoic to the spleen. Vascular and biliary tracts were of normal volume with no evidence of congestion. The gallbladder presented acceptably thin walls with primarily anechoic content. The cystic and common bile ducts were normal. No pathological hepatic lymphadenopathy was evident. No overt structural evidence of inflammatory, infiltrative or regenerative pathology was evident.



PATIENT

Little One Simon
Worodec

SPECIES

Feline

BREED

Domestic Shorthair

SEX

Spayed female

AGE

14 years

WEIGHT

2.74 lbs

INTERPRETED BY

Eric Lindquist, DMV
DABVP, Cert. IVUSS

IMAGING PERFORMED BY

Danielle Jaspar RVT

HOSPITAL NAME

Orchard VC

REFERRING VET

Dr. Antonopoulos

INVOICE

47924

DATE

6/22/23

Gastrointestinal

Examination of the **gastrointestinal tract** revealed a stomach free of stasis, of normal wall thickness, acceptable curvilinear mural detail, and peristaltic activity. Diffuse intestinal thickening was noted, there was no overt neoplastic criteria. There was some reactive mesentery associated with the small intestine. The mesenteric lymph nodes were reactive and measured 1.5 x 0.5 cm.

Pancreas

The base and limbs of the **pancreas** were observed to be largely isoechoic to surrounding omental fat. Some parenchymal remodeling, however, with mild deviation from curvilinear normalcy was observed. Pancreatic duct and capsular irregularities were present consistent with age related changes. If pain upon imaging (+ Murphy sign) was present or if the patient is focally painful in subxiphoid palpation then low-grade smoldering chronic pancreatitis should be suspected.

Free Abdomen

A slight amount of free fluid was noted.

ULTRASONOGRAPHIC FINDINGS

Diffuse intestinal thickening with reactive mesenteric lymphadenopathy, no overt neoplastic criteria.

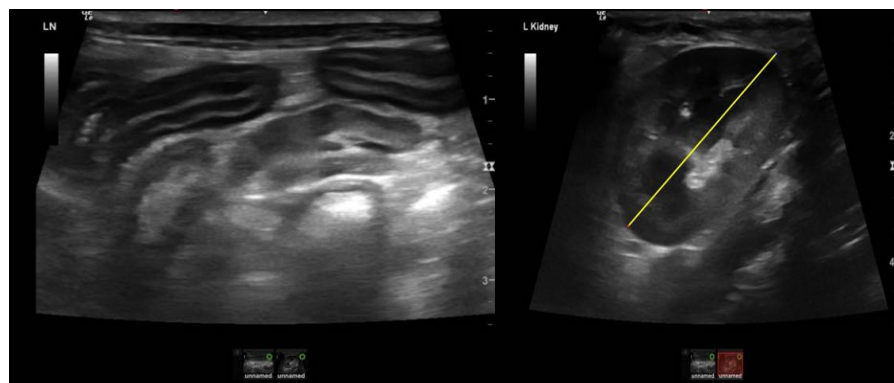
Prominent spleen.

Chronic pancreatitis changes.

Trace amount of free fluid notes likely owing to lymphatic congestion

INTERPRETATION OF THE FINDINGS & FURTHER RECOMMENDATIONS

Full thickness intestinal biopsies would be ideal in this patient. Ultrasound-guided FNA of the accessible mesenteric lymph nodes and liver can be considered with cytology and culture. Slight free fluid, concerning for potential emerging neoplasia. There is a minor potential for dry form FIP in this patient versus emerging round cell neoplasia. The prognosis is guarded.





PATIENT

Little One Simon Worodec

SPECIES

Feline

BREED

Domestic Shorthair

SEX

Spayed female

AGE

14 years

WEIGHT

2.74 lbs

INTERPRETED BY

Eric Lindquist, DMV
DABVP, Cert. IVUSS

IMAGING PERFORMED BY

Danielle Jaspar RVT

HOSPITAL NAME

Orchard VC

REFERRING VET

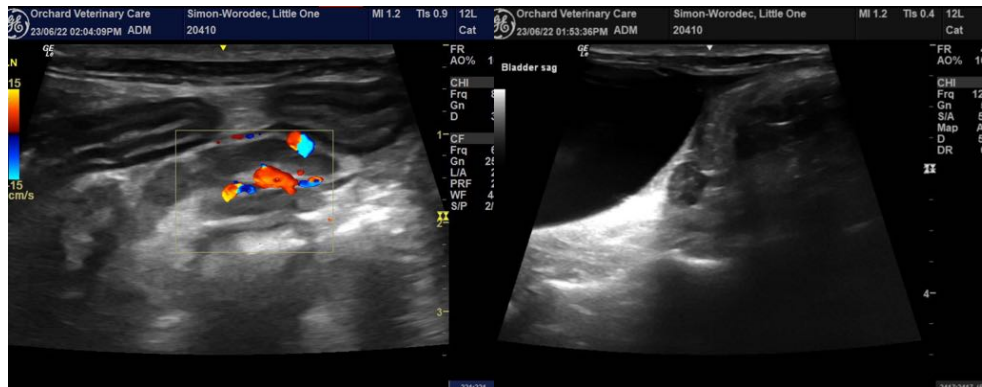
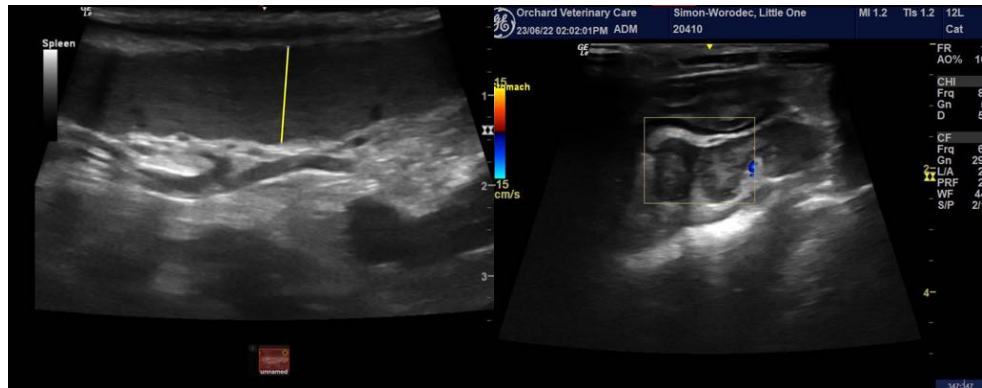
Dr. Antonopoulos

INVOICE

47924

DATE

6/22/23



The information and recommendations provided are based on the images presented by the referring veterinarian/sonographer. No evaluation can be communicated regarding pathology that was not visible in the image/video clips provided.

Thank you for this referral. If the clinical or image interpretation does not parallel your findings or if I can be of any further assistance please contact me.

Eric Lindquist, DMV, DABVP, Cert. IVUSS, CEO of SonoPath.com
info@SonoPath.com