



PATIENT PRESENTING CLINICAL SIGNS

Bella Benecki History: Grade 3/6 murmur. Previous echo 9/18/2020
 Abnormal PE/Chem/CBC/UA Results: BP 140/119(121), 150/81(87), 157/84(109)

SPECIES ULTRASONOGRAPHIC EXAMINATION OF THE HEART

Canine

BREED

Shih Tzu

SEX

Spayed Female

AGE

10 years

WEIGHT

10 lbs

INTERPRETED BY

Eric Lindquist, DMV
 DABVP, Cert. IVUSS

IMAGING PERFORMED BY

JK

HOSPITAL NAME

Hamburg VC

REFERRING VET

Dr. Martens

INVOICE

31180

DATE

6/22/22

The **left atrial** size was at the upper limits of normal in this patient. Chamber volumes and echogenicity were normal. The cranial and caudal **mitral** valve leaflets presented vegetative thickening consistent with endocardiosis. Prolapse of the anterior mitral valve leaflet was noted. Doppler indicated measurable insufficiency. The **left ventricle** presented thicknesses with linear contour and was not dilated nor restricted. The **myocardium** presented normal echogenicity without subjective evidence of significant fibrotic or ischemic disease. **Contractility** of the ventricular walls was adequate and in normal range for this patient evidenced by the fractional shortening measurement and subjective evaluation of the different regions of the myocardium. The **left ventricular outflow** tract demonstrated normal laminar flow and subjective structural integrity. The **right atrium** and auricle revealed normal size, structure and content. No evidence of masses was noted or chamber overload. **Tricuspid** valvular assessment demonstrated adequate linear morphology. The **right ventricle** was of normal size (1/3 diameter of LV), chordae structure, myocardial echogenicity and thickness. **Pulmonic** tract assessment revealed normal valve structure, laminar flow, and diameter (approx. 1:1 pa/ao ratio). No visible **pericardial** or free pleura fluid was noted. No echographically detectable evidence of infiltrative disease was visible. The cranial **mediastinum** and **pericardial** regions were free of masses in the visible window.

CANINE CARDIAC PARAMETERS	MR VMAX (m/s)	TR VMAX (m/s)	LA/AO (Boon method)	LA/AO (Heart Base; Swe)	FS (%)	EF (%)	EPSS (cm)
NORMAL PARAMETER	4.5-5.5	<2.7	1.3	<1.3	28-40	40-100	<0.6
PATIENT			1.23	1.5	33	63	NM
CANINE CARDIAC PARAMETERS	HR (BPM)	AV VMAX (m/s)	PV MAX (m/s)	BODY WEIGHT	LA (2D short axis Base view) (cm)	LVIDd (Avg; 2D and m-mode short axis) (cm)	LVIDs (Avg; 2D and m-mode short axis) (cm)
NORMAL PARAMETER	50-100	0.7-1.7	0.7-1.6				
PATIENT	114	1.3	0.7	10 lbs	3.0	2.92	

ULTRASONOGRAPHIC FINDINGS

Early stage B2 valvular disease.

INTERPRETATION OF THE FINDINGS & FURTHER RECOMMENDATIONS

I recommend initiating Pimobendan at 0.3 mg/kg b.i.d.



PATIENT

Bella Benecki

The heart has some volume overload and is working to compensate for the valvular insufficiency. Target respiratory rate is < 20 resp/minute after therapy. After initiating therapy, I recommend recheck on the clinical exam, BUN, Creatinine, USG, Chest radiographs & Blood pressure in 5-7 days. Recheck echo in 1 month. Earlier if clinical decompensation is occurring. I do not recommend anesthesia at this time until stabilization has occurred on the recommended medications. Repeat preanesthetic echo is ideal if anesthesia is eventually necessary

SPECIES

Canine

BREED

Shih Tzu

SEX

Spayed Female

AGE

10 years

WEIGHT

10 lbs

INTERPRETED BY

Eric Lindquist, DMV
DABVP, Cert. IVUS

IMAGING PERFORMED BY

JK

HOSPITAL NAME

Hamburg VC

REFERRING VET

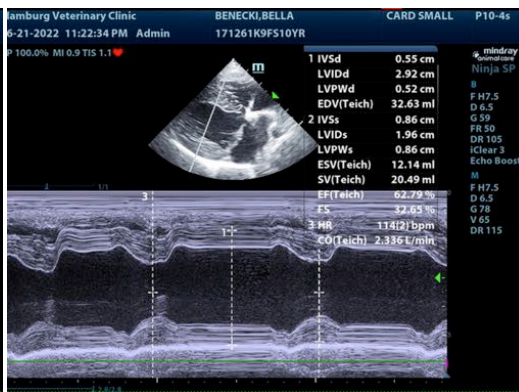
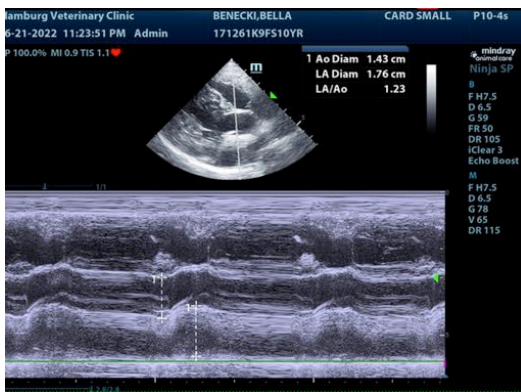
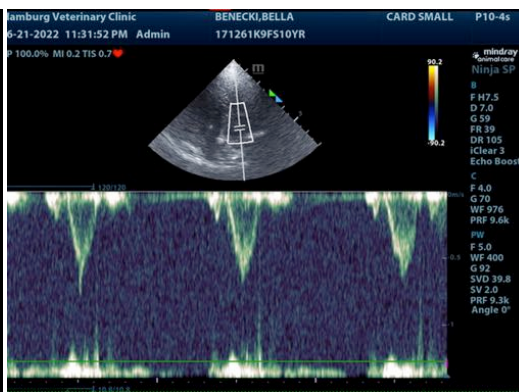
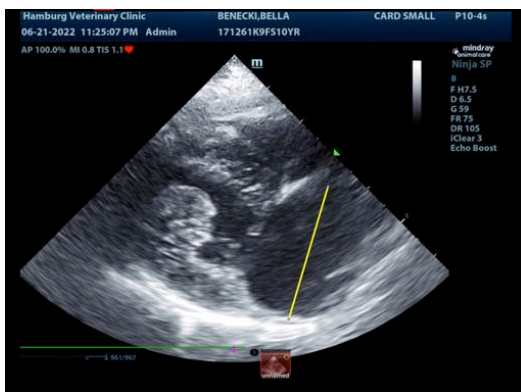
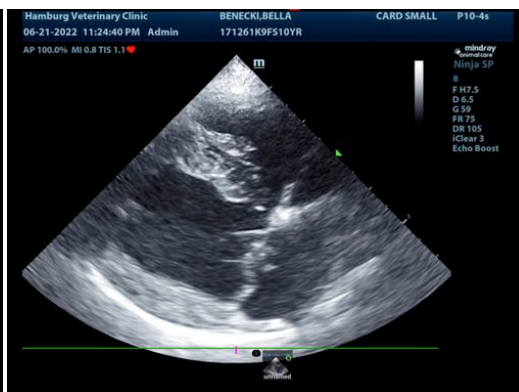
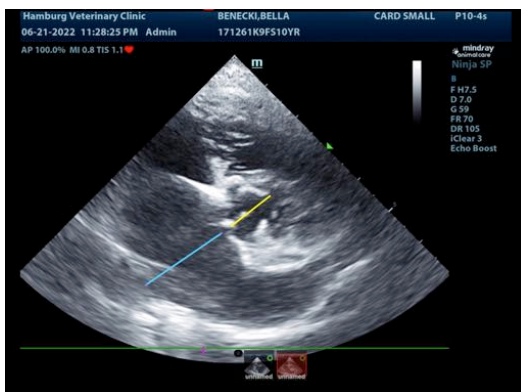
Dr. Martens

INVOICE

31180

DATE

6/22/22





PATIENT

Bella Benecki

SPECIES

Canine

BREED

Shih Tzu

SEX

Spayed Female

AGE

10 years

WEIGHT

10 lbs

INTERPRETED BY

Eric Lindquist, DMV
DABVP, Cert. IVUSS

IMAGING PERFORMED BY

JK

HOSPITAL NAME

Hamburg VC

REFERRING VET

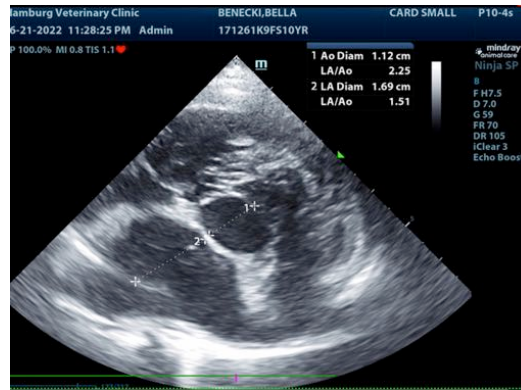
Dr. Martens

INVOICE

31180

DATE

6/22/22



The information and recommendations provided are based on the images presented by the referring veterinarian/sonographer. No evaluation can be communicated regarding pathology that was not visible in the image/video clips provided.

Thank you for this referral. If the clinical or image interpretation does not parallel your findings or if I can be of any further assistance please contact me.

Eric Lindquist, DMV, DABVP, Cert. IVUSS, CEO of SonoPath.com
info@SonoPath.com