



PATIENT

Tucker Eldridge

SPECIES

Canine

BREED

Border Collie X

SEX

Intact Male

AGE

24 Weeks

WEIGHT

35.1 Pounds

INTERPRETED BY

Eric Lindquist, DMV

DABVP, Cert. IVUSS

IMAGING PERFORMED BY

Shari Reffi, CVT

HOSPITAL NAME

Newton Vet Hospital

REFERRING VET

Dr. Barron

INVOICE

43305

DATE

6/21/23

PRESENTING CLINICAL SIGNS

V+ , not eating, lethargic. R/O FB. Cerenia given 5pm last night.

ULTRASONOGRAPHIC EXAMINATION OF THE ABDOMEN

Urinary System

The **urinary bladder**, trigone, and pelvic urethra presented normal thicknesses and normal tone. The ureters were not visible which is normal. No uroliths or sediment were visualized and anechoic urine was present. No evidence of inflammatory or neoplastic changes were noted. Ureteral papillae were normal. The prostate was uniform at 1.1 cm.

The **kidneys** revealed normal size and structure, corticomedullary definition and ratio for this age. The cortices presented largely uniform texture with normal echogenic relationship to liver and spleen. Medullary structure differed distinctly from the cortex and no evidence of pelvic dilation was present. The capsules were acceptably uniform without significant irregularities. The right kidney measured 5.5 cm. The left kidney measured 5.41 cm.

Adrenal Glands

Both **adrenal glands** were visualized and recognized as having normal shape, size, position and echogenicity for this breed. The phrenic vasculature, glandular echogenicity and detail were unremarkable. Capsule, cortex, and medullary definition were normal for this age patient. The right adrenal gland measured 2.09 cm x 0.85 cm at the cranial pole and 0.48 cm at the caudal pole. The left adrenal gland measured 1.78 cm x 0.37 cm at the caudal pole and 0.37 cm at the cranial pole.

Spleen

The **spleen** presented a smooth homogeneous parenchyma hyperechoic to liver and renal cortical parenchyma. The capsule was smooth without noticeable expansion or deviation from within the spleen or adjacent pathology. The splenic vasculature demonstrated normal volume without signs of congestion or thrombosis. No sonographic evidence of acute or chronic inflammatory, neoplastic, or infarctual changes were noted.

Liver

The **liver** images submitted revealed subjectively normal liver size, contour, and structure. Parenchymal echogenicity was naturally coarse and hypoechoic to the spleen. Vascular and biliary tracts were of normal volume with no evidence of congestion. The gallbladder presented acceptably thin walls with primarily anechoic content. The cystic and common bile ducts were normal. No pathological hepatic lymphadenopathy was evident. No overt structural evidence of inflammatory, infiltrative or regenerative pathology was evident.

Gastrointestinal

The **stomach** itself was structurally unremarkable. Jejunum revealed a 2.28 cm shadowing foreign body. Regional lymph nodes were mildly enlarged, up to 1.6 cm, likely juvenile reactive noted. Dilated small intestine noted prior to the foreign body obstruction. Upper gastrointestinal chyme and stasis noted prior to the obstruction, followed by empty small intestine. Some reactive mesentery noted around the obstructed bowel.



PATIENT

Pancreas

Tucker Eldridge

The base and limbs of the **pancreas** were observed to be largely isoechoic to surrounding omental fat. Pancreatic duct and capsular contour were acceptably normal and parenchyma respected normal curvilinear patterns. No overt evidence of active inflammatory or neoplastic disease was noted.

SPECIES

Canine

ULTRASONOGRAPHIC FINDINGS

BREED

- Jejunal foreign body obstruction – 1” hard structure such as a nut or similar.

Border Collie X

INTERPRETATION OF THE FINDINGS & FURTHER RECOMMENDATIONS

Surgical intervention is essential.

SEX

Intact Male

AGE

24 Weeks

WEIGHT

35.1 Pounds

INTERPRETED BY

Eric Lindquist, DMV
DABVP, Cert. IVUSS

IMAGING PERFORMED BY

Shari Reffi, CVT

HOSPITAL NAME

Newton Vet Hospital

REFERRING VET

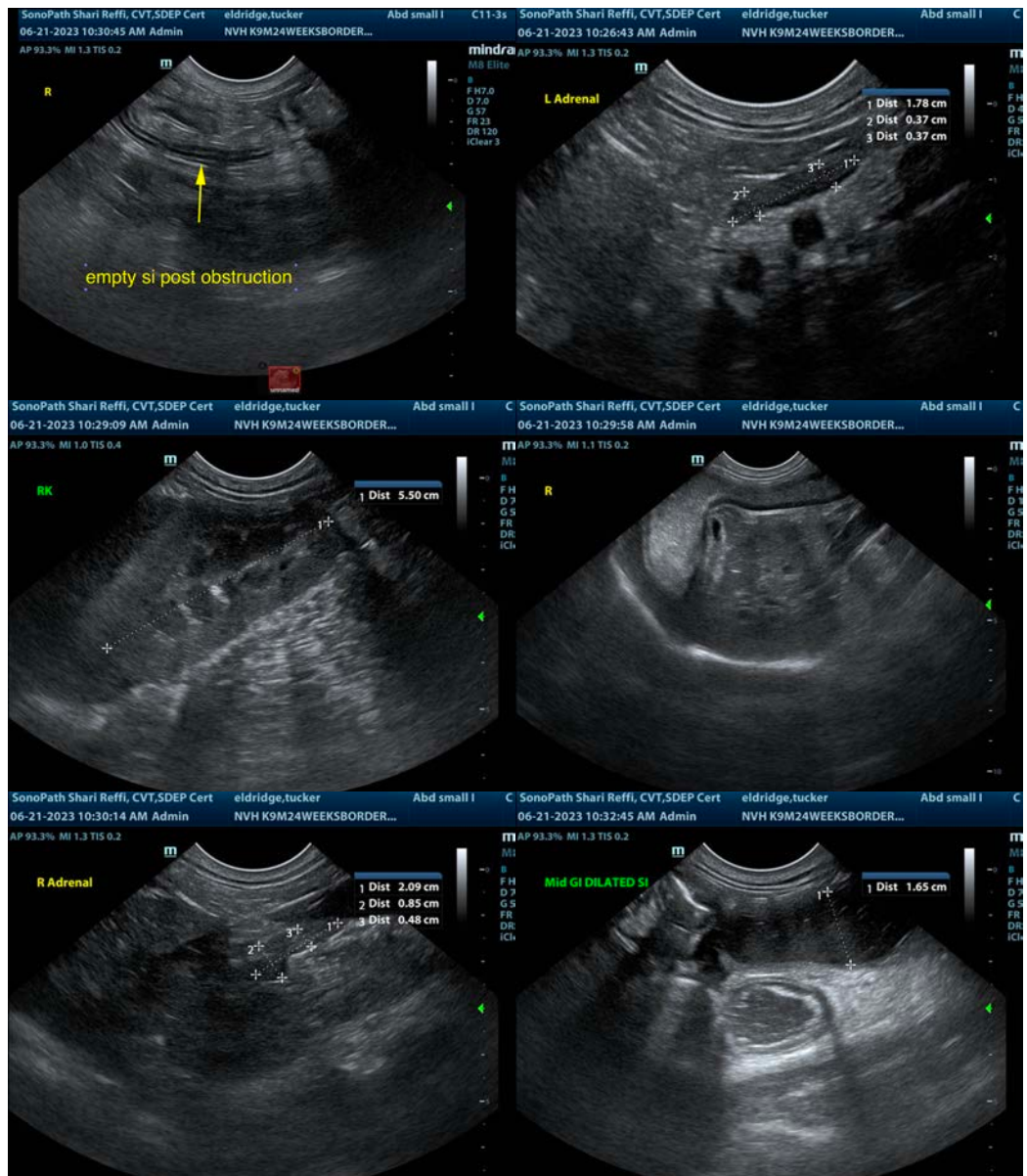
Dr. Barron

INVOICE

43305

DATE

6/21/23





PATIENT

Tucker Eldridge

SPECIES

Canine

BREED

Border Collie X

SEX

Intact Male

AGE

24 Weeks

WEIGHT

35.1 Pounds

INTERPRETED BY

Eric Lindquist, DMV

DABVP, Cert. IVUSS

IMAGING PERFORMED BY

Shari Reffi, CVT

HOSPITAL NAME

Newton Vet Hospital

REFERRING VET

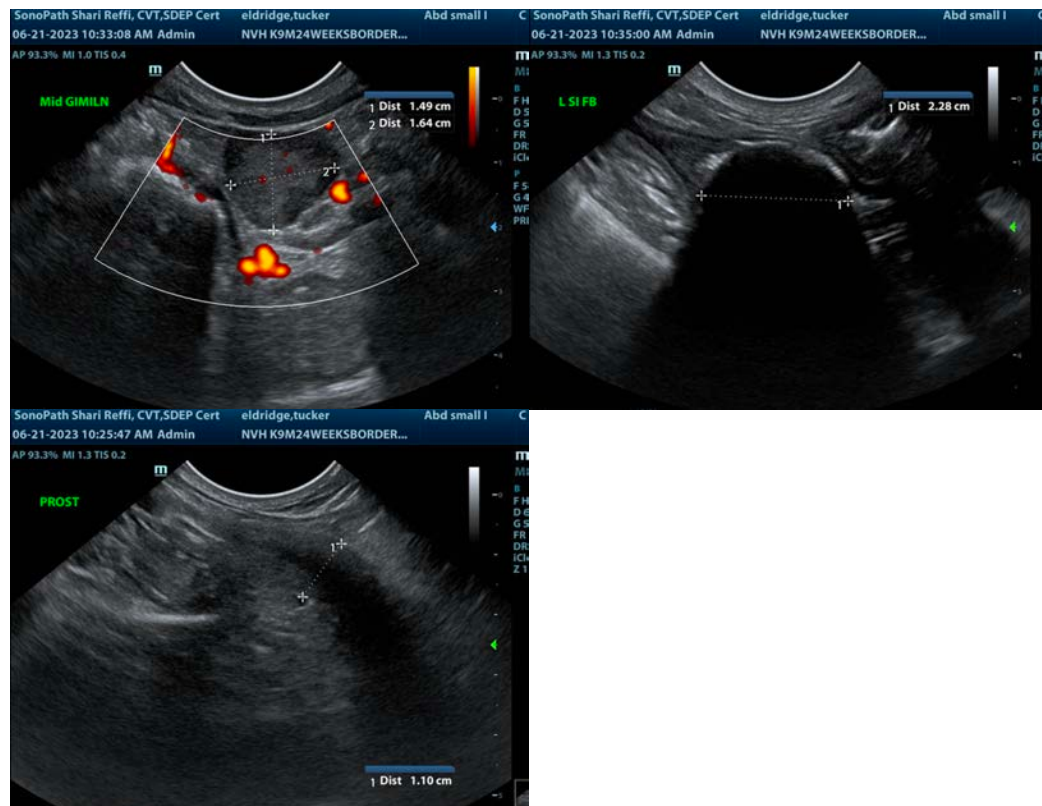
Dr. Barron

INVOICE

43305

DATE

6/21/23



The information and recommendations provided are based on the images presented by the referring veterinarian/sonographer. No evaluation can be communicated regarding pathology that was not visible in the image/video clips provided.

Thank you for this referral. If the clinical or image interpretation does not parallel your findings or if I can be of any further assistance please contact me.

Eric Lindquist, DMV, DABVP, Cert. IVUSS, CEO of SonoPath.com

info@SonoPath.com