



**PATIENT**

Enzo Cocchiari

**SPECIES**

Canine

**BREED**

Cockerpoo

**SEX**

Male

**AGE**

1 year

**WEIGHT**

9.8 kg

**INTERPRETED BY**

Eric Lindquist, DMV  
DABVP, Cert. IVUSS

**IMAGING PERFORMED BY**

Dr. Olcha

**HOSPITAL NAME**

East Meadow VC

**REFERRING VET**

Dr. Olcha

**INVOICE**

31158

**DATE**

6/21/22

**PRESENTING CLINICAL SIGNS**

History: Intermittent vomiting and cough for about 6 months. Patient does have a history of dietary indiscretion. Previous treatments include doxycycline, prednisone, hydrolyzed diet trial, panacur AUS performed today. Repeat CBC/Chem + SpecCPL/ACTH stim pending.

Abnormal PE/Chem/CBC/UA Results: Cortisol of 1.5ug/dL (normal 2-6) last November otherwise unremarkable CBC/Chem/UA/Fecal (file attached) Thoracic x-rays repeated today: Unremarkable

**ULTRASONOGRAPHIC EXAMINATION OF THE ABDOMEN**

**Urinary System**

The **urinary bladder**, trigone, and pelvic urethra presented normal thicknesses and normal tone. The ureters were not visible which is normal. No uroliths or sediment were visualized and anechoic urine was present. No evidence of inflammatory or neoplastic changes was noted. Ureteral papillae were normal.

The prostate was uniform and measured 2.0 cm with no evidence of pathology.

The **kidneys** revealed normal size and structure, corticomedullary definition and ratio for this age. The cortices presented largely uniform texture with normal echogenic relationship to liver and spleen. Medullary structure differed distinctly from the cortex and no evidence of pelvic dilation was present. The capsules were acceptably uniform without significant irregularities. The left kidney measured 5.0 cm. The right kidney measured 5.0 cm.

**Adrenal Glands**

The right adrenal gland was flattened and approximately 0.3 cm. The left adrenal gland measured 0.3 cm.

**Spleen**

The **spleen** presented a smooth homogeneous parenchyma hyperechoic to liver and renal cortical parenchyma. The capsule was smooth without noticeable expansion or deviation from within the spleen or adjacent pathology. The splenic vasculature demonstrated normal volume without signs of congestion or thrombosis. No sonographic evidence of acute or chronic inflammatory, neoplastic, or infarctual changes was noted.

**Liver**

The **liver** images submitted revealed subjectively normal liver size, contour, and structure. Parenchymal echogenicity was naturally coarse and hypoechoic to the spleen. Vascular and biliary tracts were of normal volume with no evidence of congestion. The gallbladder presented acceptably thin walls with primarily anechoic content. The cystic and common bile ducts were normal. No pathological hepatic lymphadenopathy was evident. No overt structural evidence of inflammatory, infiltrative or regenerative pathology was evident.



**PATIENT**

**Gastrointestinal**

Enzo Cocchiari

Examination of the **gastrointestinal tract** revealed a stomach and intestine free of stasis, of normal wall thickness, acceptable curvilinear mural detail, and peristaltic activity. Small and large intestine demonstrated normal luminal chyme and stool consistency respectively. No obstructive or overt infiltrative disease was noted. No associated abnormal lymphatic activity was noted.

**SPECIES**

Canine

**BREED**

Cockerpoo

**Pancreas**

The base and limbs of the **pancreas** were observed to be largely isoechoic to surrounding omental fat. Pancreatic duct and capsular contour were acceptably normal and parenchyma respected normal curvilinear patterns. No overt evidence of active inflammatory or neoplastic disease was noted.

**SEX**

Male

**ULTRASONOGRAPHIC FINDINGS**

Structurally unremarkable abdomen.

**AGE**

1 year

**INTERPRETATION OF THE FINDINGS & FURTHER RECOMMENDATIONS**

**WEIGHT**

9.8 kg

Given the patient's history full ACTH stimulation is warranted to assess for Addison's disease. Structurally the GI tract was unremarkable. Clinical trial of the following may prove effective.

**INTERPRETED BY**

Eric Lindquist, DMV  
DABVP, Cert. IVUSS

**Helicobacter/Gastritis protocol**

A clinical trial of **Zithromax** (Dogs: 5-10 mg/kg p.o. q24h. May increase dosing interval to q48h after 3-5 days of treatment), **Metronidazole** (10-20 mg/kg p.o. b.i.d.), **Sucralfate** (0.5-2 g/dog PO) and **Omeprazole** (1 mg/kg p.o. s.i.d.) over the next 3 weeks along with a **novel-protein or hydrolyzed diet** with slurry feeding b.i.d./t.i.d. over the next 2-4 days and then increase to canned diet bid. Dry food should be avoided over the next 4 weeks. A recheck sonogram to assess GI improvement or progression would be ideal in 4 weeks.

**IMAGING PERFORMED BY**

Dr. Olcha

**HOSPITAL NAME**

East Meadow VC

**REFERRING VET**

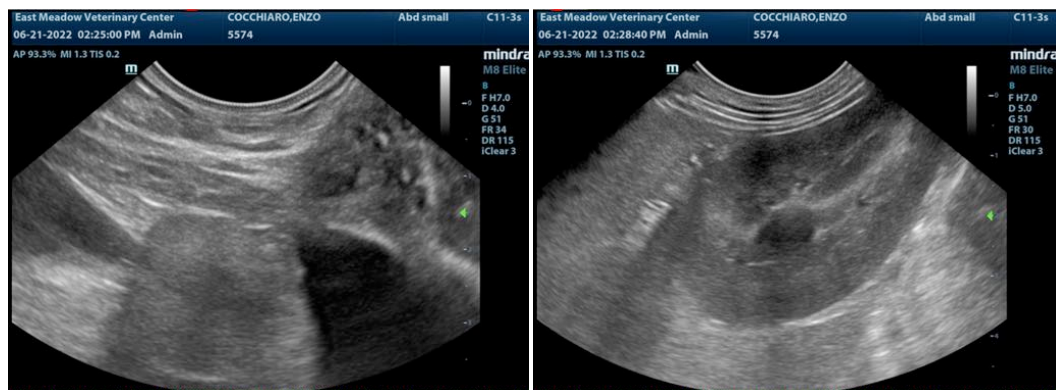
Dr. Olcha

**INVOICE**

31158

**DATE**

6/21/22





**PATIENT**

Enzo Cocchiari

**SPECIES**

Canine

**BREED**

Cockerpoo

**SEX**

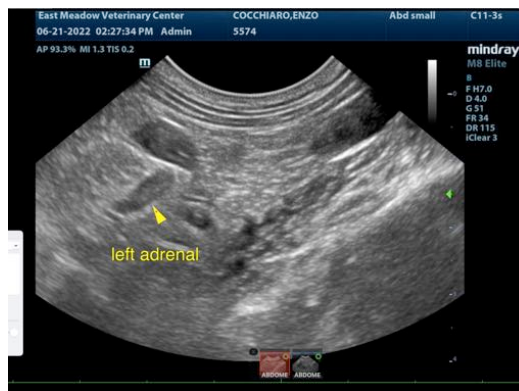
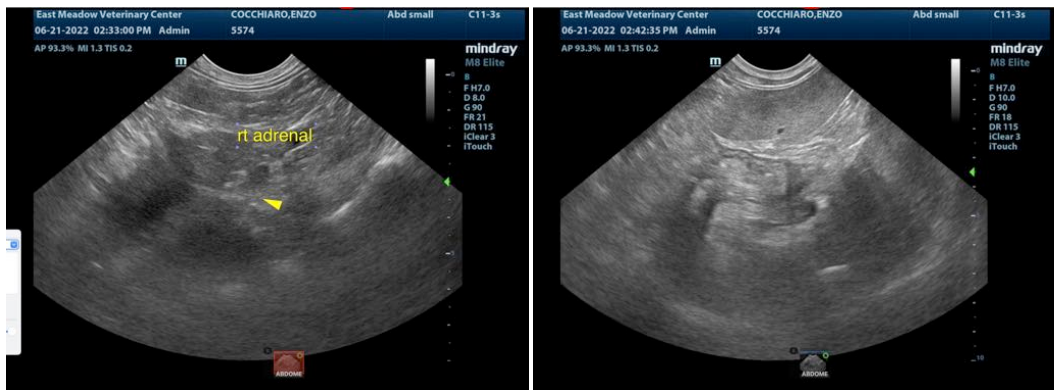
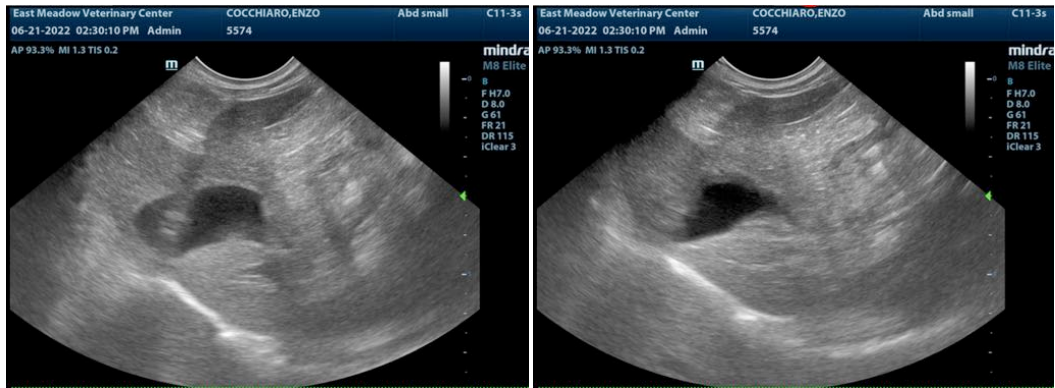
Male

**AGE**

1 year

**WEIGHT**

9.8 kg



**INTERPRETED BY**

Eric Lindquist, DMV  
DABVP, Cert. IVUSS

**IMAGING PERFORMED BY**

Dr. Olcha

**HOSPITAL NAME**

East Meadow VC

**REFERRING VET**

Dr. Olcha

**INVOICE**

31158

**DATE**

6/21/22

The information and recommendations provided are based on the images presented by the referring veterinarian/sonographer. No evaluation can be communicated regarding pathology that was not visible in the image/video clips provided.

Thank you for this referral. If the clinical or image interpretation does not parallel your findings or if I can be of any further assistance please contact me.

Eric Lindquist, DMV, DABVP, Cert. IVUSS, CEO of SonoPath.com



**PATIENT**

info@SonoPath.com

Enzo Cocchiaro

**SPECIES**

Canine

**BREED**

Cockerpoo

**SEX**

Male

**AGE**

1 year

**WEIGHT**

9.8 kg

**INTERPRETED BY**

Eric Lindquist, DMV  
DABVP, Cert. IVUSS

**IMAGING  
PERFORMED BY**

Dr. Olcha

**HOSPITAL NAME**

East Meadow VC

**REFERRING VET**

Dr. Olcha

**INVOICE**

31158

**DATE**

6/21/22