



PATIENT

Baxter DeAngelo

SPECIES

Canine

BREED

Dachshund

SEX

Neutered male

AGE

5 years

WEIGHT

21.2 lbs

INTERPRETED BY

Eric Lindquist, DMV
DABVP, Cert. IVUSS

IMAGING PERFORMED BY

Jessica Green

HOSPITAL NAME

Stanglein VC

REFERRING VET

Dr. DiNello-Schleicher

INVOICE

31146

DATE

6/21/22

PRESENTING CLINICAL SIGNS

History: 8/11/20 Pt had an abdominal explore and resection + anastomosis of ileal mass. Biopsy diagnosed B-cell lymphoma. Chemo (CHOP type protocol) performed 9/25/20 to 3/12/21. 4/12/21 AUS unremarkable other than some prominent omental LN 0.69 cm diameter. 9/21/21 AUS showed mesenteric LN 0.6cm, considered static and not neoplastic, 3/14/22 AUS showed prominent to swollen mildly hypoechoic medial iliac LN adjacent to iliac trifurcation. 1.2cm by 0.76 cm. Pt also had bloody diarrhea and elevated lipase/amylase on BW. Pt has chronically had intermittent diarrhea. Abnormal PE/Chem/CBC/UA Results: last done 3/12/22 elevated lipase/amylase, sl low phosphorus(2.3), otherwise unremarkable. No rads taken. current meds: metronidazole courses when diarrhea flare, not given in the last week,

ULTRASONOGRAPHIC EXAMINATION OF THE ABDOMEN

Urinary System

The **urinary bladder**, trigone, and pelvic urethra presented normal thicknesses and normal tone. The ureters were not visible which is normal. No uroliths or sediment were visualized and anechoic urine was present. No evidence of inflammatory or neoplastic changes was noted. Ureteral papillae were normal.

The **kidneys** revealed normal size and structure, corticomedullary definition and ratio for this age. The cortices presented largely uniform texture with normal echogenic relationship to liver and spleen. Medullary structure differed distinctly from the cortex and no evidence of pelvic dilation was present. The capsules were acceptably uniform without significant irregularities. The right kidney measured 5.07 cm. The left kidney measured 4.97 cm.

Adrenal Glands

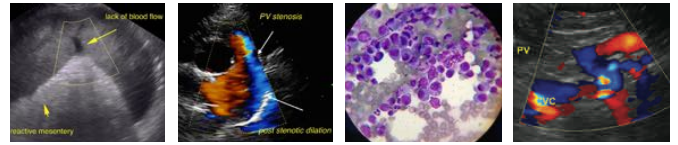
Both **adrenal glands** were visualized and recognized as having normal shape, size, position and echogenicity for this breed. The phrenic vasculature, glandular echogenicity and detail were unremarkable. Capsule, cortex, and medullary definition were normal for this age patient. The right adrenal gland measured 0.3 cm. The left adrenal gland measured 1.79 x 0.36 cm.

Spleen

The **spleen** presented a smooth homogeneous parenchyma hyperechoic to liver and renal cortical parenchyma. The capsule was smooth without noticeable expansion or deviation from within the spleen or adjacent pathology. The splenic vasculature demonstrated normal volume without signs of congestion or thrombosis. No sonographic evidence of acute or chronic inflammatory, neoplastic, or infarctual changes was noted.

Liver

The **liver** images submitted revealed subjectively normal liver size, contour, and structure. Parenchymal echogenicity was naturally coarse and hypoechoic to the spleen. Vascular and biliary tracts were of normal volume with no evidence of congestion. The gallbladder presented acceptably thin walls with primarily anechoic content. The cystic and common bile ducts were normal. No pathological hepatic



PATIENT

lymphadenopathy was evident. No overt structural evidence of inflammatory, infiltrative or regenerative pathology was evident.

Baxter DeAngelo

SPECIES

Gastrointestinal

Canine

Examination of the **gastrointestinal tract** revealed a stomach and intestine free of stasis, of normal wall thickness, acceptable curvilinear mural detail, and peristaltic activity. Small and large intestine demonstrated normal luminal chyme and stool consistency respectively. No obstructive or overt infiltrative disease was noted. No associated abnormal lymphatic activity was noted. There was no return of the prior pathology.

BREED

Dachshund

SEX

Pancreas

Neutered male

The base and limbs of the **pancreas** were observed to be largely isoechoic to surrounding omental fat. Pancreatic duct and capsular contour were acceptably normal and parenchyma respected normal curvilinear patterns. No overt evidence of active inflammatory or neoplastic disease was noted.

AGE

5 years

ULTRASONOGRAPHIC FINDINGS

WEIGHT

Structurally unremarkable abdomen.

21.2 lbs

INTERPRETATION OF THE FINDINGS & FURTHER RECOMMENDATIONS

INTERPRETED BY

There was no primary or metastatic disease noted.

Eric Lindquist, DMV
DABVP, Cert. IVUSS

IMAGING PERFORMED BY

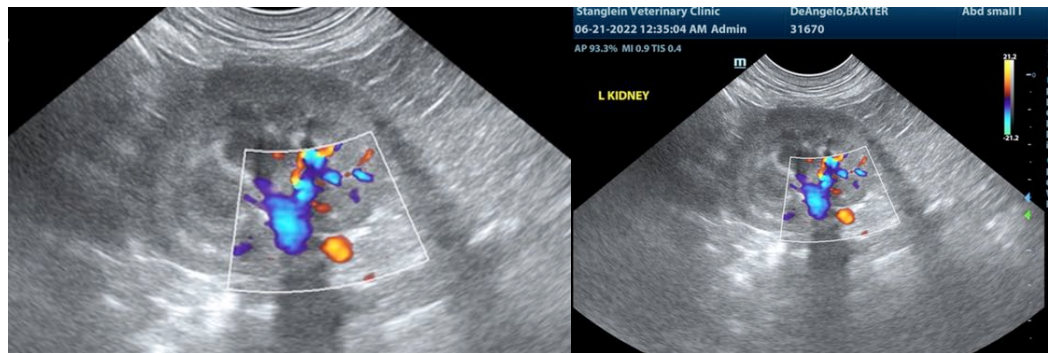
Jessica Green

HOSPITAL NAME

Stanglein VC

REFERRING VET

Dr. DiNello-Schleicher



INVOICE

31146

DATE

6/21/22



PATIENT

Baxter DeAngelo

SPECIES

Canine

BREED

Dachshund

SEX

Neutered male

AGE

5 years

WEIGHT

21.2 lbs

INTERPRETED BY

Eric Lindquist, DMV
DABVP, Cert. IVUSS

IMAGING PERFORMED BY

Jessica Green

HOSPITAL NAME

Stanglein VC

REFERRING VET

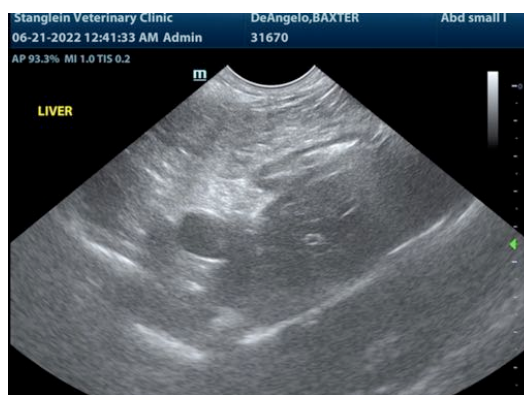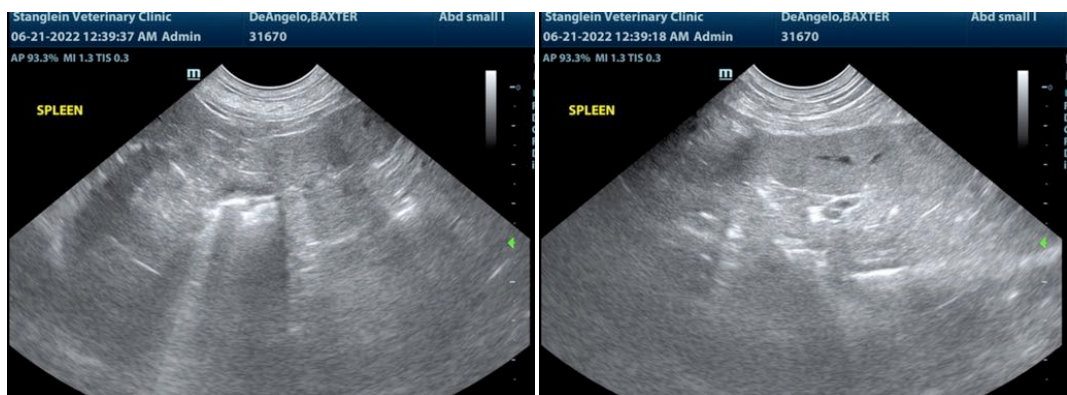
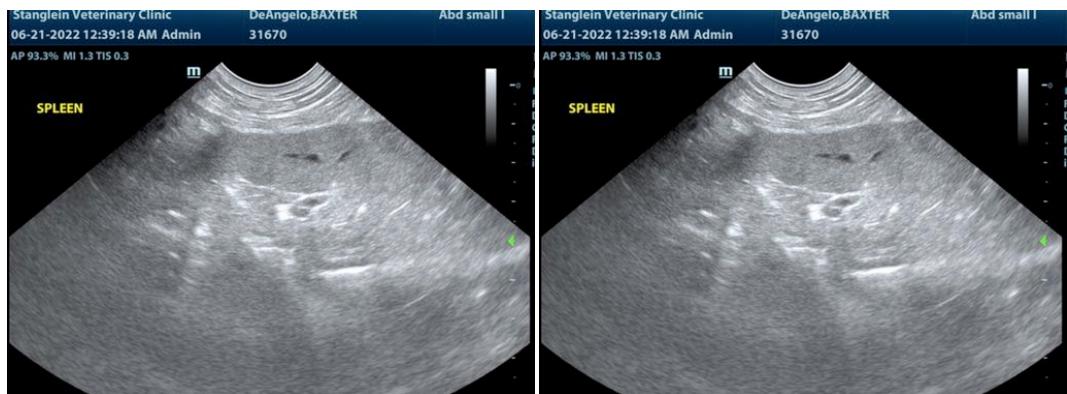
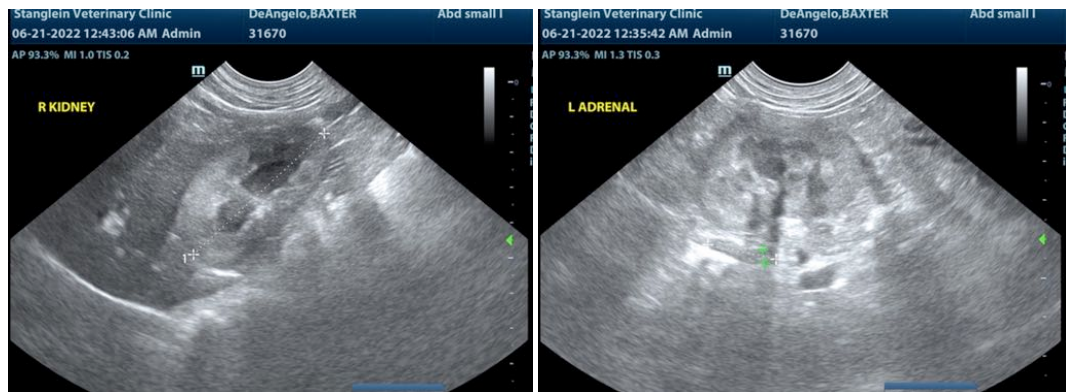
Dr. DiNello-Schleicher

INVOICE

31146

DATE

6/21/22





PATIENT

Baxter DeAngelo

The information and recommendations provided are based on the images presented by the referring veterinarian/sonographer. No evaluation can be communicated regarding pathology that was not visible in the image/video clips provided.

SPECIES

Canine

Thank you for this referral. If the clinical or image interpretation does not parallel your findings or if I can be of any further assistance please contact me.

BREED

Dachshund

Eric Lindquist, DMV, DABVP, Cert. IVUSS, CEO of SonoPath.com
info@SonoPath.com

SEX

Neutered male

AGE

5 years

WEIGHT

21.2 lbs

INTERPRETED BY

Eric Lindquist, DMV
DABVP, Cert. IVUSS

**IMAGING
PERFORMED BY**

Jessica Green

HOSPITAL NAME

Stanglein VC

REFERRING VET

Dr. DiNello-Schleicher

INVOICE

31146

DATE

6/21/22