



PATIENT	RESENTING CLINICAL SIGNS
Archibald Thompson	History: Increased BUN/Crea, Pu/Pd, Urolith Weight loss - 0.5 lbs Evaluate for renal disease, pyelonephritis. Labs + Radiographs attached Rads unremarkable.
SPECIES	ULTRASONOGRAPHIC EXAMINATION OF THE ABDOMEN
Feline	Urinary System
BREED	The urinary bladder , trigone, and pelvic urethra presented normal thicknesses and normal tone. The ureters were not visible which is normal. The urinary bladder presented a trace amount of sand. The sand accumulation measured 2.0 cm. Minor urethral sand was noted. No evidence of inflammatory or neoplastic changes was noted. Ureteral papillae were normal.
Domestic Shorthair	
SEX	The kidneys revealed largely normal size and structure, corticomedullary definition and ratio (cortex 1/3 of medulla) were essentially maintained with some age-related loss of curvilinear patterns regarding the capsule and C/M junction. The cortices presented largely uniform texture with some increased echogenicity expected for this age patient. Medullary structure differed distinctly from that of the cortex and no evidence of pelvic dilation was present. The right kidney measured 4.13 cm. The left kidney measured 3.52 cm with corticomedullary mineralization.
Neutered male	
AGE	
2009	
WEIGHT	Adrenal Glands
12.4 lbs	Both adrenal glands were visualized and recognized as having normal shape, size, position and echogenicity for this breed. The phrenic vasculature, glandular echogenicity and detail were unremarkable. Capsule, cortex, and medullary definition were normal for this age patient. The right adrenal gland measured 0.28 cm.
INTERPRETED BY	Spleen
Eric Lindquist, DMV DABVP, Cert. IVUSS	The spleen presented a smooth homogeneous parenchyma hyperechoic to liver and renal cortical parenchyma. The capsule was smooth without noticeable expansion or deviation from within the spleen or adjacent pathology. The splenic vasculature demonstrated normal volume without signs of congestion or thrombosis. No sonographic evidence of acute or chronic inflammatory, neoplastic, or infarctual changes was noted. The spleen measured 0.85 cm.
IMAGING PERFORMED BY	Liver
Denise Bruno, LVT, RDMS	The liver images from right and left intercostal as well as subcostal views revealed subjectively normal liver size, contour, and structure. Occasional hypoechoic nodule was noted and measured up to 0.4 cm. Some age-related parenchymal remodeling was noted but likely not clinically significant at this time. Vascular and biliary tracts were of normal volume and no evidence of congestion was noted. The gallbladder presented some dependent debris with essentially normal contour. The cystic and common bile ducts were normal. No overt evidence of active inflammatory, infiltrative or regenerative pathology was noted but should be paired with current or past LE elevations regarding any clinical significance to this presentation. The hepatic lymph nodes were unremarkable.
HOSPITAL NAME	
Brooklyn Heights	
REFERRING VET	
Dr. Thomson	
INVOICE	
31169	
DATE	
6/21/22	



PATIENT

Archibald Thompson

SPECIES

Feline

BREED

Domestic Shorthair

SEX

Neutered male

AGE

2009

WEIGHT

12.4 lbs

INTERPRETED BY

Eric Lindquist, DMV
DABVP, Cert. IVUSS

IMAGING PERFORMED BY

Denise Bruno, LVT,
RDMS

HOSPITAL NAME

Brooklyn Heights

REFERRING VET

Dr. Thomson

INVOICE

31169

DATE

6/21/22

Gastrointestinal

Examination of the **gastrointestinal tract** revealed a stomach and intestine free of stasis, of normal wall thickness, acceptable curvilinear mural detail, and peristaltic activity. Small and large intestine demonstrated normal luminal chyme and stool consistency respectively. The epigastric lymph nodes were slightly enlarged and measured 0.68 cm.

Pancreas

The base and limbs of the **pancreas** were observed to be largely isoechoic to surrounding omental fat. Pancreatic duct and capsular contour were acceptably normal and parenchyma respected normal curvilinear patterns. No overt evidence of active inflammatory or neoplastic disease was noted.

ULTRASONOGRAPHIC FINDINGS

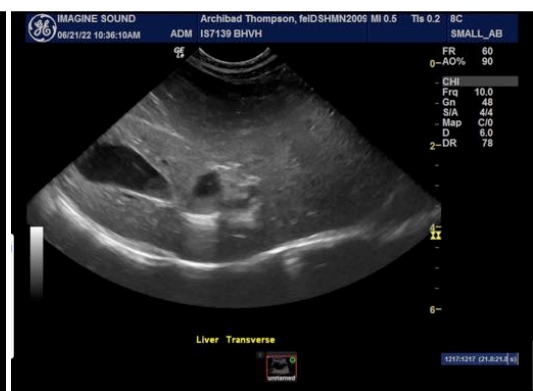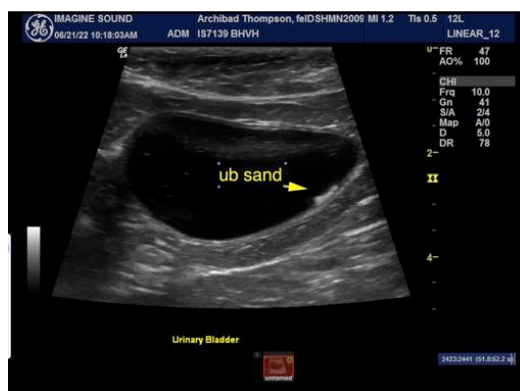Bladder and urethral sand.

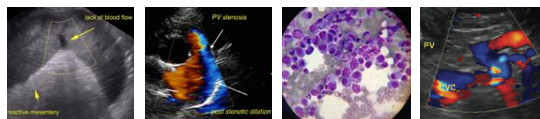
Minor hepatic nodular changes.

Otherwise, geriatric abdomen.

INTERPRETATION OF THE FINDINGS & FURTHER RECOMMENDATIONS

Given the weight loss FNA of the liver hepatic nodules would be indicated. However, these are subtle and minor. The largest nodule measured 0.4-0.5 cm. If liver enzyme elevations occur then FNA is indicated. The patient is likely passing small calculi periodically from the kidneys to the lower urinary tract. Azotemic insult is likely owing to periodic passage as the kidneys appear to have only minor degenerative changes that would be expected for this age patient.





PATIENT

Archibald Thompson

SPECIES

Feline

BREED

Domestic Shorthair

SEX

Neutered male

AGE

2009

WEIGHT

12.4 lbs

INTERPRETED BY

Eric Lindquist, DMV
DABVP, Cert. IVUSS

**IMAGING
PERFORMED BY**

Denise Bruno, LVT,
RDMS

HOSPITAL NAME

Brooklyn Heights

REFERRING VET

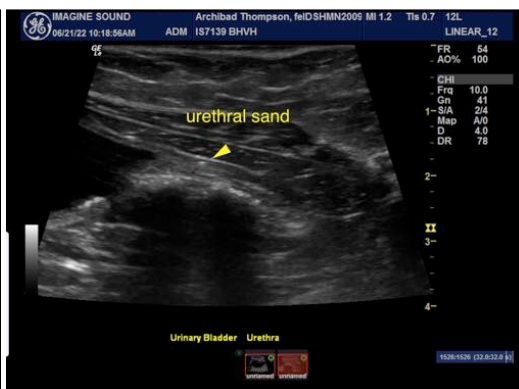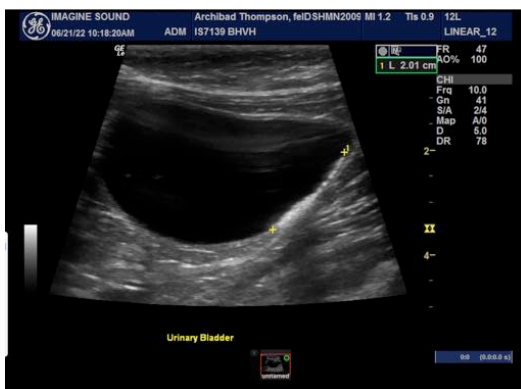
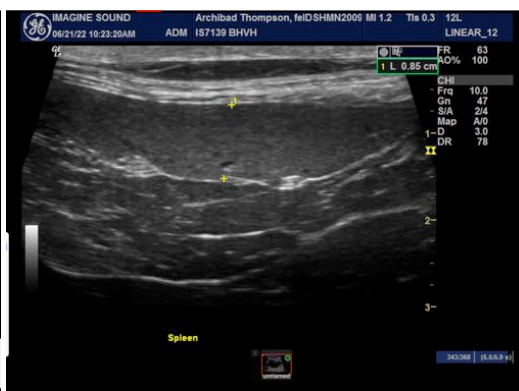
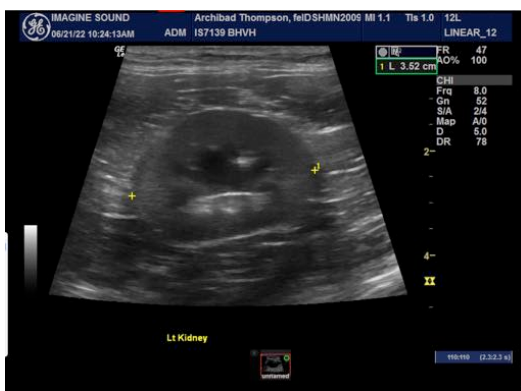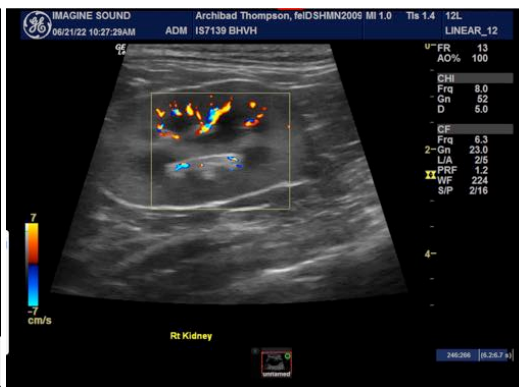
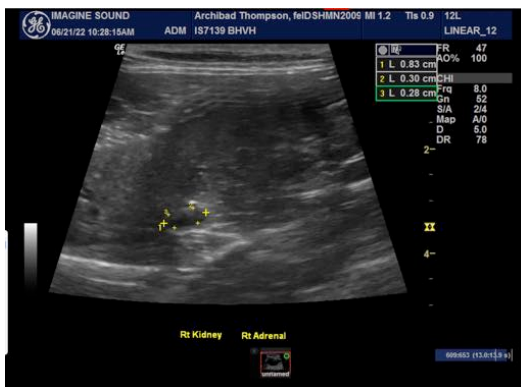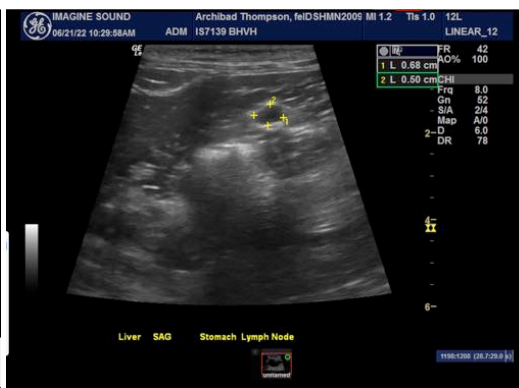
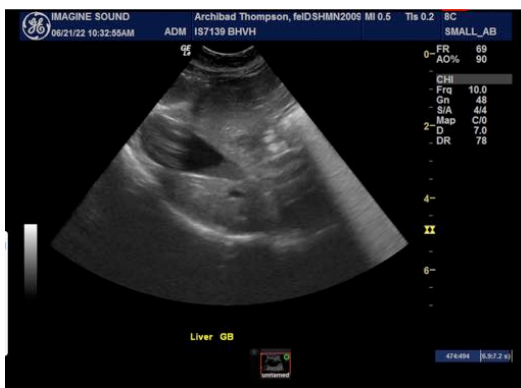Dr. Thomson

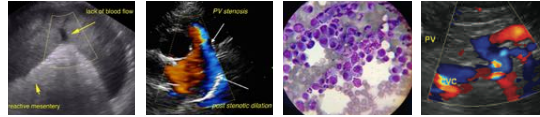
INVOICE

31169

DATE

6/21/22





PATIENT

Archibald Thompson

The information and recommendations provided are based on the images presented by the referring veterinarian/sonographer. No evaluation can be communicated regarding pathology that was not visible in the image/video clips provided.

SPECIES

Feline

Thank you for this referral. If the clinical or image interpretation does not parallel your findings or if I can be of any further assistance please contact me.

BREED

Domestic Shorthair

Eric Lindquist, DMV, DABVP, Cert. IVUSS, CEO of SonoPath.com
Eric.Lindquist@SonoPath.com

SEX

Neutered male

AGE

2009

WEIGHT

12.4 lbs

INTERPRETED BY

Eric Lindquist, DMV
DABVP, Cert. IVUSS

**IMAGING
PERFORMED BY**

Denise Bruno, LVT,
RDMS

HOSPITAL NAME

Brooklyn Heights

REFERRING VET

Dr. Thomson

INVOICE

31169

DATE

6/21/22