



PATIENT

Ginger Miller

SPECIES

Feline

BREED

Persian

SEX

Spayed female

AGE

2 years

WEIGHT

8.66 lbs

INTERPRETED BY

Eric Lindquist, DMV
DABVP, Cert. IVUSS

IMAGING PERFORMED BY

Isabel Plourde

HOSPITAL NAME

TotalBond VH

REFERRING VET

Dr. Epstein

INVOICE

47849

DATE

6/20/23

PRESENTING CLINICAL SIGNS

History: Ginger is a 2 year old female spayed persian cat that has had a history of chronic vomiting, as often as every other day to every 3 days and occasional constipation for the past year. Patient does not typically vomit hairballs according to owner, but usually vomitus is food. Previous radiographs were performed on 2/24/23 and 3/10/23 and they had no major abnormalities seen. Fasting TLI, cobalamin, folate, pancreatic lipase all WNL on 5/23/23. Referring for abdominal ultrasound to evaluate small intestine, other abdominal structures.

Abnormal PE/Chem/CBC/UA Results: Previous radiographs were performed on 2/24/23 and 3/10/23 and they had no major abnormalities seen. Fasting TLI, cobalamin, folate, pancreatic lipase all WNL on 5/23/23. Referring for abdominal ultrasound to evaluate small intestine, other abdominal structures.

ULTRASONOGRAPHIC EXAMINATION OF THE ABDOMEN

Urinary System

The **urinary bladder**, trigone, and pelvic urethra presented normal thicknesses and normal tone. The ureters were not visible which is normal. No uroliths or sediment were visualized and anechoic urine was present. No evidence of inflammatory or neoplastic changes was noted. Ureteral papillae were normal.

The **kidneys** revealed normal size and structure, corticomedullary definition and ratio for this age. The cortices presented largely uniform texture with normal echogenic relationship to liver and spleen. Medullary structure differed distinctly from the cortex and no evidence of pelvic dilation was present. The capsules were acceptably uniform without significant irregularities. Slight pinpoint mineralization was noted in both kidneys. The left kidney measured 3.31 cm.

Adrenal Glands

Both **adrenal glands** were visualized and recognized as having normal shape, size, position and echogenicity for this breed. The phrenic vasculature, glandular echogenicity and detail were unremarkable. Capsule, cortex, and medullary definition were normal for this age patient. The left adrenal gland measured 0.23 cm. The right adrenal gland measured 0.26 cm.

Spleen

The **spleen** presented a smooth homogeneous parenchyma hyperechoic to liver and renal cortical parenchyma. The capsule was smooth without noticeable expansion or deviation from within the spleen or adjacent pathology. The splenic vasculature demonstrated normal volume without signs of congestion or thrombosis. No sonographic evidence of acute or chronic inflammatory, neoplastic, or infarctual changes was noted.

Liver

The **liver** images submitted revealed subjectively normal liver size, contour, and structure. Parenchymal echogenicity was naturally coarse and hypoechoic to the spleen. Vascular and biliary tracts were of



PATIENT

Ginger Miller

normal volume with no evidence of congestion. The gallbladder presented acceptably thin walls with primarily anechoic content. The cystic and common bile ducts were normal. No pathological hepatic lymphadenopathy was evident. No overt structural evidence of inflammatory, infiltrative or regenerative pathology was evident.

SPECIES

Feline

Gastrointestinal

BREED

Persian

Examination of the **gastrointestinal tract** revealed a stomach and intestine free of stasis, of normal wall thickness, acceptable curvilinear mural detail, and peristaltic activity. Minor fluid filled gastric lumen was noted. Small and large intestine demonstrated normal luminal chyme and stool consistency respectively. No obstructive or overt infiltrative disease was noted. No associated abnormal lymphatic activity was noted.

SEX

Spayed female

Pancreas

AGE

2 years

The base and limbs of the **pancreas** were observed to be largely isoechoic to surrounding omental fat. Pancreatic duct and capsular contour were acceptably normal and parenchyma respected normal curvilinear patterns. No overt evidence of active inflammatory or neoplastic disease was noted.

WEIGHT

8.66 lbs

ULTRASONOGRAPHIC FINDINGS

Structurally unremarkable abdomen.

Minor fluid filled gastric lumen.

INTERPRETED BY

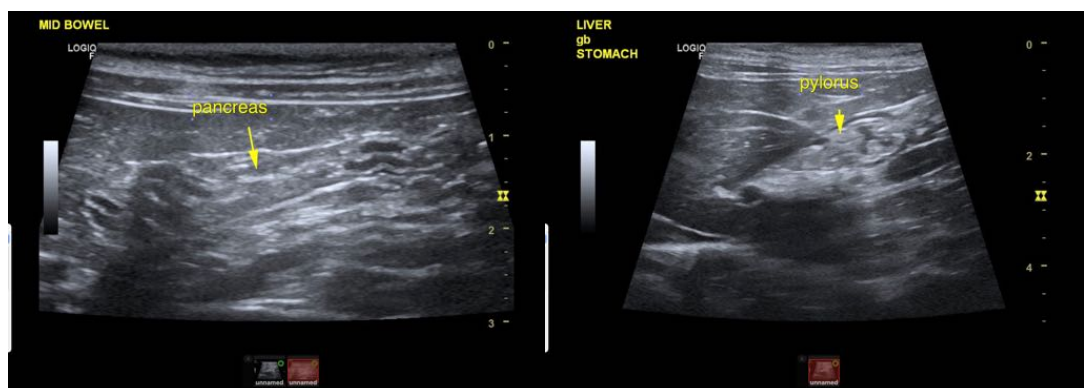
Eric Lindquist, DMV
DABVP, Cert. IVUSS

INTERPRETATION OF THE FINDINGS & FURTHER RECOMMENDATIONS

Dietary indiscretion, food intolerance, structurally significant inflammatory bowel or occult parasitism.

IMAGING PERFORMED BY

Isabel Plourde



HOSPITAL NAME

TotalBond VH

REFERRING VET

Dr. Epstein

INVOICE

47849

DATE

6/20/23



PATIENT

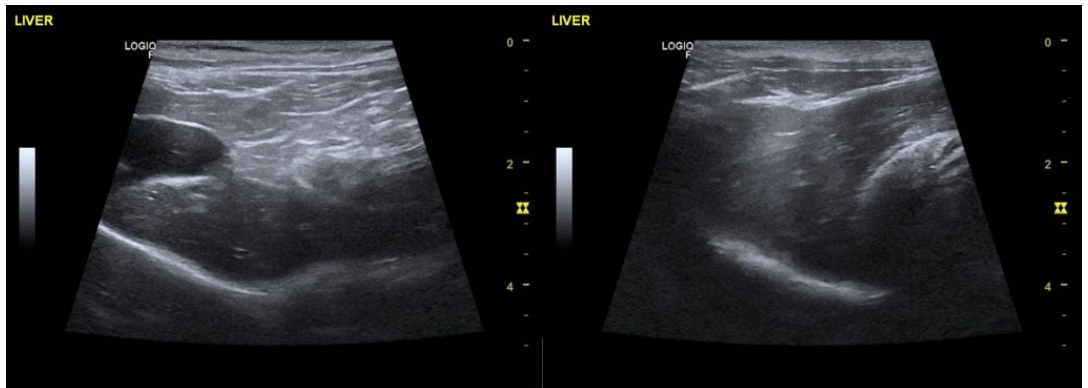
Ginger Miller

SPECIES

Feline

BREED

Persian



SEX

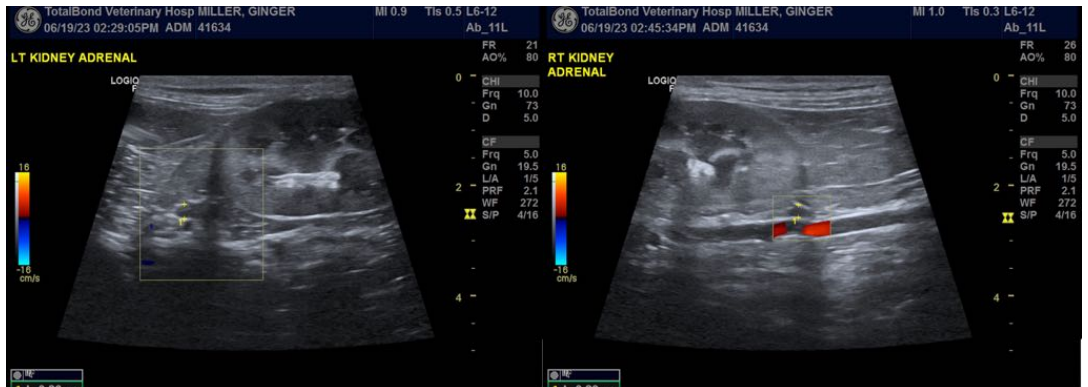
Spayed female

AGE

2 years

WEIGHT

8.66 lbs



INTERPRETED BY

Eric Lindquist, DMV
DABVP, Cert. IVUSS

IMAGING PERFORMED BY

Isabel Plourde

HOSPITAL NAME

TotalBond VH

REFERRING VET

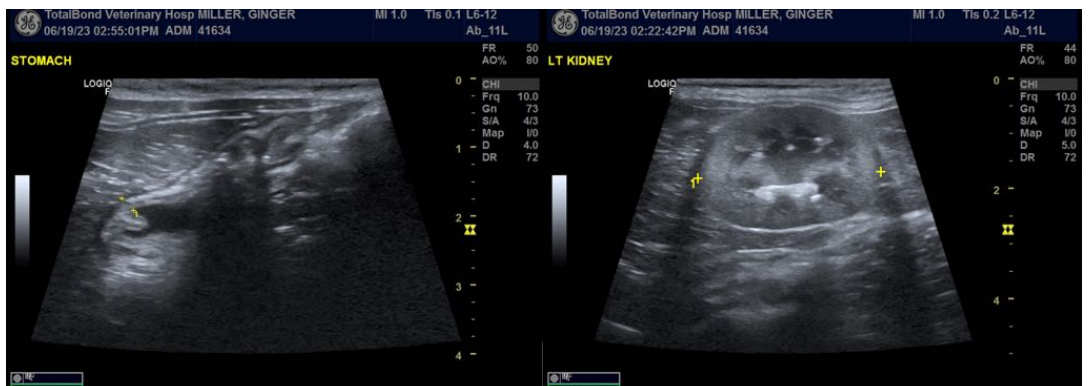
Dr. Epstein

INVOICE

47849

DATE

6/20/23



The information and recommendations provided are based on the images presented by the referring veterinarian/sonographer. No evaluation can be communicated regarding pathology that was not visible in the image/video clips provided.

Thank you for this referral. If the clinical or image interpretation does not parallel your findings or if I can be of any further assistance please contact me.

Eric Lindquist, DMV, DABVP, Cert. IVUSS, CEO of SonoPath.com
info@SonoPath.com