

**DATE**

6/20/22

**PRESENTING CLINICAL SIGNS**

A large firm mass found to the proximal left cervical region at the time of the annual examination. No clinical signs or problems noted by owner or found on remainder of the physical examination.

Current Medications: None listed.

**PATIENT**

Sunny Pancake

Lab Results: Blood profile (CBC/Chem including total T4) - wnl; Lyme positive dating back to 2017, underwent treatment at that time.

Date of Previous IntraPet Ultrasound: No previous.

Sedation: Not required to complete full diagnostic ultrasound.

Stat Report: Not requested.

Imaging Performed By: Rachel Brilhart, RDMS.

**SPECIES**

Canine

**BREED**

Golden Retriever

**SEX**

Spayed Female

**AGE**

12/14/14

**WEIGHT**

101.2 lbs

**INTERPRETED BY**Eric Lindquist, DMV  
DABVP, Cert. IVUSS**HOSPITAL NAME**

Fork VH

**REFERRING VET**

Dr. Doherty

**INVOICE**

31088

**ULTRASONOGRAPHIC EXAMINATION**

The left cervical region revealed a parenchymal mass that measured 6.53 x 3.76 cm. The region of the left thyroid lobe was ill-defined and expansive into regional tissues with enhanced, surrounding, pericapsular fat. The mass envelops the surrounding vascular. Clean resection is unlikely; however, CT evaluation for potential surgical planning would be appropriate.

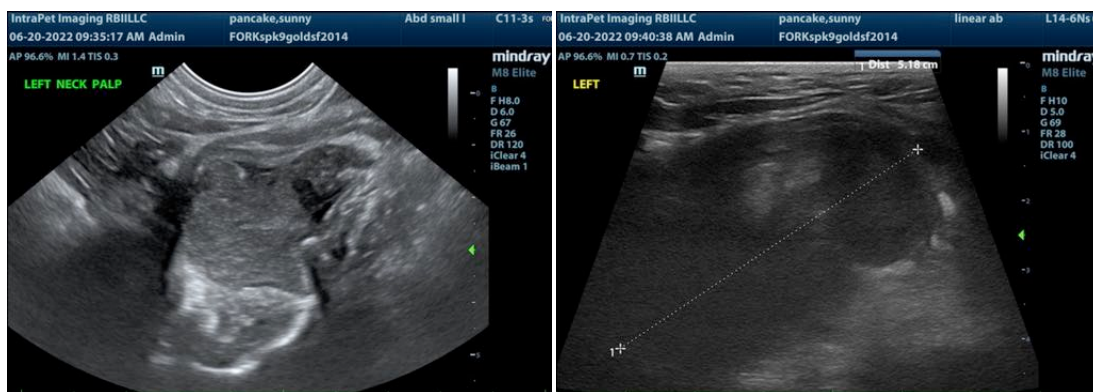
The right thyroid lobe was unremarkable and measured 2.2 x 0.7 cm.

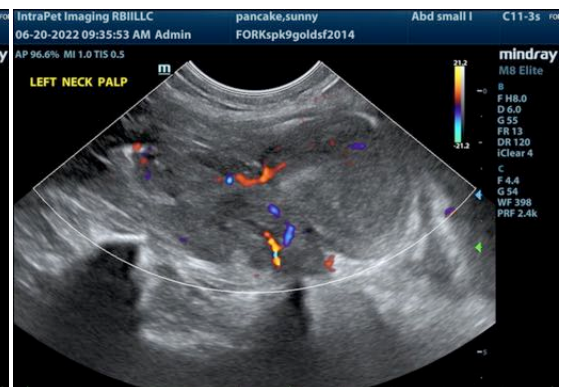
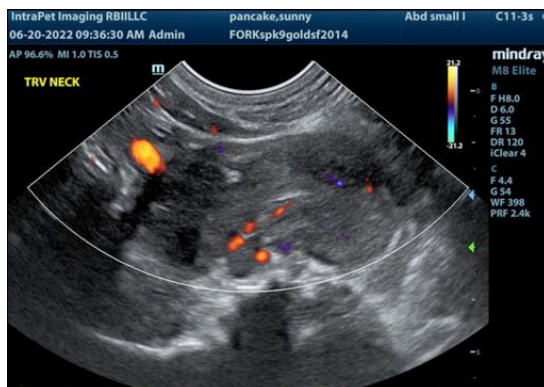
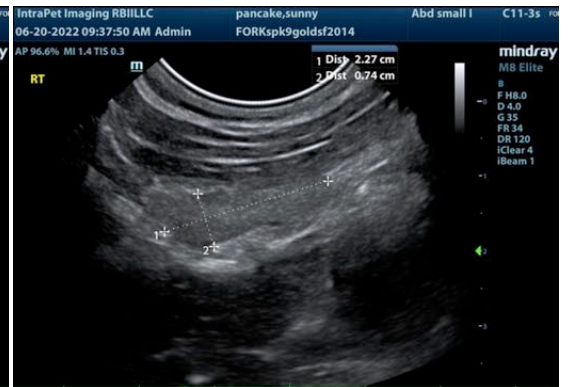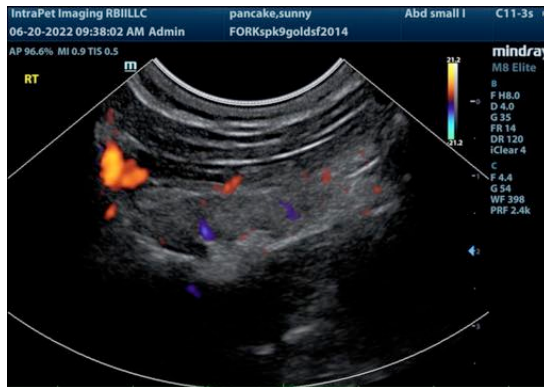
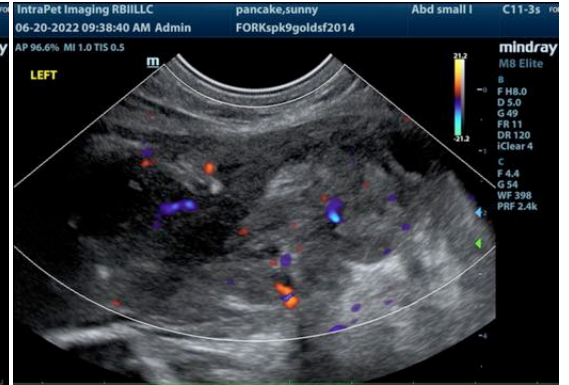
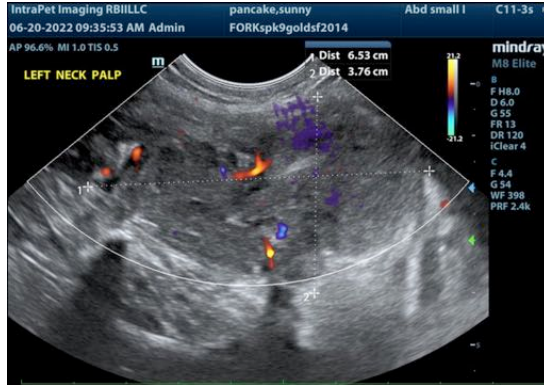
**ULTRASONOGRAPHIC FINDINGS**

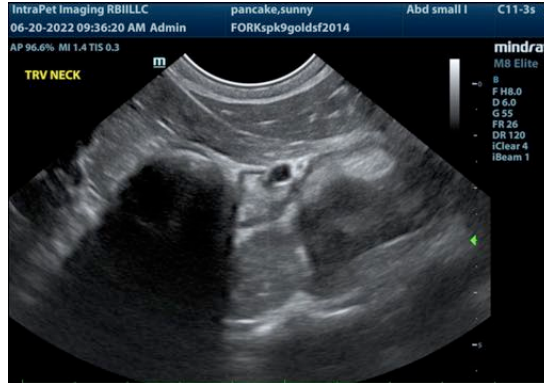Irregular, expansive left thyroid mass with envelopment of regional vasculature, not overtly resectable.

**INTERPRETATION OF THE FINDINGS & FURTHER RECOMMENDATIONS**

CT with contrast is indicated for potential surgical approach. FNA can be considered for further definition. Regional tissue such as salivary glands, trachea and esophagus were unaffected.







The information and recommendations provided are based on the images presented by the referring veterinarian. No evaluation can be communicated regarding pathology that was not visible in the image/video clips provided.

Thank you for this referral. If the clinical or image interpretation does not parallel your findings or if I can be of any further assistance please contact me.

**Eric Lindquist**, DMV, DABVP, Cert. IVUSS, CEO of SonoPath.com  
Eric.Lindquist@SonoPath.com