



PATIENT

Migo Rodgers

SPECIES

Canine

BREED

Labrador Retriever

SEX

MN

AGE

3 yr

WEIGHT

41 kg

INTERPRETED BY

Eric Lindquist, DMV
DABVP, Cert. IVUSS

IMAGING PERFORMED BY

Hayley Biederbeck

HOSPITAL NAME

Lomsnes Veterinary
Hospital

REFERRING VET

Dr. Hayley
Biederbeck

INVOICE

10865ag

DATE

06/20/2022

PRESENTING CLINICAL SIGNS

History: SINGLE ORGAN/RECHECK u/s was done on June 3 and comment about deep liver so repeated today when dog here for spleen fna Clinically dog is doing excellent
Abnormal PE/Chem/CBC/UA Results: AlkP low, all other lab values normal

ULTRASONOGRAPHIC LIMITED EXAMINATION OF THE LIVER/SPLEEN

Spleen

The spleen presented minor heterogeneous parenchyma changes with normal size and contour.

Liver

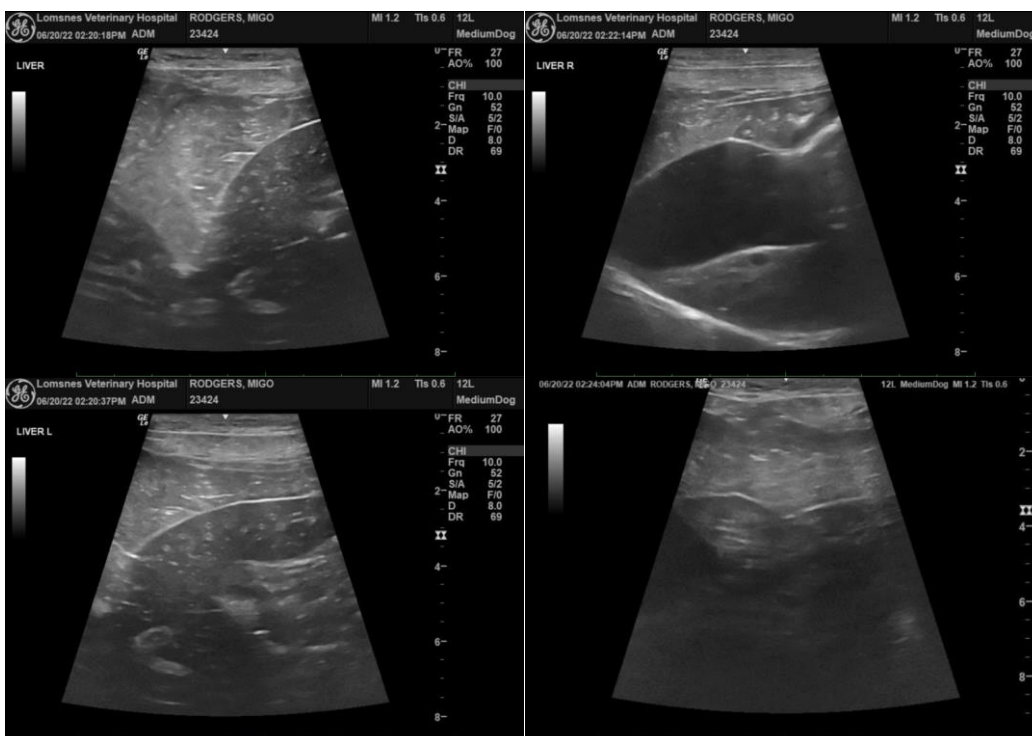
The liver images submitted revealed mild coarse architecture and slightly increased portal markings. Minor uniform swelling was present.

ULTRASONOGRAPHIC FINDINGS

- Mild hepatic remodeling-chronic inflammatory hepatopathy likely

INTERPRETATION OF THE FINDINGS & FURTHER RECOMMENDATIONS

The liver appears stable. The patient likely underwent an inflammatory hepatopathy in the past. However, there is no evidence of significant disease at this time.





PATIENT

Migo Rodgers

The information and recommendations provided are based on the images presented by the referring veterinarian. No evaluation can be communicated regarding pathology that was not visible in the image/video clips provided.

SPECIES

Canine

Thank you for this referral. If the clinical or image interpretation does not parallel your findings or if I can be of any further assistance please contact me.

BREED

Labrador Retriever

Eric Lindquist, DMV, DABVP, Cert. IVUSS, CEO of SonoPath.com
Eric.Lindquist@SonoPath.com

SEX

MN

AGE

3 yr

WEIGHT

41 kg

INTERPRETED BY

Eric Lindquist, DMV
DABVP, Cert. IVUSS

**IMAGING
PERFORMED BY**

Hayley Biederbeck

HOSPITAL NAME

Lomsnes Veterinary
Hospital

REFERRING VET

Dr. Hayley
Biederbeck

INVOICE

10865ag

DATE

06/20/2022