SonoPath
Clinical Sonography & Telecytology

EDUCATIONAL TELECONSULTATION SERVICES™

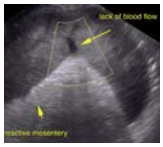

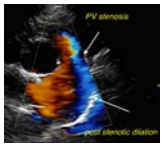

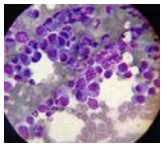
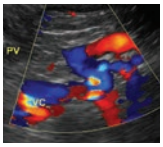

SonoPath.com™
1-800-838-4268 info@sonopath.com

PATIENT
Luna Delgado

SPECIES
Canine

BREED
West Highland Terrier

SEX
Spayed Female

AGE
3 Years

WEIGHT
17.2 Pounds

INTERPRETED BY
Eric Lindquist, DMV
DABVP, Cert. IVUSS

IMAGING PERFORMED BY
Dr. Gabriel Ferrer

HOSPITAL NAME
Paseos Vet Center

REFERRING VET
Dr. Gabriel Ferrer

INVOICE
38908

DATE
6/20/22

PRESENTING CLINICAL SIGNS

Presented for evaluation of vomiting. Patient started to vomit 2 days ago. PT has a history of eating foreign things. PT is depressed and lethargic and anorexic. Tried to eat and vomits.
Abnormal PE/Chem/CBC/UA Results: PE: Temp 98F, tension and discomfort on abdominal palpation. BW: CBC: Increased HCT 64%, increase monocytes CHEM: Increased BUN 54, Phos: 12.4, Glob: 1.4, ALP: 263, Tbili: 1.5, K: 7.3, Cl 100. ABd rads: Severe distended stomach with fluid filled. Distension of intestinal loops.

ULTRASONOGRAPHIC EXAMINATION OF THE ABDOMEN

Urinary System

The **urinary bladder**, trigone, and pelvic urethra presented normal thicknesses and normal tone. The ureters were not visible which is normal. No uroliths or sediment were visualized and anechoic urine was present. No evidence of inflammatory or neoplastic changes were noted. Ureteral papillae were normal.

The **kidneys** revealed normal size and structure, corticomedullary definition and ratio for this age. The cortices presented largely uniform texture with normal echogenic relationship to liver and spleen. Medullary structure differed distinctly from the cortex and no evidence of pelvic dilation was present. The capsules were acceptably uniform without significant irregularities. The left kidney measured 4.62 cm. The right kidney measured 3.76 cm.

Adrenal Glands

Both **adrenal glands** were visualized and recognized as having normal shape, size, position and echogenicity for this breed. The phrenic vasculature, glandular echogenicity and detail were unremarkable. Capsule, cortex, and medullary definition were normal for this age patient. The left adrenal gland measured 0.38 cm. The right adrenal gland measured 0.47 cm.

Spleen

The **spleen** presented a smooth homogeneous parenchyma hyperechoic to liver and renal cortical parenchyma. The spleen was folded upon itself caudally. The capsule was smooth without noticeable expansion or deviation from within the spleen or adjacent pathology. The splenic vasculature demonstrated normal volume without signs of congestion or thrombosis. No sonographic evidence of acute or chronic inflammatory, neoplastic, or infarctual changes were noted.

Liver

The **liver** presented mild increased portal markings. The gallbladder was unremarkable.

Gastrointestinal

The **pylorus** was patent. The upper small intestine was dilated, followed by empty small intestine, comprising an obstructive pattern. The distal small intestine revealed a shadowing foreign body measuring approximately 3.0 cm. Variable intestinal thickening noted with reactive surrounding mesentery.

Pancreas

The base and limbs of the **pancreas** were observed to be largely isoechoic to surrounding omental fat. Pancreatic duct and capsular contour were acceptably normal and parenchyma respected normal curvilinear patterns. No overt evidence of active inflammatory or neoplastic disease was noted.

SonoPath
Clinical Sonography & Telecytology

EDUCATIONAL TELECONSULTATION SERVICES™

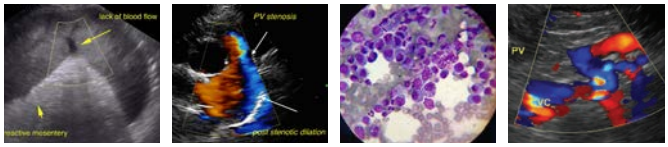

SonoPath.com™
1-800-838-4268 info@sonopath.com

PATIENT

Luna Delgado

SPECIES

Canine

BREED

West Highland Terrier

SEX

Spayed Female

AGE

3 Years

WEIGHT

17.2 Pounds

INTERPRETED BY

Eric Lindquist, DMV

DABVP, Cert. IVUSS

IMAGING PERFORMED BY

Dr. Gabriel Ferrer

HOSPITAL NAME

Paseos Vet Center

REFERRING VET

Dr. Gabriel Ferrer

INVOICE

38908

DATE

6/20/22

PRIMARY FINDINGS

- Jejunal foreign body with variable intestinal thickening and gastric stasis

SECONDARY FINDINGS

- Mild increased portal markings

INTERPRETATION OF THE FINDINGS & FURTHER RECOMMENDATIONS

Immediate exploratory surgery recommended with intestinal biopsies. Liver biopsy warranted, given the liver enzyme elevations. Leptospirosis titers also warranted. GI biopsies warranted to rule out underlying disease.

According to Sonopath research presented at ECVIM 2016 (Stockholm, Sweden), Advances in Small Animal Medicine and Surgery (May 2017), and EVDI 2017 (Verona, Italy), concurrent underlying chronic inflammatory neoplastic intestinal disease can often reside in PICA patients. Therefore, surgical biopsies are essential in this case regardless of the exploratory findings.

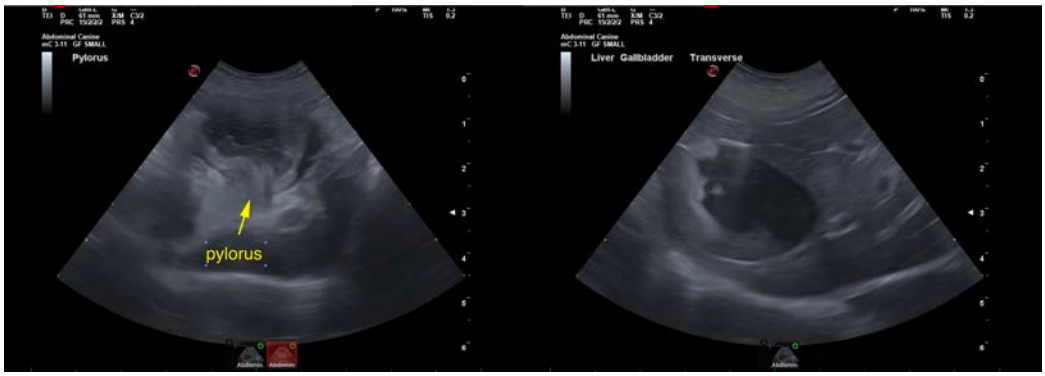

SonoPath

Clinical Sonography & Telecytology

EDUCATIONAL TELECONSULTATION SERVICES™

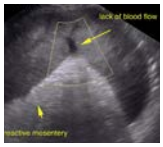
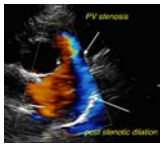
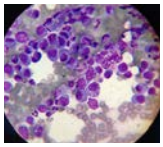
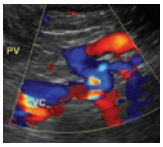

SonoPath.com™
1-800-838-4268 info@sonopath.com

PATIENT

Luna Delgado

SPECIES

Canine

BREED

West Highland Terrier

SEX

Spayed Female

AGE

3 Years

WEIGHT

17.2 Pounds

INTERPRETED BY

Eric Lindquist, DMV

DABVP, Cert. IVUSS

IMAGING PERFORMED BY

Dr. Gabriel Ferrer

HOSPITAL NAME

Paseos Vet Center

REFERRING VET

Dr. Gabriel Ferrer

INVOICE

38908

DATE

6/20/22

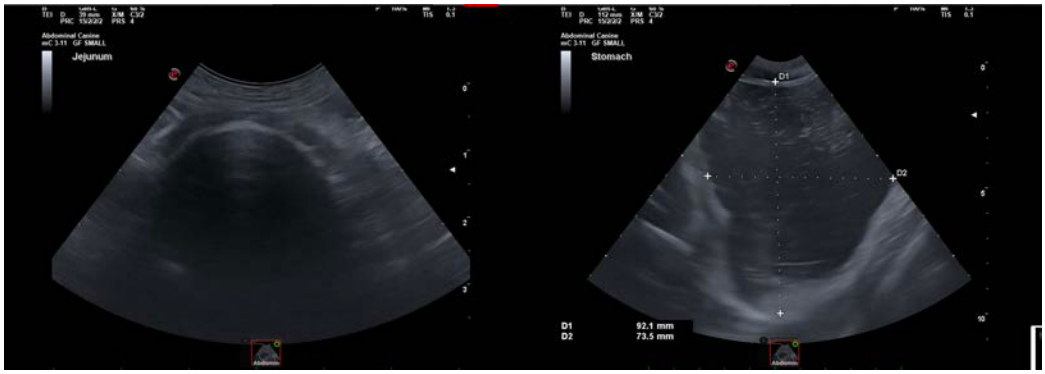

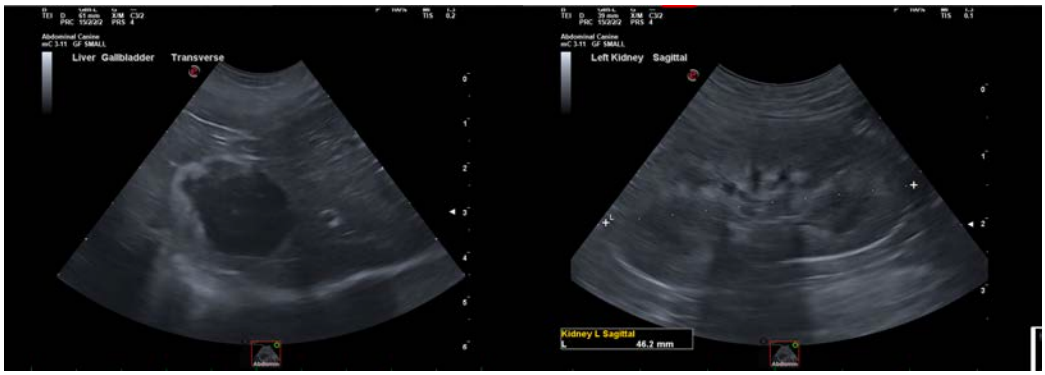

SonoPath
Clinical Sonography & Telecytology

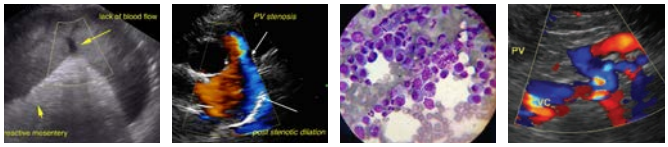

EDUCATIONAL TELECONSULTATION SERVICES™

SonoPath.com™
1-800-838-4268 info@sonopath.com

PATIENT

Luna Delgado

SPECIES

Canine

BREED

West Highland Terrier

SEX

Spayed Female

AGE

3 Years

WEIGHT

17.2 Pounds

INTERPRETED BY

Eric Lindquist, DMV

DABVP, Cert. IVUSS

IMAGING PERFORMED BY

Dr. Gabriel Ferrer

HOSPITAL NAME

Paseos Vet Center

REFERRING VET

Dr. Gabriel Ferrer

INVOICE

38908

DATE

6/20/22

The information and recommendations provided are based on the images presented by the referring veterinarian/sonographer. No evaluation can be communicated regarding pathology that was not visible in the image/video clips provided.

Thank you for this referral. If the clinical or image interpretation does not parallel your findings or if I can be of any further assistance please contact me.

Eric Lindquist, DMV, DABVP, Cert. IVUSS, CEO of SonoPath.com

info@SonoPath.com