



PATIENT

Zoey Chavez

SPECIES

Canine

BREED

Boxer

SEX

Spayed female

AGE

9 years

WEIGHT

67 lbs

INTERPRETED BY

Eric Lindquist, DMV
DABVP, Cert. IVUSS

IMAGING PERFORMED BY

Erin Henderson

HOSPITAL NAME

Lyon V C

REFERRING VET

Dr. Henderson

INVOICE

78299

DATE

6/2/26

PRESENTING CLINICAL SIGNS

History: Arrhythmia identified on routine physical exam 10 days ago. Has been present at each of the three visits to the hospital in that time period, so appears to be sustained. Owner's report no physical symptoms at home. Patient is hypothyroid as of 2021, and has been well managed on levothyroxine. Also on firocoxib for arthritis. Otherwise no health problems.

Abnormal PE/Chem/CBC/UA Results: Arrhythmia with VPC noted in pairs and runs. No murmur appreciated. No increased respiratory effort, rate is a comfortable pant, which is typical for patient. Routine blood work in March should normal CBC, Chem 27, and TT4=3.8 (normal for patient on supplementation). BP today under sedation for echo is 108/78.

ULTRASONOGRAPHIC EXAMINATION OF THE HEART

The echocardiogram in this patient demonstrated slight volume overload of all four chambers appeared to be present. This is likely owing to the tachyarrhythmia. Otherwise, the heart was structurally unremarkable. Tachyarrhythmia appeared to be present in this patient.

CANINE CARDIAC PARAMETERS	MR VMAX (m/s)	TR VMAX (m/s)	LA/AO	LA/AO (Heart Base)	FS (%)	EF (%)	EPSS (cm)
NORMAL PARAMETER	4.5-5.5	<2.7	1.3	<1.6	28-40	40-100	<0.6
PATIENT	NM	NM	NM	1.6	35	NM	NM
CANINE CARDIAC PARAMETERS	HR (BPM)	AV VMAX (m/s)	PV MAX (m/s)	BODY WEIGHT	LA 2D short axis Base view (cm)	LVIDd Avg; 2D and m-mode short axis (cm)	LVIDs Avg; 2D and m-mode short axis (cm)
NORMAL PARAMETER	50-100	0.7-1.7	0.7-1.6	BELOW	BELOW	BELOW	BELOW
PATIENT	NM	NM	NM	67 lbs	NM	3.7	

ULTRASONOGRAPHIC FINDINGS

Tachyarrhythmia.

Structurally normal heart otherwise.

Boxer cardiomyopathy is likely.

INTERPRETATION OF THE FINDINGS & FURTHER RECOMMENDATIONS

Management is recommended based on EKG or Holter monitor. The prognosis is guarded.



PATIENT

Zoey Chavez

SPECIES

Canine

BREED

Boxer

SEX

Spayed female

AGE

9 years

WEIGHT

67 lbs

INTERPRETED BY

Eric Lindquist, DMV
DABVP, Cert. IVUSS

IMAGING PERFORMED BY

Erin Henderson

HOSPITAL NAME

Lyon VC

REFERRING VET

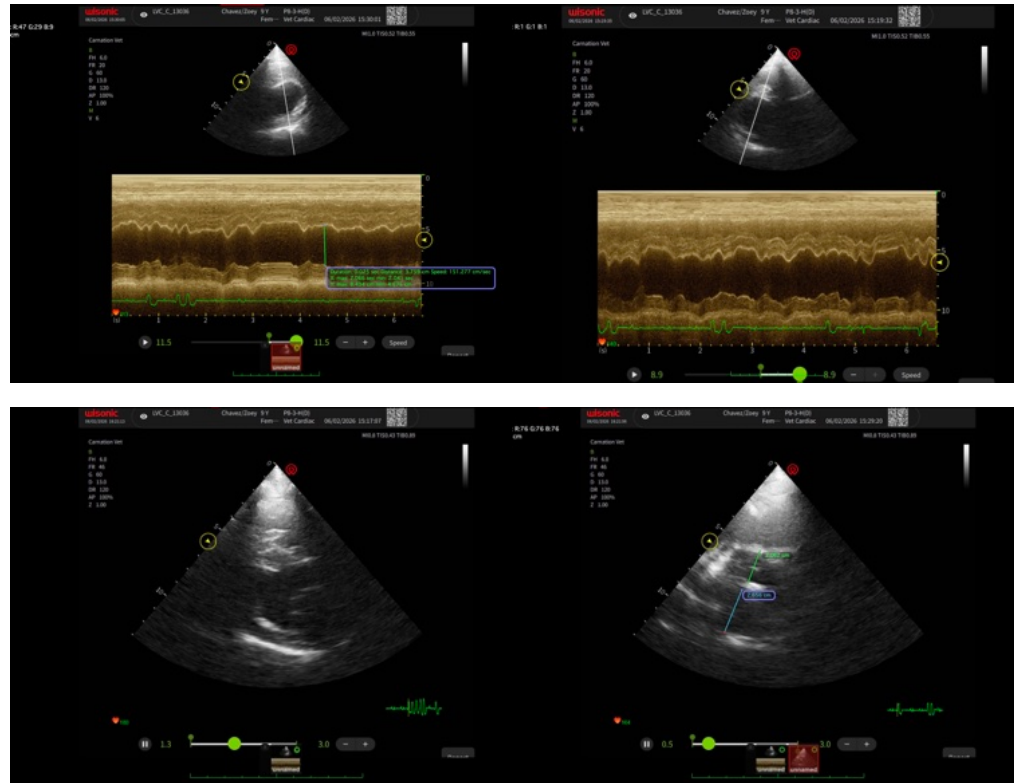
Dr. Henderson

INVOICE

78299

DATE

6/2/26



The information and recommendations provided are based on the images presented by the referring veterinarian/sonographer. No evaluation can be communicated regarding pathology that was not visible in the image/video clips provided.

Thank you for this referral. If the clinical or image interpretation does not parallel your findings or if I can be of any further assistance please contact me.

Eric Lindquist, DMV, DABVP (CFM), Cert. IVUSS, CEO of SonoPath.com

info@SonoPath.com