



## PATIENT

Finnley Rousseau

## SPECIES

Canine

## BREED

Lab Mix

## SEX

Neutered male

## AGE

3 years

## WEIGHT

69 lbs

## INTERPRETED BY

Eric Lindquist, DMV  
DABVP, Cert. IVUSS

## IMAGING PERFORMED BY

Dr. Velez

## HOSPITAL NAME

Court Street VH

## REFERRING VET

Dr. Velez

## INVOICE

78271

## DATE

6/2/26

## PRESENTING CLINICAL SIGNS

History: On and off leaking urine since December. When it started, patient had a couple UTI's but still occurring despite full resolution of infections.

## ULTRASONOGRAPHIC EXAMINATION OF THE ABDOMEN

**\*\*65 still images and 3 videos were submitted.**

### BASED ON THIS IMAGE SET:

#### *Urinary System*

The **urinary bladder**, trigone, and pelvic urethra presented normal thicknesses and normal tone. The ureters were not visible which is normal. No uroliths or sediment were visualized and anechoic urine was present. No evidence of inflammatory or neoplastic changes was noted. Ureteral papillae were normal.

The **kidneys** revealed normal size and structure, corticomedullary definition and ratio for this age. The cortices presented largely uniform texture with normal echogenic relationship to liver and spleen. Medullary structure differed distinctly from the cortex and no evidence of pelvic dilation was present. The capsules were acceptably uniform without significant irregularities. The right kidney measured 6.2 cm. The left kidney measured 6.0 cm.

#### *Adrenal Glands*

The **adrenal glands** were not visualized.

#### *Spleen*

The **spleen** presented a smooth homogeneous parenchyma hyperechoic to liver and renal cortical parenchyma. The capsule was smooth without noticeable expansion or deviation from within the spleen or adjacent pathology. The splenic vasculature demonstrated normal volume without signs of congestion or thrombosis. No sonographic evidence of acute or chronic inflammatory, neoplastic, or infarctual changes was noted.

#### *Liver*

The **liver** images submitted revealed subjectively normal liver size, contour, and structure. Parenchymal echogenicity was naturally coarse and hypoechoic to the spleen. Vascular and biliary tracts were of normal volume with no evidence of congestion. The gallbladder presented acceptably thin walls with primarily anechoic content. The cystic and common bile ducts were normal. No pathological hepatic lymphadenopathy was evident. No overt structural evidence of inflammatory, infiltrative or regenerative pathology was evident.



**PATIENT**

Finnley Rousseau

**SPECIES**

Canine

**BREED**

Lab Mix

**SEX**

Neutered male

**AGE**

3 years

**WEIGHT**

69 lbs

**INTERPRETED BY**

Eric Lindquist, DMV  
DABVP, Cert. IVUSS

**IMAGING PERFORMED BY**

Dr. Velez

**HOSPITAL NAME**

Court Street VH

**REFERRING VET**

Dr. Velez

**INVOICE**

78271

**DATE**

6/2/26

**Gastrointestinal**

Examination of the **gastrointestinal tract** revealed a stomach and intestine free of stasis, of normal wall thickness, acceptable curvilinear mural detail, and peristaltic activity. Small and large intestine demonstrated normal luminal chyme and stool consistency respectively. No obstructive or overt infiltrative disease was noted. No associated abnormal lymphatic activity was noted.

**Pancreas**

The base and limbs of the **pancreas** were observed to be largely isoechoic to surrounding omental fat. Pancreatic duct and capsular contour were acceptably normal and parenchyma respected normal curvilinear patterns. No overt evidence of active inflammatory or neoplastic disease was noted.

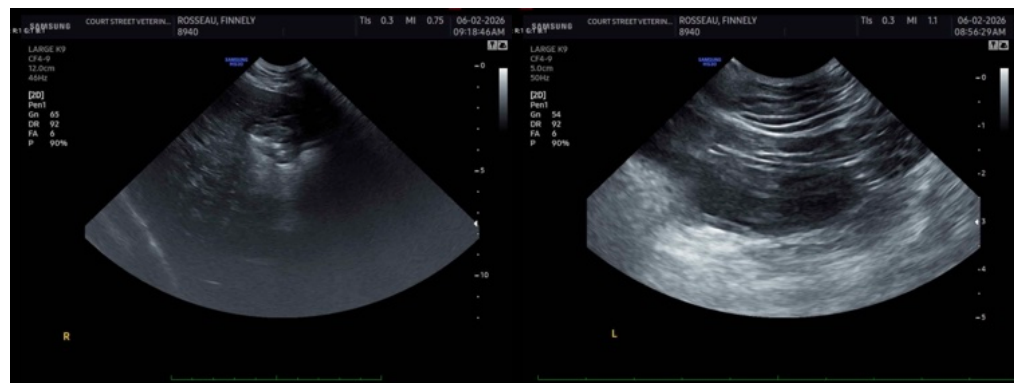**ULTRASONOGRAPHIC FINDINGS**

Based on these images, unremarkable abdomen.

**INTERPRETATION OF THE FINDINGS & FURTHER RECOMMENDATIONS**

Note that still image protocol provide a lot less information diagnostically. I strongly recommend submission of full video clip protocols such as SDEP or similar. You can reach out for more information at [info@sonopath.com](mailto:info@sonopath.com).

There was no gross evidence of ectopic ureters, yet I cannot rule this out.





## PATIENT

Finnley Rousseau

## SPECIES

Canine

## BREED

Lab Mix

## SEX

Neutered male

## AGE

3 years

## WEIGHT

69 lbs

## INTERPRETED BY

Eric Lindquist, DMV  
DABVP, Cert. IVUSS

## IMAGING PERFORMED BY

Dr. Velez

## HOSPITAL NAME

Court Street VH

## REFERRING VET

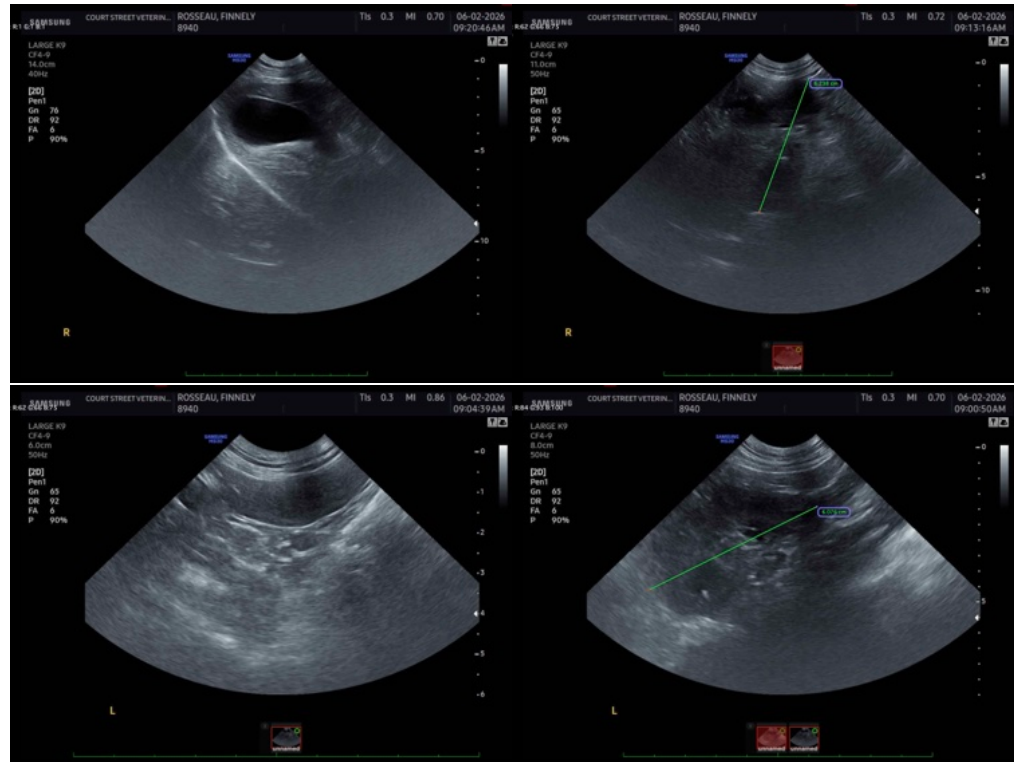
Dr. Velez

## INVOICE

78271

## DATE

6/2/26



The information and recommendations provided are based on the images presented by the referring veterinarian/sonographer. No evaluation can be communicated regarding pathology that was not visible in the image/video clips provided.

Thank you for this referral. If the clinical or image interpretation does not parallel your findings or if I can be of any further assistance please contact me.

Eric Lindquist, DMV, DABVP (CFM), Cert. IVUSS, CEO of SonoPath.com

[info@SonoPath.com](mailto:info@SonoPath.com)