



PATIENT

Brody Sudol

SPECIES

Canine

BREED

Dachshund

SEX

Neutered Male

AGE

13

WEIGHT

13

INTERPRETED BY

Eric Lindquist, DMV,
DABVP(CFM), Cert.
IVUSS

IMAGING PERFORMED BY

Jenn

HOSPITAL NAME

Rockaway Animal
Hospital

REFERRING VET

Dr. Dubos

INVOICE

16244

DATE

06/02/26

PRESENTING CLINICAL SIGNS

Presented for having diarrhea for 3 months started on Metro didn't help, stopped eating dog food only chicken, black stool r/o dietary intolerance IBD parasites Also has severe dental dz, scheduled to have dental on Thurs Has HM r/o degenerative valve dz , congenital heart dz

Abnormal PE/Chem/CBC/UA Results: Stress leukogram K 6.6 Chlor 108 Cortisol 3.61 r/o Addison's

ULTRASONOGRAPHIC EXAMINATION OF THE HEART & ABDOMEN

CANINE CARDIAC PARAMETERS	MR VMAX (m/s)	TR VMAX (m/s)	LA/AO (M-Mode)	LA/AO (Heart Base; Swe)	FS (%)	EF (%)	EPSS (cm)
NORMAL PARAMETER	4.5-5.5	<2.7	1.3	Up to 1.6	28-40	40-100	<0.6
PATIENT	--	--	1.0	1.0	35	80	NM
CANINE CARDIAC PARAMETERS	HR (BPM)	AV VMAX (m/s)	PV MAX (m/s)	BODY WEIGHT	LAD LA MAX 4 Chamber	LVIDd Avg; 2D and m-mode short axis (cm)	LVIDs Avg; 2D and m-mode short axis (cm)
NORMAL PARAMETER	50-100	0.7-1.7	0.7-1.6				
PATIENT	110	NM	0.91	13	1.8	1.8	--

E-wave V: 0.6

Cardiac Presentation

The echocardiogram in this patient demonstrated normal **left atrial** size based on 3 different LA measurement methods. Chamber volumes and echogenicity were normal. The cranial and caudal **mitral** valve leaflets presented vegetative thickening consistent with endocardiosis. Doppler indicated measurable insufficiency. The **left ventricle** presented normal thicknesses with linear contour and was not dilated nor restricted. The **myocardium** presented normal echogenicity without subjective evidence of significant fibrotic or ischemic disease. **Contractility** of the ventricular walls was adequate and in normal range for this patient evidenced by the fractional shortening measurement and subjective evaluation of the different regions of the myocardium. The **left ventricular outflow** tract demonstrated normal laminar flow and subjective structural integrity. The **right atrium** and auricle revealed normal size, structure and content. No evidence of masses was noted or chamber overload. **Tricuspid** valvular assessment demonstrated adequate linear morphology. The **right ventricle** was of normal size (1/3 diameter of LV), chordae structure, myocardial echogenicity and thickness. **Pulmonic** tract assessment revealed normal valve structure, laminar flow, and diameter (approx.1:1 pa/ao ratio). No visible **pericardial** or free pleura fluid was noted. No echographically detectable evidence of infiltrative disease was visible. The cranial **mediastinum and pericardial regions** were free of masses in the visible window.

Urinary System



PATIENT

Brody Sudol

SPECIES

Canine

BREED

Dachshund

SEX

Neutered Male

AGE

13

WEIGHT

13

INTERPRETED BY

Eric Lindquist, DMV,
DABVP(CFM), Cert.
IVUSS

IMAGING PERFORMED BY

Jenn

HOSPITAL NAME

Rockaway Animal
Hospital

REFERRING VET

Dr. Dubos

INVOICE

16244

DATE

06/02/26

The **urinary bladder**, trigone, and pelvic urethra presented normal thicknesses and normal tone. The ureters were not visible which is normal. No uroliths or sediment were visualized, and anechoic urine was present. No evidence of inflammatory or neoplastic changes were noted. Ureteral papillae were normal.

The **kidneys** revealed largely normal size and structure, corticomedullary definition and ratio (cortex 1/3 of medulla) were essentially maintained with some age-related loss of curvilinear patterns regarding the capsule and C/M junction. The cortices presented largely uniform texture with some increased echogenicity expected for his age patient. Medullary structure differed distinctly from that of the cortex and no evidence of pelvic dilation was present. The left kidney measured 5.0 cm in length.

Adrenal Glands

The **left adrenal gland** was visualized and recognized as having normal shape, size, position and echogenicity for this breed. The phrenic vasculature, glandular echogenicity and detail were unremarkable. Capsule, cortex, and medullary definition were normal for this age patient. The left adrenal gland measured 0.5 cm width.

The **right adrenal gland** was not visualized.

Spleen

The **spleen** presented a smooth homogeneous parenchyma hyperechoic to liver and renal cortical parenchyma. The capsule was smooth without noticeable expansion or deviation from within the spleen or adjacent pathology. The splenic vasculature demonstrated normal volume without signs of congestion or thrombosis. No sonographic evidence of acute or chronic inflammatory, neoplastic, or infarctual changes were noted.

Liver

The **liver** images from right and left intercostal as well as subcostal views revealed subjectively normal liver size, contour, and structure. Some mild age-related parenchymal remodeling was noted but likely not clinically significant at this time. Vascular and biliary tracts were of normal volume and no evidence of congestion was noted. The gallbladder presented some dependent debris with essentially normal contour. The cystic and common bile ducts were normal. No overt evidence of active inflammatory, infiltrative or regenerative pathology was noted but should be paired with current or past LE elevations regarding any clinical significance to this presentation. The hepatic lymph nodes were unremarkable.

Gastrointestinal

Examination of the **gastrointestinal tract** revealed a stomach and intestine free of stasis, of normal wall thickness, acceptable curvilinear mural detail, and peristaltic activity. Small and large intestine demonstrated normal luminal chyme and stool consistency respectively. No obstructive or overt infiltrative disease was noted. No associated abnormal lymphatic activity was noted.

Pancreas

The base and limbs of the **pancreas** were observed to be largely isoechoic to surrounding omental fat. Pancreatic duct and capsular contour were acceptably normal and parenchyma respected normal curvilinear patterns. No overt evidence of active inflammatory or neoplastic disease was noted.



PATIENT

Free Abdomen

Brody Sudol

The right **cranial abdomen** revealed an undifferentiated mixed echogenic nodular mass extending approximately 5.0+ cm, extending into the medial cranial abdomen. Free fluid was noted with mesenteric lymph nodes that appeared enlarged, rounded and hypoechoic. Reactive surrounding fat was noted. The mass may be right adrenal or right kidney in origin.

SPECIES

Canine

BREED

Dachshund

SEX

Neutered Male

AGE

13

WEIGHT

13

INTERPRETED BY

Eric Lindquist, DMV,
DABVP(CFM), Cert.
IUUSS

IMAGING PERFORMED BY

Jenn

HOSPITAL NAME

Rockaway Animal
Hospital

REFERRING VET

Dr. Dubos

INVOICE

16244

DATE

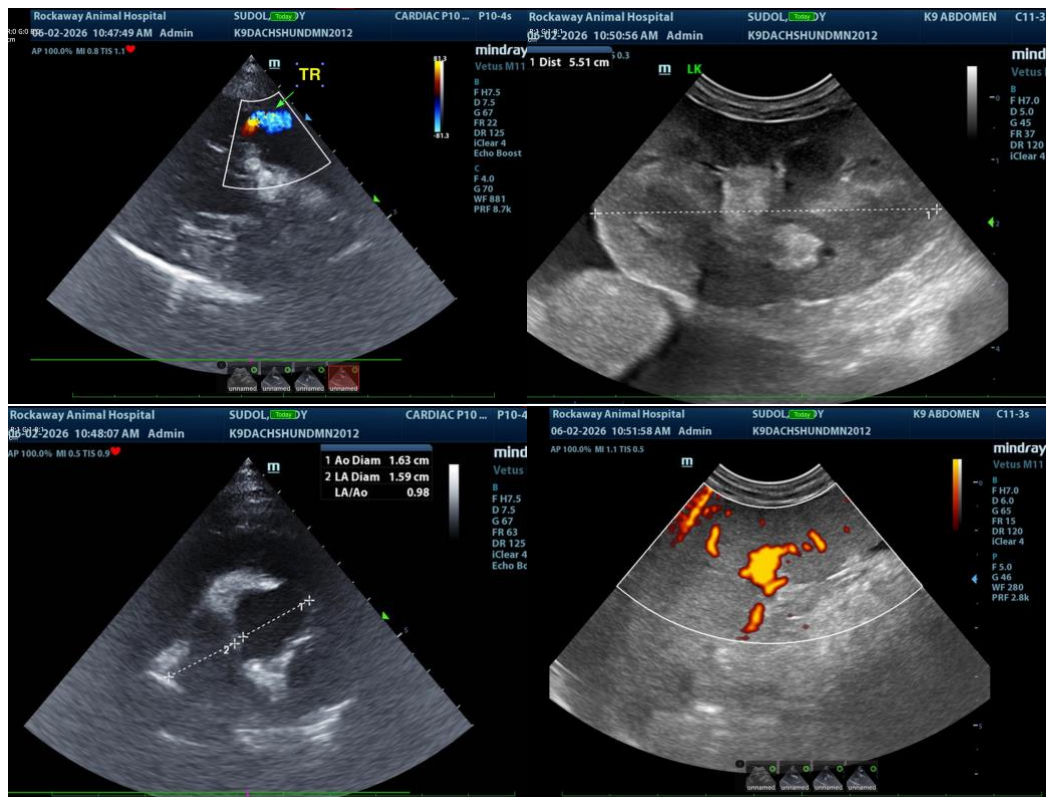
06/02/26

ULTRASONOGRAPHIC FINDINGS

- Stage B1 valvular disease.
- Cranial abdomen neoplasia- probable right adrenal derivation.
- Age-related hepatic remodeling.
- Age-related renal changes.

INTERPRETATION OF THE FINDINGS & FURTHER RECOMMENDATIONS

Abdominocentesis and cytospin could be considered for further definition. f accessible, FNA of the mass in the region of the right adrenal could be considered, likely pheochromocytoma or carcinoma, however, CT evaluation necessary for further definition.





PATIENT

Brody Sudol

SPECIES

Canine

BREED

Dachshund

SEX

Neutered Male

AGE

13

WEIGHT

13

INTERPRETED BY

Eric Lindquist, DMV,
DABVP(CFM), Cert.
IVUSS

IMAGING PERFORMED BY

Jenn

HOSPITAL NAME

Rockaway Animal
Hospital

REFERRING VET

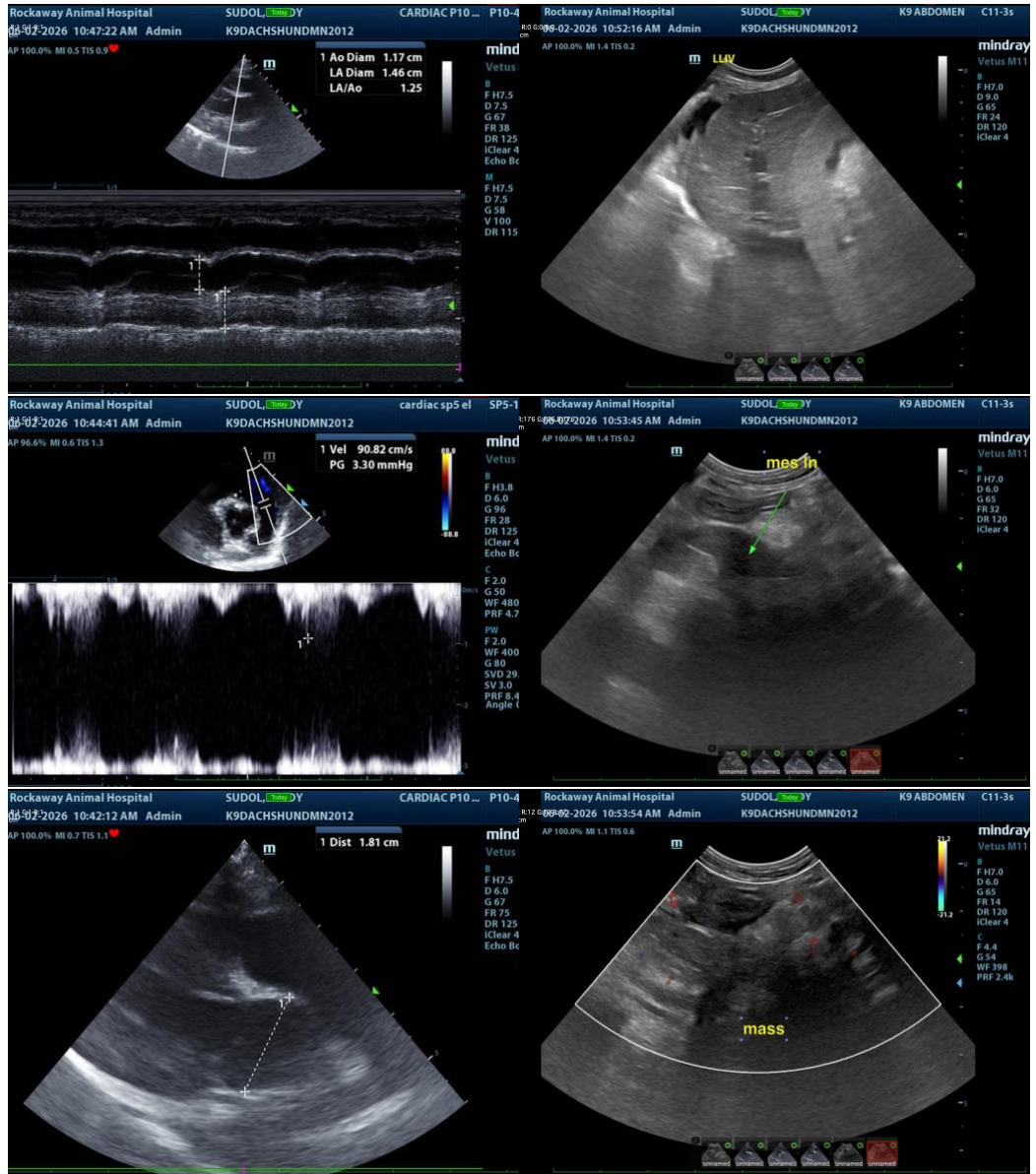
Dr. Dubos

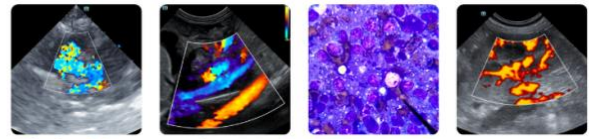
INVOICE

16244

DATE

06/02/26





PATIENT

Brody Sudol

SPECIES

Canine

BREED

Dachshund

SEX

Neutered Male

AGE

13

WEIGHT

13

INTERPRETED BY

Eric Lindquist, DMV,
DABVP(CFM), Cert.
IVUS

IMAGING PERFORMED BY

Jenn

HOSPITAL NAME

Rockaway Animal
Hospital

REFERRING VET

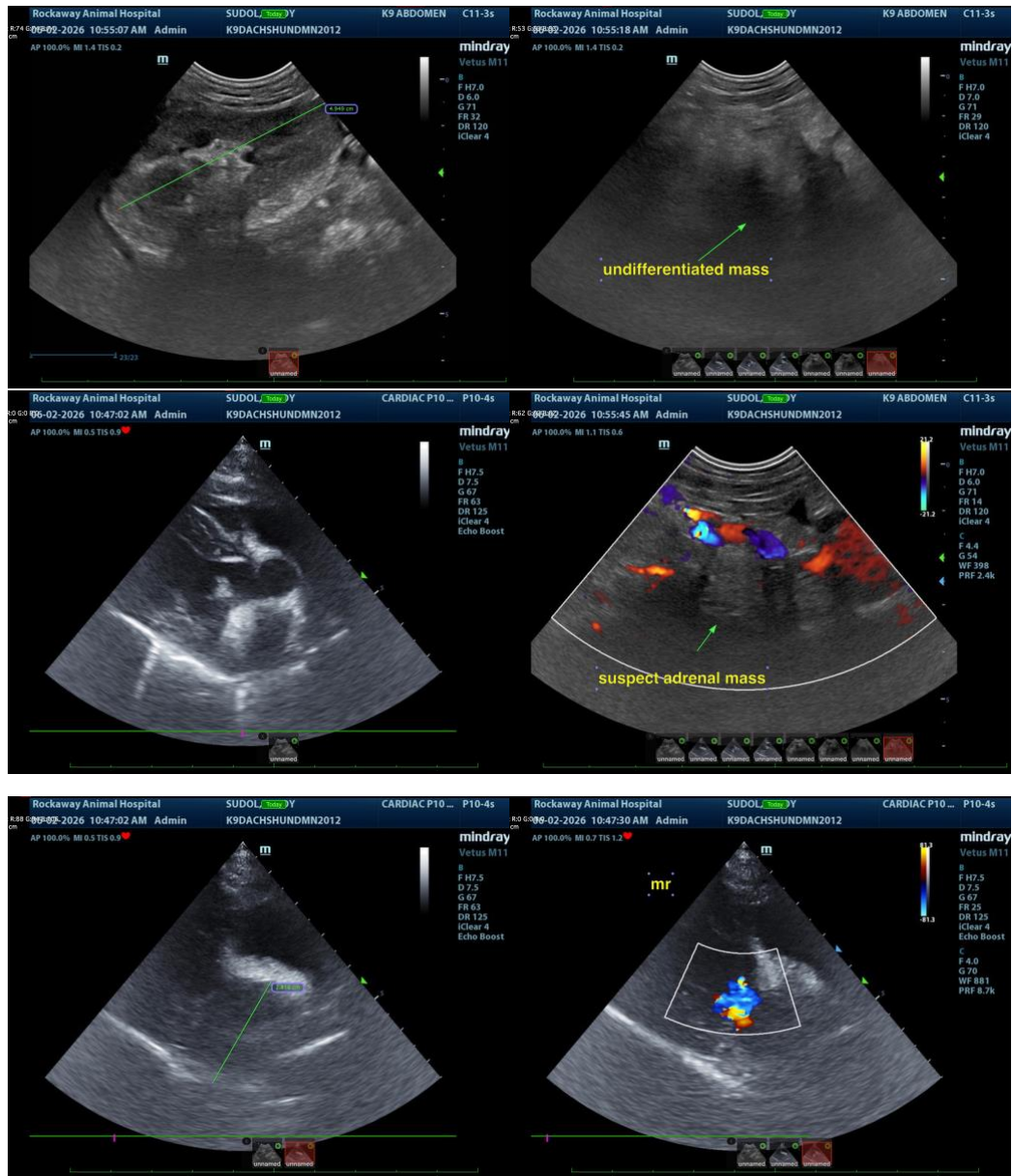
Dr. Dubos

INVOICE

16244

DATE

06/02/26



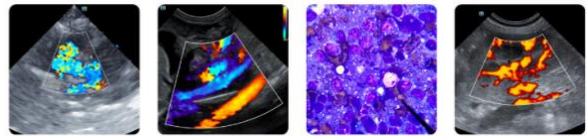
The information and recommendations provided are based on the images presented by the referring veterinarian/sonographer. No evaluation can be communicated regarding pathology that was not visible in the image/video clips provided.

Thank you for this referral. If the clinical or image interpretation does not parallel your findings or if I can be of any further assistance, please contact me.

Eric Lindquist, DMV, DABVP(CFM), Cert. IVUS,

CEO, Owner, Founder -- SonoPath.com

info@SonoPath.com



PATIENT

Brody Sudol

SPECIES

Canine

BREED

Dachshund

SEX

Neutered Male

AGE

13

WEIGHT

13

INTERPRETED BY

Eric Lindquist, DMV,
DABVP(CFM), Cert.
IVUSS

IMAGING PERFORMED BY

Jenn

HOSPITAL NAME

Rockaway Animal
Hospital

REFERRING VET

Dr. Dubos

INVOICE

16244

DATE

06/02/26