



PATIENT

Briggs Phillips

SPECIES

Canine

BREED

Maltese Mix

SEX

Neutered male

AGE

-

WEIGHT

16 lbs

INTERPRETED BY

Eric Lindquist, DMV
DABVP, Cert. IVUSS

IMAGING PERFORMED BY

Jill Rumachik

HOSPITAL NAME

Clarity Imaging LLC

REFERRING VET

Dr. Hoffman

INVOICE

78272

DATE

6/2/26

PRESENTING CLINICAL SIGNS

History: Pre-op echo prior to dental -- murmur 4/6 -- increasing in intensity.

ULTRASONOGRAPHIC EXAMINATION OF THE HEART

The echocardiogram in this patient demonstrated normal **left atrial** size based on 3 different LA measurement methods. Chamber volumes and echogenicity were normal. The cranial and caudal **mitral** valve leaflets presented vegetative thickening consistent with endocardiosis. Prolapse of the anterior mitral valve leaflet was noted. Moderate filling of the left atrium was noted on color flow assessment of the mitral valve. Doppler indicated measurable insufficiency. The **left ventricle** presented thicknesses with linear contour and was not dilated nor restricted. The **myocardium** presented normal echogenicity without subjective evidence of significant fibrotic or ischemic disease. **Contractility** of the ventricular walls was adequate and in normal range for this patient evidenced by the fractional shortening measurement and subjective evaluation of the different regions of the myocardium. **Aortic insufficiency** was noted. The **right atrium** and auricle revealed normal size, structure and content. No evidence of masses was noted or chamber overload. **Tricuspid** valvular assessment demonstrated adequate linear morphology. The **right ventricle** was of normal size (1/3 diameter of LV), chordae structure, myocardial echogenicity and thickness. **Pulmonic** tract assessment revealed normal valve structure, laminar flow, and diameter (approx. 1:1 pa/ao ratio). No visible **pericardial** or free pleura fluid was noted. No echographically detectable evidence of infiltrative disease was visible. The cranial **mediastinum and pericardial regions** were free of masses in the visible window. The hepatic veins were not dilated.

CANINE CARDIAC PARAMETERS	MR VMAX (m/s)	TR VMAX (m/s)	LA/AO	LA/AO (Heart Base)	FS (%)	EF (%)	EPSS (cm)
NORMAL PARAMETER	4.5-5.5	<2.7	1.3	<1.6	28-40	40-100	<0.6
PATIENT	> 5.0	2.3	NM	1.4	35	80	0.1
CANINE CARDIAC PARAMETERS	HR (BPM)	AV VMAX (m/s)	PV MAX (m/s)	BODY WEIGHT	LA 2D short axis Base view (cm)	LVIDd Avg; 2D and m-mode short axis (cm)	LVIDs Avg; 2D and m-mode short axis (cm)
NORMAL PARAMETER	50-100	0.7-1.7	0.7-1.6	BELOW	BELOW	BELOW	BELOW
PATIENT	90	1.5	1.4	16 lbs	2.6 max	2.4	

ULTRASONOGRAPHIC FINDINGS

Stage B1 valvular disease.



PATIENT

Briggs Phillips

SPECIES

Canine

BREED

Maltese Mix

SEX

Neutered male

AGE

-

WEIGHT

16 lbs

INTERPRETED BY

Eric Lindquist, DMV
DABVP, Cert. IVUSS

IMAGING PERFORMED BY

Jill Rumachik

HOSPITAL NAME

Clarity Imaging LLC

REFERRING VET

Dr. Hoffman

INVOICE

78272

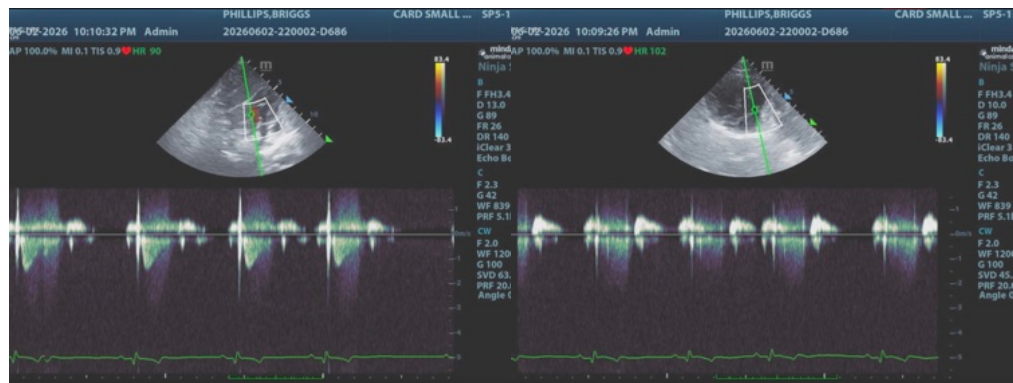
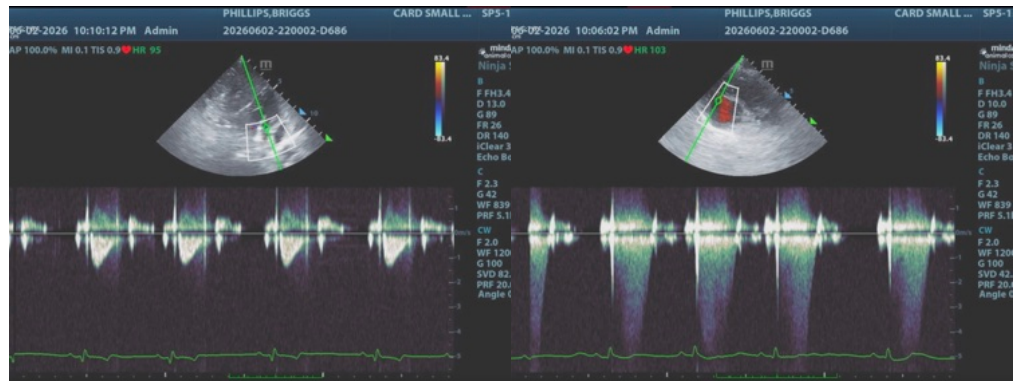
DATE

6/2/26

INTERPRETATION OF THE FINDINGS & FURTHER RECOMMENDATIONS

There is no gross contraindication to anesthetic procedure. Blood pressure measurements are indicated.

The heart is stable without clinical disease. No overt contraindication for anesthesia of brief to moderate duration. I suggest Torbutrol premed, Propofol induction, Isoflor maintenance or similar protocol if anesthesia is desired. Blood pressure recommended if not already performed and target white coat negative systolic pressure of < 160 mmHg. If higher than this ACE-inhibitor is suggested to reach this level. Recheck echocardiogram is recommended in 6 months, earlier if murmur grade increases or clinical signs initiate.





PATIENT

Briggs Phillips

SPECIES

Canine

BREED

Maltese Mix

SEX

Neutered male

AGE

-

WEIGHT

16 lbs

INTERPRETED BY

Eric Lindquist, DMV
DABVP, Cert. IVUSS

IMAGING PERFORMED BY

Jill Rumachik

HOSPITAL NAME

Clarity Imaging LLC

REFERRING VET

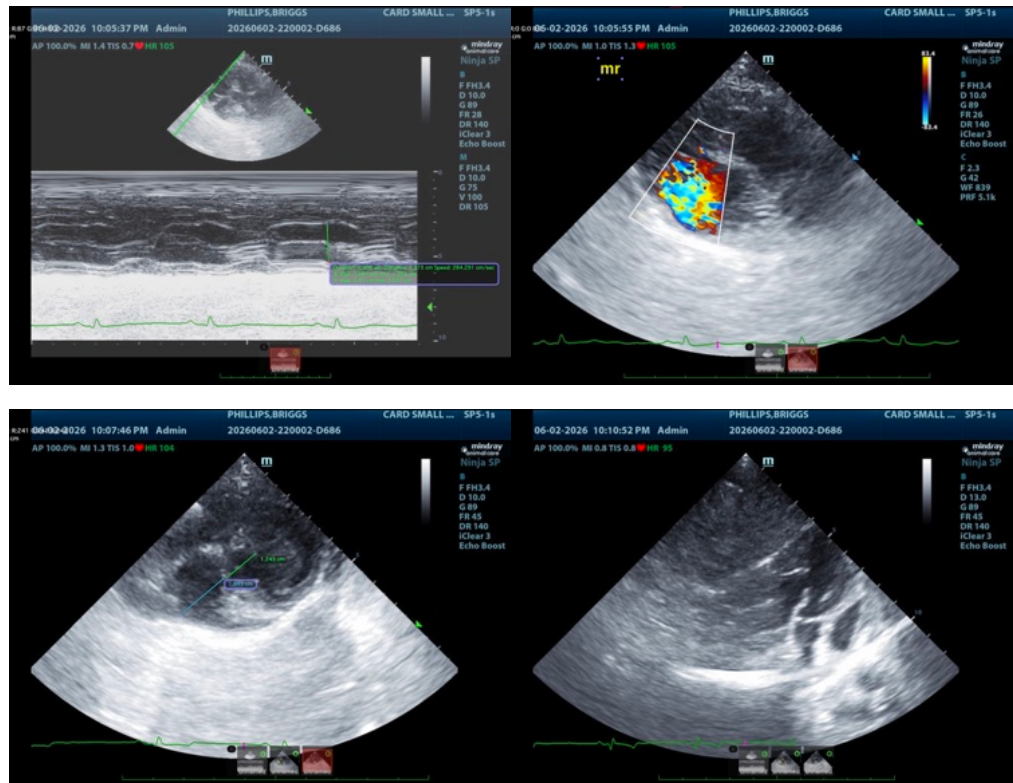
Dr. Hoffman

INVOICE

78272

DATE

6/2/26



The information and recommendations provided are based on the images presented by the referring veterinarian/sonographer. No evaluation can be communicated regarding pathology that was not visible in the image/video clips provided.

Thank you for this referral. If the clinical or image interpretation does not parallel your findings or if I can be of any further assistance please contact me.

Eric Lindquist, DMV, DABVP (CFM), Cert. IVUSS, CEO of SonoPath.com

info@SonoPath.com