



**PATIENT**

Buddy Reagle

**SPECIES**

Canine

**BREED**

Chihuahua

**SEX**

Neutered Male

**AGE**

13 Years

**WEIGHT**

11 Pounds

**INTERPRETED BY**

Eric Lindquist, DMV

DABVP, Cert. IVUSS

**IMAGING PERFORMED BY**

Dr. Mack

**HOSPITAL NAME**

Northside VC

**REFERRING VET**

Dr. Mack

**INVOICE**

38309

**DATE**

6/2/22

**PRESENTING CLINICAL SIGNS**

Patient has heart disease and is managed well on Furosemide and Vetmedin. Started Denamarin at visit on 5/5 after BW results

Abnormal PE/Chem/CBC/UA Results: ALKP 1393 ALT 152 CHOL 396

**ULTRASONOGRAPHIC EXAMINATION OF THE ABDOMEN**

**Urinary System**

The **urinary bladder**, trigone, and pelvic urethra presented normal thicknesses and normal tone. The ureters were not visible which is normal. No uroliths or sediment were visualized and anechoic urine was present. No evidence of inflammatory or neoplastic changes were noted. Ureteral papillae were normal. The pelvic urethra was imaged 1.0 cm beyond the cystourethral junction.

The residual prostate was uniform at 1.0 cm.

The **kidneys** revealed largely normal size and structure, corticomedullary definition and ratio (cortex 1/3 of medulla) were essentially maintained with some age-related loss of curvilinear patterns regarding the capsule and C/M junction. The cortices presented largely uniform texture with some increased echogenicity expected for his age patient. Medullary structure differed distinctly from that of the cortex and no evidence of pelvic dilation was present. The left kidney measured 4.0 cm. The right kidney measured 4.0 cm.

**Adrenal Glands**

Both **adrenal glands** were visualized and recognized as having normal shape, size, position and echogenicity for this breed. The phrenic vasculature, glandular echogenicity and detail were unremarkable. Capsule, cortex, and medullary definition were normal for this age patient. The left adrenal gland measured 0.40 cm. The right adrenal gland measured 0.50 cm.

**Spleen**

The **spleen** presented a smooth homogeneous parenchyma hyperechoic to liver and renal cortical parenchyma. The capsule was smooth without noticeable expansion or deviation from within the spleen or adjacent pathology. The splenic vasculature demonstrated normal volume without signs of congestion or thrombosis. No sonographic evidence of acute or chronic inflammatory, neoplastic, or infarctual changes were noted.

**Liver**

The **liver** was uniformly swollen with minor, excessive gallbladder debris and over distension with dependent and suspended bile without evidence of overt mucocele formation. However, excessive sludge was present. The liver presented coarse architecture with mildly increased portal markings and subtle, mixed echogenic changes. This is consistent with vacuolar hepatopathy and some level of remodeling and history of inflammatory component. There was no overt suspicion of neoplasia.

**Gastrointestinal**

A minor amount of non-shadowing, non-obstructive ingesta was noted in the **stomach**. Transit of chyme into the small intestine was normal. Curvilinear patterns were maintained throughout the GI tract. No evidence of pathology. Small and large intestine demonstrated normal luminal chyme and stool consistency respectively. No obstructive or overt infiltrative disease was noted. No associated abnormal lymphatic activity was noted.



**PATIENT**

**Pancreas**

Buddy Reagle

The base and limbs of the **pancreas** were observed to be largely isoechoic to surrounding omental fat. Pancreatic duct and capsular contour were acceptably normal and parenchyma respected normal curvilinear patterns. No overt evidence of active inflammatory or neoplastic disease was noted.

**SPECIES**

Canine

**ULTRASONOGRAPHIC FINDINGS**

- Vacuolar hepatopathy with remodeling – subjectively benign. However, FNA could be considered for further definition.

**BREED**

Chihuahua

**INTERPRETATION OF THE FINDINGS & FURTHER RECOMMENDATIONS**

No evidence or suspicion of neoplasia. Likely endocrinopathy or genetic predisposition towards vacuolar hepatopathy with chronic inflammatory component. Bile acid profile would be ideal to assess for any early dysfunction, yet not suspected.

**SEX**

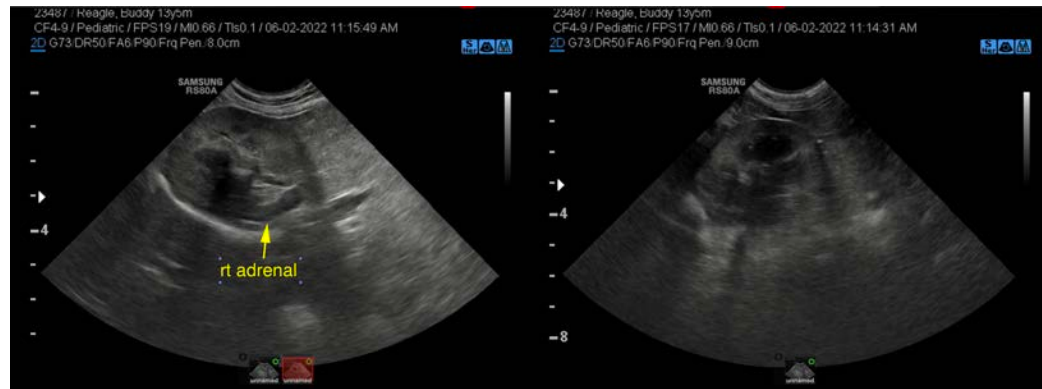Neutered Male

**AGE**

13 Years

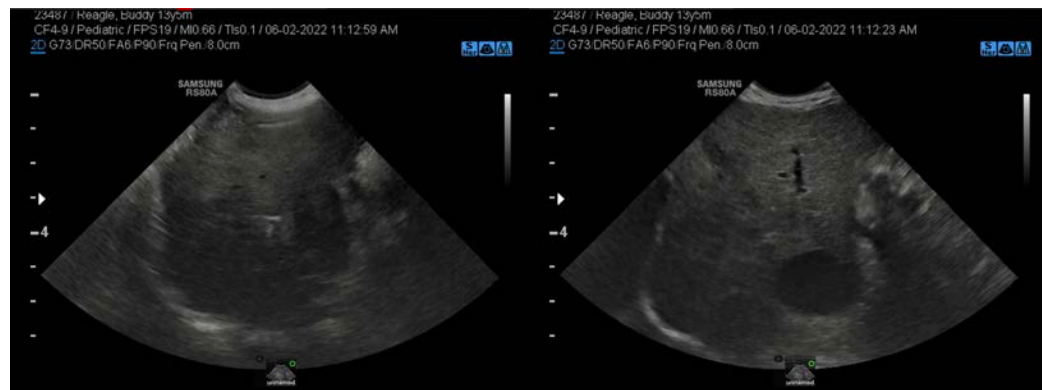
**WEIGHT**

11 Pounds



**INTERPRETED BY**

Eric Lindquist, DMV



DABVP, Cert. IVUSS

**IMAGING PERFORMED BY**

Dr. Mack

**HOSPITAL NAME**

Northside VC

**REFERRING VET**

Dr. Mack

**INVOICE**

38309

**DATE**

6/2/22



**PATIENT**

Buddy Reagle

**SPECIES**

Canine

**BREED**

Chihuahua

**SEX**

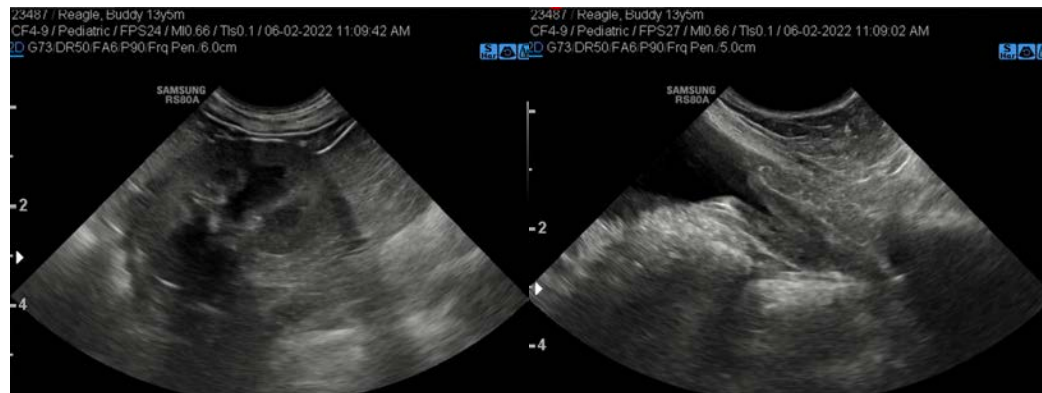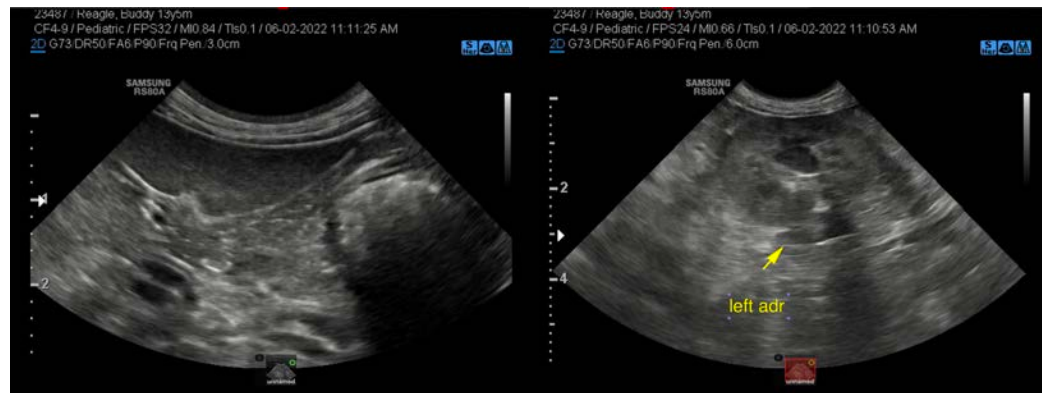
Neutered Male

**AGE**

13 Years

**WEIGHT**

11 Pounds



**INTERPRETED BY**

Eric Lindquist, DMV

DABVP, Cert. IVUSS

**IMAGING PERFORMED BY**

Dr. Mack

**HOSPITAL NAME**

Northside VC

**REFERRING VET**

Dr. Mack

**INVOICE**

38309

**DATE**

6/2/22

The information and recommendations provided are based on the images presented by the referring veterinarian/sonographer. No evaluation can be communicated regarding pathology that was not visible in the image/video clips provided.

Thank you for this referral. If the clinical or image interpretation does not parallel your findings or if I can be of any further assistance please contact me.

Eric Lindquist, DMV, DABVP, Cert. IVUSS, CEO of SonoPath.com

[info@SonoPath.com](mailto:info@SonoPath.com)