

**DATE**

6/2/22

PRESENTING CLINICAL SIGNS

History of 3/6 heart murmur, Chronic hepatopathy

PATIENT

Buddy Brown

Current Medications: Denamarin.

Lab Results: 11/23/21: CBC/Chem: ALKP: 397 H (23-212) ALT: 320 H (10-125). 1/24/2022: Hepatic panel: ALKP 269 (23-212)

5/25/22: CBC/Chem: ALKP 606 (23-212), ALT 95 (10-125)

SPECIES

Canine

Date of Previous IntraPet Ultrasound: No previous.

Sedation: Not required to complete full diagnostic ultrasound.

Stat Report: Declined.

BREED

Yorkie

ULTRASONOGRAPHIC EXAMINATION OF THE ABDOMEN**Urinary System**

The **urinary bladder**, trigone, and pelvic urethra presented normal thicknesses and normal tone. The ureters were not visible which is normal. No uroliths or sediment were visualized and anechoic urine was present. No evidence of inflammatory or neoplastic changes were noted. Ureteral papillae were normal.

AGE

5/25/12

The prostate was uniform at 3.25 cm, slightly heterogeneous. No significant deviation of the descending colon.

WEIGHT

13.8 Pounds

The **kidneys** revealed largely normal size and structure, corticomedullary definition and ratio (cortex 1/3 of medulla) were essentially maintained with some age-related loss of curvilinear patterns regarding the capsule and C/M junction. The cortices presented largely uniform texture with some increased echogenicity expected for his age patient. Medullary structure differed distinctly from that of the cortex and no evidence of pelvic dilation was present. The right kidney measured 4.99 cm. The left kidney measured 4.81 cm.

INTERPRETED BYEric Lindquist, DMV
DABVP, Cert. IVUSS**Adrenal Glands**

Both **adrenal glands** were visualized and recognized as having normal shape, size, position and echogenicity for this breed. The phrenic vasculature, glandular echogenicity and detail were unremarkable. Capsule, cortex, and medullary definition were normal for this age patient. The right adrenal gland measured 1.75 cm x 0.44 cm at the caudal pole and 0.56 cm at the cranial pole. The left adrenal gland measured 1.62 cm x 0.48 cm at the caudal pole and 0.40 cm at the cranial pole.

IMAGING PERFORMED BYStephanie Pearce
RDMS, RVT**Spleen**

The **spleen** presented a smooth homogeneous parenchyma hyperechoic to liver and renal cortical parenchyma. The capsule was smooth without noticeable expansion or deviation from within the spleen or adjacent pathology. The splenic vasculature demonstrated normal volume without signs of congestion or thrombosis. No sonographic evidence of acute or chronic inflammatory, neoplastic, or infarctual changes were noted.

HOSPITAL NAME

Banfield White Marsh

Liver

The **liver** presented heterogenous parenchyma with increased portal markings and coarse architecture. Slight undulating capsular contour was noted. Lobar biliary mineralizations noted. The gallbladder and common bile duct were unremarkable. This is consistent with chronic inflammatory hepatopathy.

REFERRING VET

Dr. Gutwillig

INVOICE

38317

Gastrointestinal

Examination of the **gastrointestinal tract** revealed a stomach and intestine free of stasis, of normal wall thickness, acceptable curvilinear mural detail, and peristaltic activity. Small and large intestine demonstrated normal luminal chyme and stool consistency respectively. No obstructive or overt infiltrative disease was noted. No associated abnormal lymphatic activity was noted.

Pancreas

The base and limbs of the **pancreas** were observed to be largely isoechoic to surrounding omental fat. Pancreatic duct and capsular contour were acceptably normal and parenchyma respected normal curvilinear patterns. No overt evidence of active inflammatory or neoplastic disease was noted.

Other

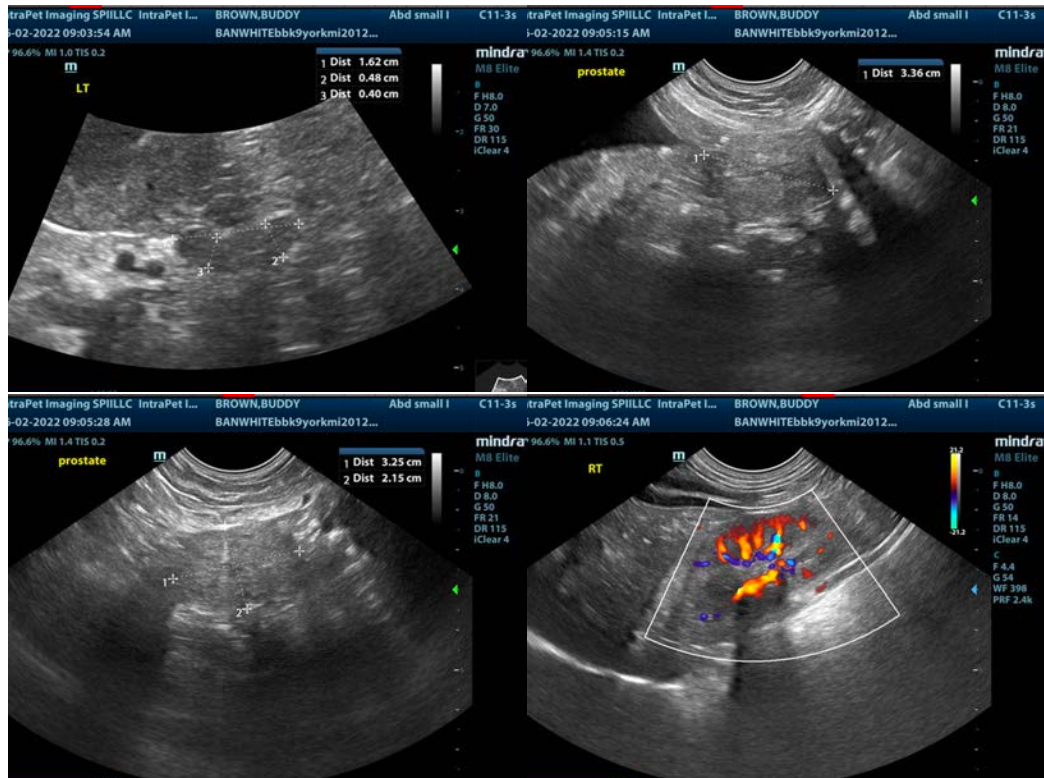
The testicles were imaged and found to be uniform, measuring 2.5 cm each.

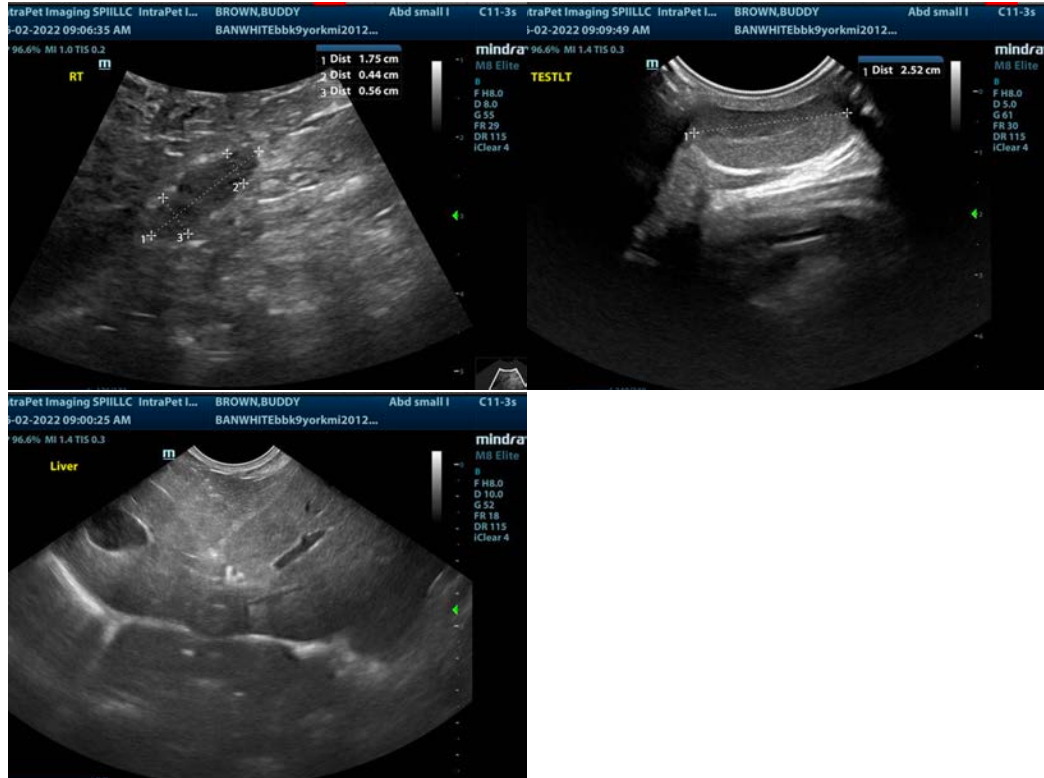
ULTRASONOGRAPHIC FINDINGS

- Subjectively benign hepatopathy with inflammatory component and lobar biliary mineralization
- Age related abdominal changes otherwise

INTERPRETATION OF THE FINDINGS & FURTHER RECOMMENDATIONS

FNA of the liver could be considered for further definition, yet subjectively appears benign. Stable prostate. However, if any other clinical signs of prostatic disease are present, then neutering or medical management should be considered.





The information and recommendations provided are based on the images presented by the referring veterinarian/sonographer. No evaluation can be communicated regarding pathology that was not visible in the image/video clips provided.

Thank you for this referral. If the clinical or image interpretation does not parallel your findings or if I can be of any further assistance please contact me.

Eric Lindquist, DMV, DABVP, Cert. IVUSS, CEO of SonoPath.com
info@SonoPath.com