



PATIENT PRESENTING CLINICAL SIGNS

B Zajac Is juvenile diabetic, well regulated. Owner has noticed frank blood in urine on 4-5 separate occasions. No urinary signs, no pollakiuria, no stranguria, u/a showed rare rbc, no bacteria, 3+ glucose. Ultrasound today to check for bladder stones- seeing polyp, mass? Pet was not sedated or fasted so only did quick ultrasound- may return for full sdep us pending results

SPECIES Abnormal PE/Chem/CBC/UA Results: u/a - rare rbc, 3+ glucose

Canine

LIMITED ULTRASONOGRAPHIC EXAMINATION

BREED The **urinary bladder** presented areas of embedded mineralization or sand noted, or possible dystrophic mineralization of polypoid changes. Polyps appear to be occupying the dorsal and apical wall primarily. Recommend cystotomy and partial resection of the bladder wall.

GSD

SEX The **left kidney** revealed normal size and structure, corticomedullary definition and ratio for this age. The cortices presented largely uniform texture with normal echogenic relationship to liver and spleen. Medullary structure differed distinctly from the cortex. The capsules were acceptably uniform without significant irregularities. Pyelectasia noted in the left kidney. The left kidney measured 7.0 cm.

Neutered Male

AGE ULTRASONOGRAPHIC FINDINGS

- Polypoid bladder changes, appear resectable

INTERPRETATION OF THE FINDINGS & FURTHER RECOMMENDATIONS

Polypoid tissue resection recommend with exploratory partial cystectomy. Further imaging of the deep pelvic urethra would be ideal to ensure no concurrent polypoid changes in the region. Removal of any sand or small calculi accumulation warranted, as well as histopathology of the polypoid lesions.

INTERPRETED BY

Eric Lindquist, DMV
DABVP, Cert. IVUSS

IMAGING PERFORMED BY

Dr. Meghan Myers

HOSPITAL NAME

Hershire AH

REFERRING VET

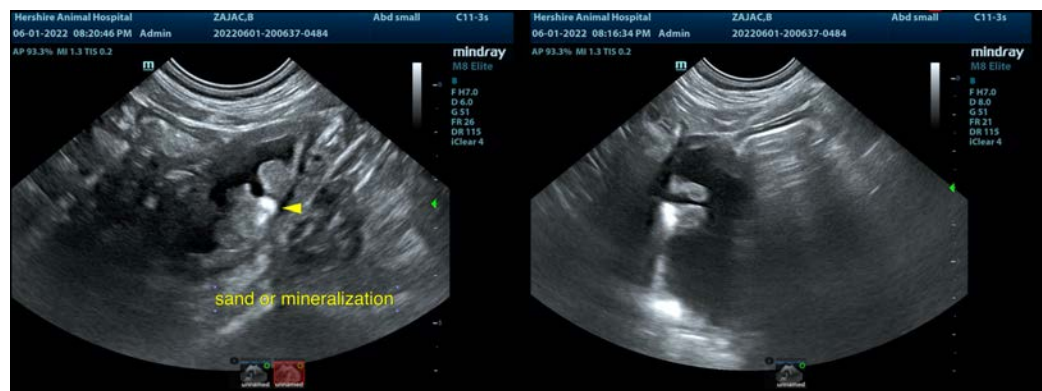
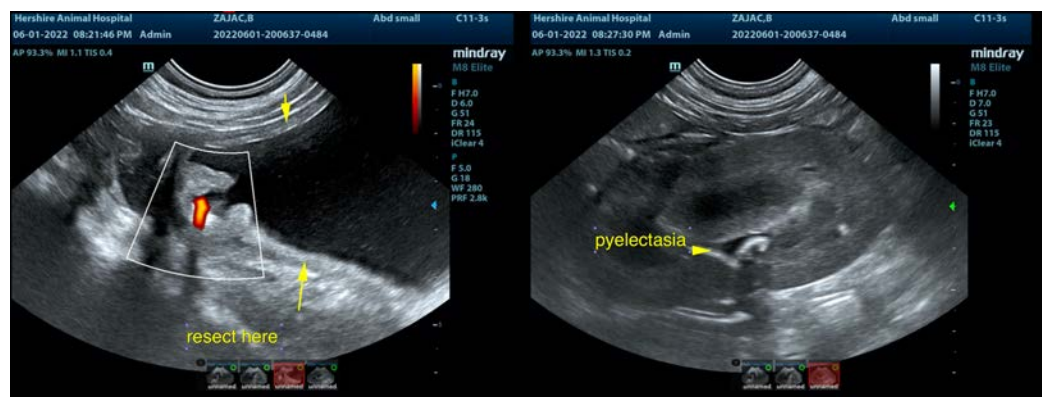
Dr. Meghan Myers

INVOICE

38300

DATE

6/2/22





PATIENT

B Zajac

SPECIES

Canine

BREED

GSD

SEX

Neutered Male

AGE

6 Years

WEIGHT

69 Pounds

INTERPRETED BY

Eric Lindquist, DMV

DABVP, Cert. IVUSS

IMAGING PERFORMED BY

Dr. Meghan Myers

HOSPITAL NAME

Hershire AH

REFERRING VET

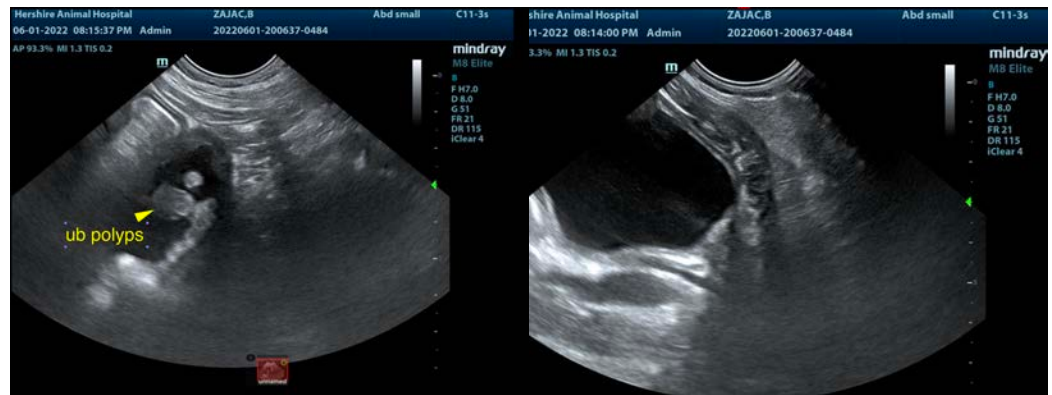
Dr. Meghan Myers

INVOICE

38300

DATE

6/2/22



The information and recommendations provided are based on the images presented by the referring veterinarian/sonographer. No evaluation can be communicated regarding pathology that was not visible in the image/video clips provided.

Thank you for this referral. If the clinical or image interpretation does not parallel your findings or if I can be of any further assistance please contact me.

Eric Lindquist, DMV, DABVP, Cert. IVUSS, CEO of SonoPath.com

info@SonoPath.com