



## PATIENT

Taz Kamrowski

## SPECIES

Canine

## BREED

Pit Bull

## SEX

Intact Male

## AGE

7 Years

## WEIGHT

78 lbs

## INTERPRETED BY

Eric Lindquist, DMV,  
DABVP (CFM), Cert.  
IVUSS

## IMAGING PERFORMED BY

Dr. Gudrun Gunther

## HOSPITAL NAME

New Frontier Animal  
Medical Center

## REFERRING VET

Dr. Gudrun Gunther

## INVOICE

76070

## DATE

6/19/26

## PRESENTING CLINICAL SIGNS

Staging AUS due to cutaneous high grade mast cell tumor on R shoulder  
Abnormal PE/Chem/CBC/UA Results: CHEM 10 WNL

## ULTRASONOGRAPHIC EXAMINATION OF THE ABDOMEN

### Urinary System

The **urinary bladder**, trigone, and pelvic urethra presented normal thicknesses and normal tone. The ureters were not visible which is normal. No uroliths or sediment were visualized and anechoic urine was present. No evidence of inflammatory or neoplastic changes were noted. Ureteral papillae were normal.

The **prostate** was uniformly enlarged (2.7 cm) with lobar swelling appeared to impinge upon the urethra and mildly deviate the descending colon. The prostatic tissue was hyperechoic containing focal areas of decreased echogenicity. These changes are suggestive of either chronic inflammatory episodes, benign cystic pathology or both. Underlying neoplasia cannot be completely ruled-out but is lower on the differential list. This presentation is most consistent with benign prostatic hyperplasia with possible active prostatitis. Neutering or off-label Finasteride (Propecia) (0.1-0.5 mg/kg Sid) treatment is indicated +/- FNA or prostatic wash cytology and culture.

The testicles were imaged and found to be uniform, no evident pathology.

The **kidneys** revealed largely normal size and structure, corticomedullary definition and ratio (cortex 1/3 of medulla) were essentially maintained with some age-related loss of curvilinear patterns regarding the capsule and C/M junction. The cortices presented largely uniform texture with some increased echogenicity expected for his age patient. Medullary structure differed distinctly from that of the cortex and no evidence of pelvic dilation was present. Right kidney measured 7.0 cm. Left kidney measured 7.5 cm.

### Adrenal Glands

Both **adrenal glands** were visualized and recognized as having normal shape, size, position and echogenicity for this breed. The phrenic vasculature, glandular echogenicity and detail were unremarkable. Capsule, cortex, and medullary definition were normal for this age patient. Right measured 2.7 cm x 0.55 cm at the cranial pole and 0.38 cm at the caudal pole. Left measured 3.12 cm x 0.58 cm at the cranial pole and 0.62 cm at the caudal pole.

### Spleen

The **spleen** presented a smooth homogeneous parenchyma hyperechoic to liver and renal cortical parenchyma. The capsule was smooth without noticeable expansion or deviation from within the spleen or adjacent pathology. The splenic vasculature demonstrated normal volume without signs of congestion or thrombosis. No sonographic evidence of acute or chronic inflammatory, neoplastic, or infarctual changes were noted.

### Liver

The **liver** images submitted revealed subjectively normal liver size, contour, and structure. Parenchymal echogenicity was naturally coarse and hypoechoic to the spleen. Vascular and biliary tracts were of normal volume with no evidence of congestion. The gallbladder presented acceptably thin walls with



**PATIENT**

Taz Kamrowski

primarily anechoic content. The cystic and common bile ducts were normal. No pathological hepatic lymphadenopathy was evident. No overt structural evidence of inflammatory, infiltrative or regenerative pathology was evident.

**SPECIES**

Canine

**Gastrointestinal**

Examination of the **gastrointestinal tract** revealed a stomach and intestine free of stasis, of normal wall thickness, acceptable curvilinear mural detail, and peristaltic activity. Small and large intestine demonstrated normal luminal chyme and stool consistency respectively. No obstructive or overt infiltrative disease was noted. No associated abnormal lymphatic activity was noted.

**BREED**

Pit Bull

**Pancreas**

**SEX**

Intact Male

The base and limbs of the **pancreas** were observed to be largely isoechoic to surrounding omental fat. Pancreatic duct and capsular contour were acceptably normal and parenchyma respected normal curvilinear patterns. No overt evidence of active inflammatory or neoplastic disease was noted.

**AGE**

7 Years

**ULTRASONOGRAPHIC FINDINGS**

- Mild BPH prostate.
- Age related renal changes.

**WEIGHT**

78 lbs

**INTERPRETATION OF THE FINDINGS & FURTHER RECOMMENDATIONS**

Structurally unremarkable abdomen. No evidence of metastatic disease consistent with mast cell disease or other.

**INTERPRETED BY**

Eric Lindquist, DMV,  
DABVP (CFM), Cert.  
IVUSS

**IMAGING PERFORMED BY**

Dr. Gudrun Gunther

**HOSPITAL NAME**

New Frontier Animal  
Medical Center

**REFERRING VET**

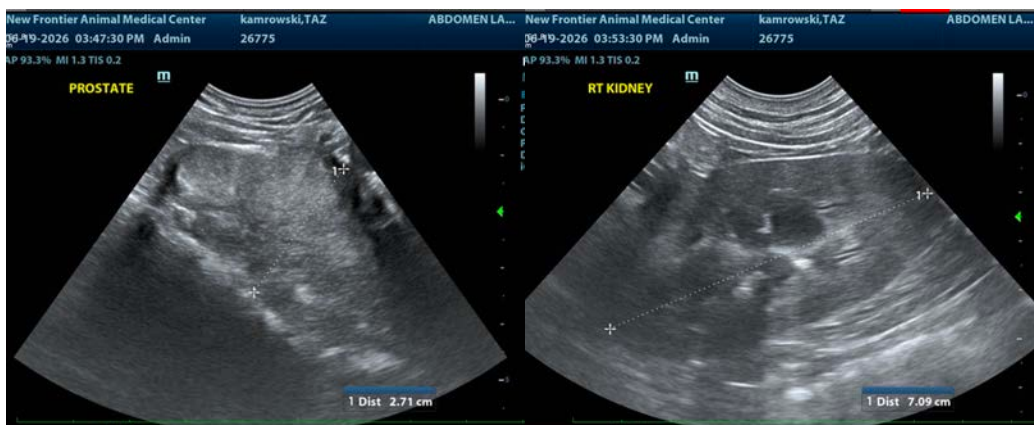
Dr. Gudrun Gunther

**INVOICE**

76070

**DATE**

6/19/26





### PATIENT

Taz Kamrowski

### SPECIES

Canine

### BREED

Pit Bull

### SEX

Intact Male

### AGE

7 Years

### WEIGHT

78 lbs

### INTERPRETED BY

Eric Lindquist, DMV,  
DABVP (CFM), Cert.  
IVUSS

### IMAGING PERFORMED BY

Dr. Gudrun Gunther

### HOSPITAL NAME

New Frontier Animal  
Medical Center

### REFERRING VET

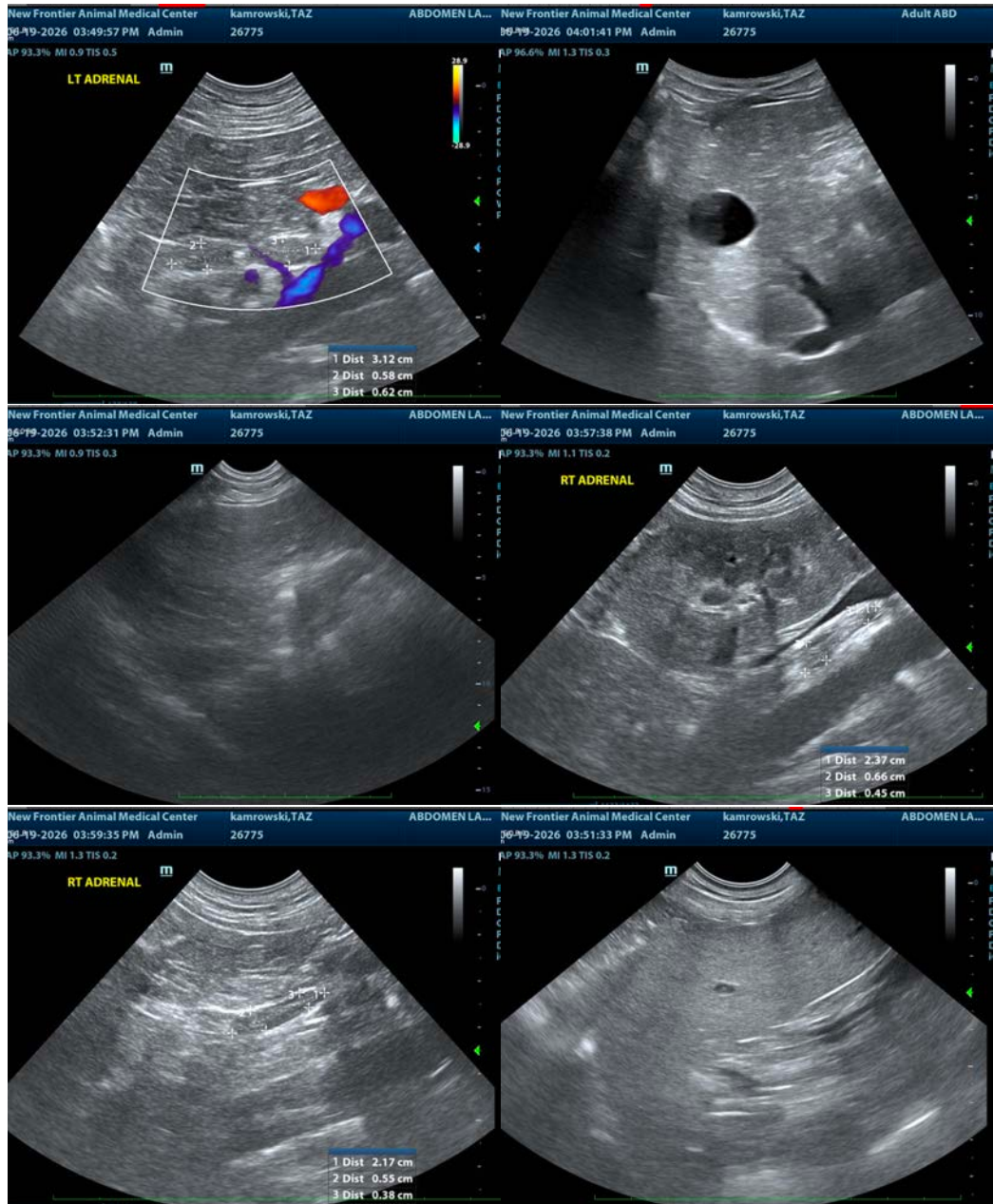
Dr. Gudrun Gunther

### INVOICE

76070

### DATE

6/19/26





## PATIENT

Taz Kamrowski

## SPECIES

Canine

## BREED

Pit Bull

## SEX

Intact Male

## AGE

7 Years

## WEIGHT

78 lbs

## INTERPRETED BY

Eric Lindquist, DMV,  
DABVP (CFM), Cert.  
IVUSS

## IMAGING PERFORMED BY

Dr. Gudrun Gunther

## HOSPITAL NAME

New Frontier Animal  
Medical Center

## REFERRING VET

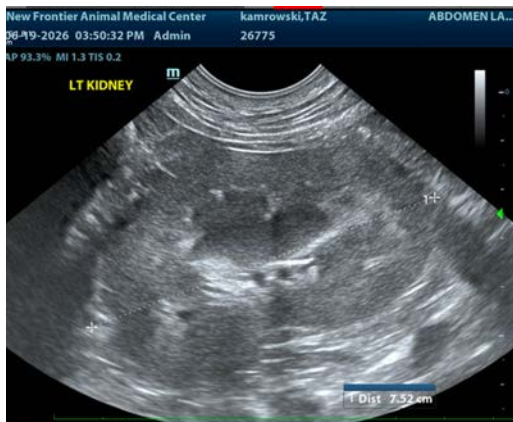Dr. Gudrun Gunther

## INVOICE

76070

## DATE

6/19/26



The information and recommendations provided are based on the images presented by the referring veterinarian/sonographer. No evaluation can be communicated regarding pathology that was not visible in the image/video clips provided.

Thank you for this referral. If the clinical or image interpretation does not parallel your findings or if I can be of any further assistance please contact me.

**Eric Lindquist**, DMV, DABVP(CFM), Cert. IVUSS,  
CEO, Owner, Founder -- SonoPath.com  
[info@SonoPath.com](mailto:info@SonoPath.com)