

PATIENT PRESENTING CLINICAL SIGNS

Tuukka Berardi Presented for annual exam on 5/27 with complaint of "urine odor". On PE patient had urine scalding at vulva with swelling. Attempted cysto but visualized a mural structure, so did not perform cysto. Free catch urine performed = blood 2+, RBC 21-50 (no bacteria or WBC) *Study limited to urinary system

SPECIES LIMITED ULTRASONOGRAPHIC EXAMINATION

Feline **Urinary System**

BREED The urinary bladder itself was unremarkable. Normal curvilinear patterns. However, a grouping of calculi was noted, measuring approximately 3.0 mm. The calculi appeared to be flattened. The pelvic urethra was imaged 2.0 cm beyond the cystourethral junction. This patient is likely passing calculi from the kidneys to the bladder.

SEX The kidneys revealed largely normal size and structure, corticomedullary definition and ratio (cortex 1/3 of medulla) were essentially maintained with some age-related loss of curvilinear patterns regarding the capsule and C/M junction. The cortices presented largely uniform texture with some increased echogenicity expected for his age patient. Medullary structure differed distinctly from that of the cortex and no evidence of pelvic dilation was present. The left kidney measured 4.03 cm. The right kidney measured 3.97 cm.

AGE
 9 Years

ULTRASONOGRAPHIC FINDINGS

- WEIGHT**
- Urinary bladder calculi
 - Age related renal changes
- 16.2 Pounds

INTERPRETATION OF THE FINDINGS & FURTHER RECOMMENDATIONS

INTERPRETED BY Recommend cystotomy, stone analysis and culture. Bladder wall biopsy recommended to ensure underlying disease is not an issue, but the material appears to be moving separately from the bladder wall itself. Recommend bladder ultrasound just prior to surgery to ensure the calculi are persistently present.

Eric Lindquist, DMV
 DABVP, Cert. IVUSS

IMAGING PERFORMED BY

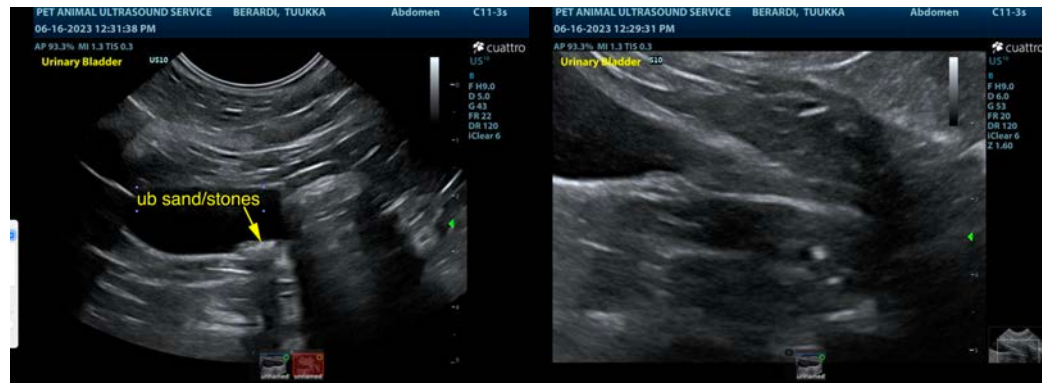
Pamela Harrigan, RDCS

HOSPITAL NAME

Norfolk County VS

REFERRING VET

Dr. Emily McCabe

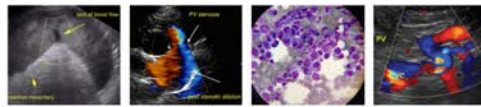


INVOICE

43276

DATE

6/17/23



PATIENT

Tuukka Berardi

SPECIES

Feline

BREED

DSH

SEX

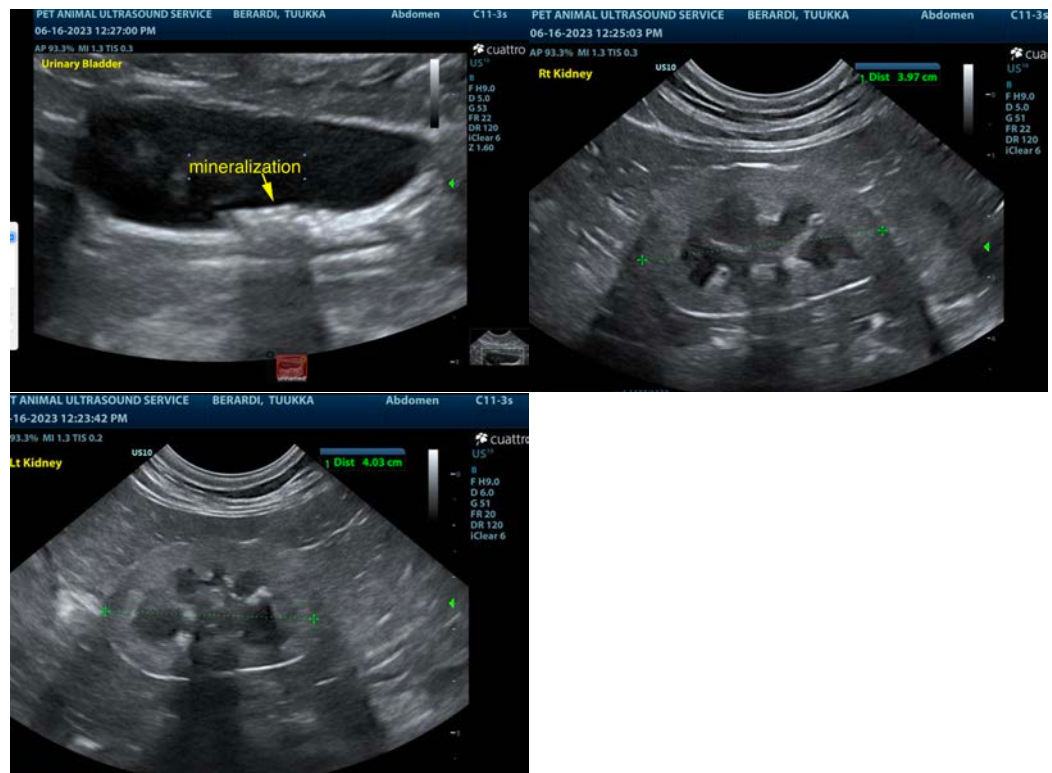
Spayed Female

AGE

9 Years

WEIGHT

16.2 Pounds



INTERPRETED BY

Eric Lindquist, DMV
 DABVP, Cert. IVUSS

IMAGING PERFORMED BY

Pamela Harrigan, RDCS

HOSPITAL NAME

Norfolk County VS

REFERRING VET

Dr. Emily McCabe

INVOICE

43276

DATE

6/17/23

The information and recommendations provided are based on the images presented by the referring veterinarian/sonographer. No evaluation can be communicated regarding pathology that was not visible in the image/video clips provided.

Thank you for this referral. If the clinical or image interpretation does not parallel your findings or if I can be of any further assistance please contact me.

Eric Lindquist, DMV, DABVP, Cert. IVUSS, CEO of SonoPath.com

info@SonoPath.com