



**PATIENT**

Roxy Spritznagal

**PRESENTING CLINICAL SIGNS**

Acute vomiting last few days lethargic with weight loss. And chest x rays inconclusive. Abnormal PE/Chem/CBC/UA Results: Stress leukogram Chemistry non diagnostic

**SPECIES**

Felinie

**ULTRASONOGRAPHIC EXAMINATION OF THE ABDOMEN**

**Urinary System**

**BREED**

DLH

The **urinary bladder**, trigone, and pelvic urethra presented normal thicknesses and normal tone. The ureters were not visible which is normal. No uroliths or sediment were visualized and anechoic urine was present. No evidence of inflammatory or neoplastic changes were noted. Ureteral papillae were normal. The pelvic urethra was imaged 1.0 cm beyond the cystourethral junction.

**SEX**

Spayed Female

The **kidneys** revealed normal size and structure, corticomedullary definition and ratio for this age. The cortices presented largely uniform texture with normal echogenic relationship to liver and spleen. Medullary structure differed distinctly from the cortex and no evidence of pelvic dilation was present. The capsules were acceptably uniform without significant irregularities. The right kidney measured 3.62 cm. The left kidney measured 3.82 cm.

**AGE**

14 Years

**Adrenal Glands**

**WEIGHT**

4.7 kg

Both **adrenal glands** were visualized and recognized as having normal shape, size, position and echogenicity for this breed. The phrenic vasculature, glandular echogenicity and detail were unremarkable. Capsule, cortex, and medullary definition were normal for this age patient. The right adrenal gland measured 0.30 cm. The left adrenal gland measured 0.32 cm.

**Spleen**

**INTERPRETED BY**

Eric Lindquist, DMV

DABVP, Cert. IVUSS

The **spleen** presented a smooth homogeneous parenchyma hyperechoic to liver and renal cortical parenchyma. The spleen measured 0.50 cm. The capsule was smooth without noticeable expansion or deviation from within the spleen or adjacent pathology. The splenic vasculature demonstrated normal volume without signs of congestion or thrombosis. No sonographic evidence of acute or chronic inflammatory, neoplastic, or infarctual changes were noted.

**IMAGING PERFORMED BY**

Dr. Belan

**Liver**

**HOSPITAL NAME**

Alpine 24/7

The **liver** images submitted revealed subjectively normal liver size, contour, and structure. Parenchymal echogenicity was naturally coarse and hypoechoic to the spleen. Vascular and biliary tracts were of normal volume with no evidence of congestion. The gallbladder presented acceptably thin walls with primarily anechoic content. The cystic and common bile ducts were normal. No pathological hepatic lymphadenopathy was evident. No overt structural evidence of inflammatory, infiltrative or regenerative pathology was evident.

**REFERRING VET**

Dr. Zhao

**Gastrointestinal**

**INVOICE**

38847

The **gastrointestinal** presentation revealed mild uniform prominence of the gastric mucosa as well as areas of "ropey" small intestinal wall with slight disruption of the normal 1:3 muscularis/mucosal ratio. The intestinal submucosa was slightly irregular, thickened and hyperechoic suggestive of low grade, chronic disease. No evidence of obstruction was present. Chronic inflammatory bowel disease is likely with a low possibility of an early neoplastic event such as lymphoma. Full thickness tissue biopsies via open laparotomy, ideally guided by intraoperative ultrasound in order to obtain the most representative mural sample, would be necessary to rule out this possibility.

**DATE**

6/17/22

Reactive mesenteric lymph nodes noted up to 0.30 cm.



**PATIENT**

**Pancreas**

Roxy Spritznagal

The **pancreas** presented heterogeneous changes with enhanced surrounding mesentery. Subxiphoid palpation is recommended to assess for pain or discomfort associated with the pancreas.

**SPECIES**

**ULTRASONOGRAPHIC FINDINGS**

Felinie

- Inflammatory bowel/pancreatitis type presentation with reactive lymphadenopathy

**BREED**

**INTERPRETATION OF THE FINDINGS & FURTHER RECOMMENDATIONS**

DLH

No neoplastic criteria noted. Maldigestion panel, three view chest radiographs and full CNS examination is recommended to examine for occult disease that could be responsible for the weight loss. Evaluation for competitive eating environments should also be considered. A clinical trial of the following may prove effective.

**SEX**

**Triaditis/Pancreatitis protocol**

Spayed Female

Part or all of this protocol may be considered based on your clinical impression of the patient:

**AGE**

Recommend pain management when anorexic with **Buprenorphine** (0.01-0.02 mg/kg IM or SC), clinical trial of **Zithromax** (50 mg sid/cat x 10 days, 3 weeks if bartonella +), **Prednisolone** (0.5-2 mg/kg tapering over 1 week to minimal effective dose), and **B12 injections** if weight loss (Cyanobalamine 250 mcg sub-q once-weekly x six weeks, then every other week for six weeks and then once-monthly, long-term if necessary), **novel-protein or hydrolyzed diet** (*Hydrolyzed diets have been shown to be more effective in dietary intolerance case management compared to hypoallergenic diets*) or the **magical Purina DM** (changing protein source is crucial and may need rotation every 6 months if clinical signs recur) Diet trials is a whatever works phenomenon. If vomiting becomes a persistent issue then endoscopy would be warranted and/or recheck sonogram to assess more emerging disease. One diet does not work for all patients so different trials may be necessary or protein source rotation every 6 months as new sensitivities develop.

14 Years

**WEIGHT**

4.7 kg

**INTERPRETED BY**

Eric Lindquist, DMV

DABVP, Cert. IVUSS

**IMAGING PERFORMED BY**

Dr. Belan

**HOSPITAL NAME**

Alpine 24/7

**REFERRING VET**

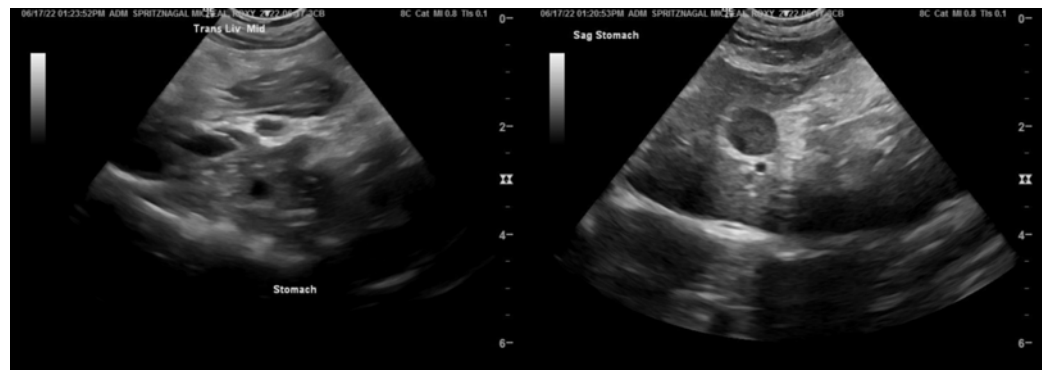
Dr. Zhao

**INVOICE**

38847

**DATE**

6/17/22





**PATIENT**

Roxy Spritznagal

**SPECIES**

Felinie

**BREED**

DLH

**SEX**

Spayed Female

**AGE**

14 Years

**WEIGHT**

4.7 kg

**INTERPRETED BY**

Eric Lindquist, DMV  
DABVP, Cert. IVUSS

**IMAGING PERFORMED BY**

Dr. Belan

**HOSPITAL NAME**

Alpine 24/7

**REFERRING VET**

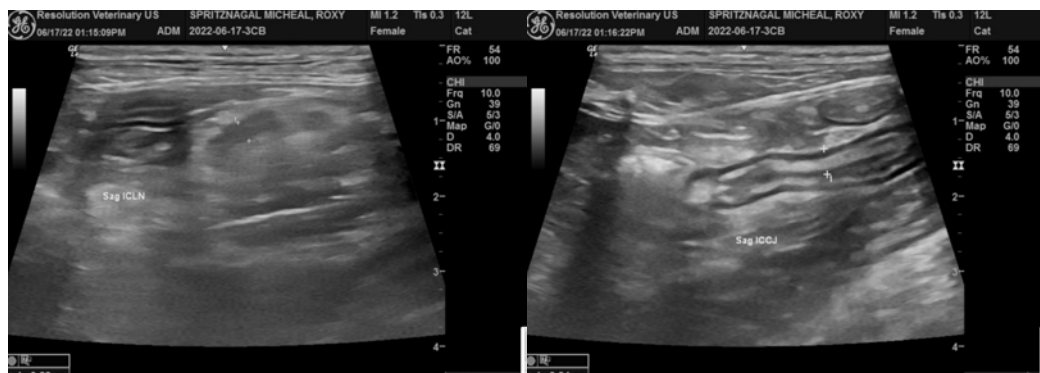
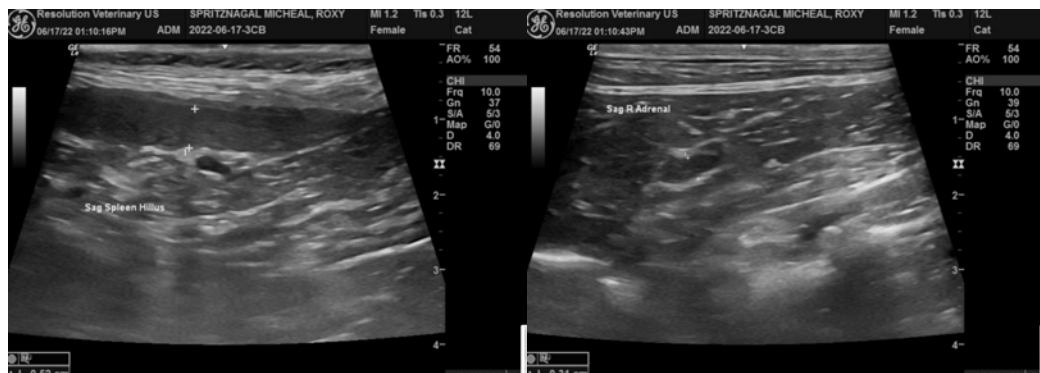
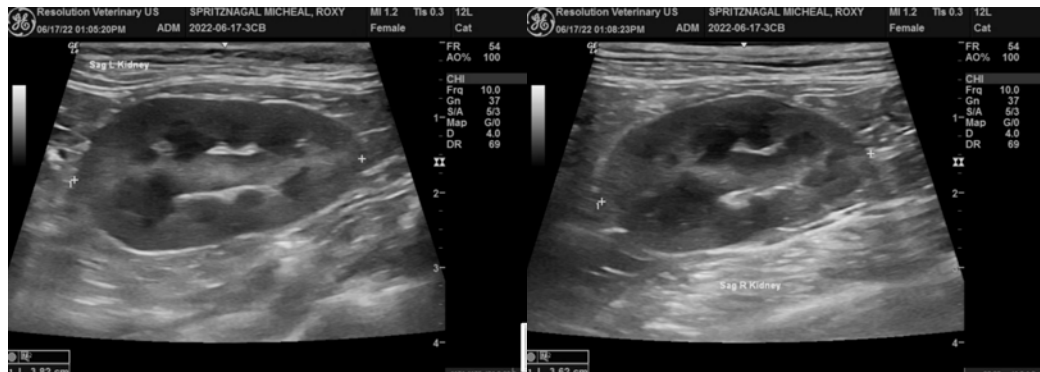
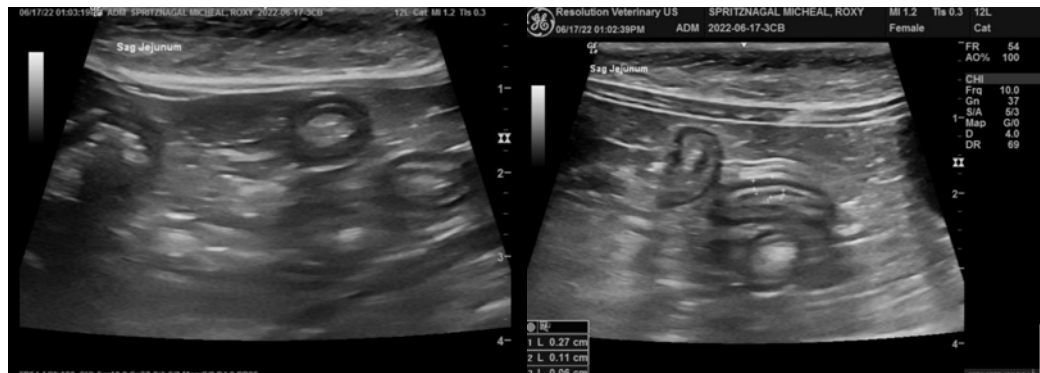Dr. Zhao

**INVOICE**

38847

**DATE**

6/17/22





**PATIENT**

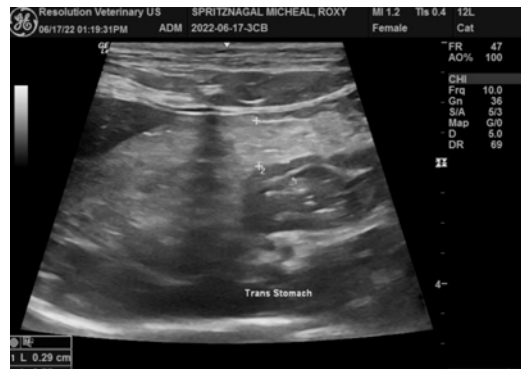Roxy Spritznagal

**SPECIES**

Felinie

**BREED**

DLH



**SEX**

Spayed Female

**AGE**

14 Years

**WEIGHT**

4.7 kg

**INTERPRETED BY**

Eric Lindquist, DMV

DABVP, Cert. IVUSS

**IMAGING PERFORMED BY**

Dr. Belan

**HOSPITAL NAME**

Alpine 24/7

**REFERRING VET**

Dr. Zhao

**INVOICE**

38847

**DATE**

6/17/22

The information and recommendations provided are based on the images presented by the referring veterinarian/sonographer. No evaluation can be communicated regarding pathology that was not visible in the image/video clips provided.

Thank you for this referral. If the clinical or image interpretation does not parallel your findings or if I can be of any further assistance please contact me.

Eric Lindquist, DMV, DABVP, Cert. IVUSS, CEO of SonoPath.com

[info@SonoPath.com](mailto:info@SonoPath.com)