



PATIENT

Rocky Santalucia

PRESENTING CLINICAL SIGNS

Grade 3/6 murmur. Previous echo done 6/15/21. Recheck prior to surgery
Abnormal PE/Chem/CBC/UA Results: BP 164/124(132),146/89(128),138/84(114)

SPECIES

Canine

ULTRASONOGRAPHIC EXAMINATION OF THE HEART

BREED

Chihuahua

SEX

Intact Male

AGE

13 Years

WEIGHT

7.2 Pounds

CANINE CARDIAC PARAMETERS	MR VMAX (m/s)	TR VMAX (m/s)	LA/AO (Boon method)	LA/AO (Heart Base; Swe)	FS (%)	EF (%)	EPSS (cm)
NORMAL PARAMETER	4.5-5.5	<2.7	1.3	<1.6	28-40	40-100	<0.6
PATIENT	5.26		1.4	1.5	65	94	0.2
CANINE CARDIAC PARAMETERS	HR (BPM)	AV VMAX (m/s)	PV MAX (m/s)	BODY WEIGHT (kg)	LA 2D short axis Base view (cm)	LVIDd Avg; 2D and m-mode short axis (cm)	LVIDs Avg; 2D and m-mode short axis (cm)
NORMAL PARAMETER	50-100	0.7-1.7	0.7-1.6	BELOW	BELOW	BELOW	BELOW
PATIENT	149	1.2	1.1		2.5	2.19	

Cardiac Presentation

The echocardiogram in this patient demonstrated normal **left atrial** size based on 3 different LA measurement methods. Chamber volumes and echogenicity were normal. The cranial and caudal **mitral** valve leaflets presented vegetative thickening consistent with endocardiosis. Doppler indicated measurable insufficiency. Prolapse of the anterior mitral valve leaflet noted, yet no volume overload. The **left ventricle** presented thicknesses with linear contour and was not dilated nor restricted. The **myocardium** presented normal echogenicity without subjective evidence of significant fibrotic or ischemic disease. **Contractility** of the ventricular walls was adequate and in normal range for this patient evidenced by the fractional shortening measurement and subjective evaluation of the different regions of the myocardium. The **left ventricular outflow** tract demonstrated normal laminar flow and subjective structural integrity. The **right atrium** and auricle revealed normal size, structure and content. No evidence of masses was noted or chamber overload. **Tricuspid** valvular assessment demonstrated adequate linear morphology. The **right ventricle** was of normal size (1/3 diameter of LV), chordae structure, myocardial echogenicity and thickness. **Pulmonic** tract assessment revealed normal valve structure, laminar flow, and diameter (approx.1:1 pa/ao ratio). No visible **pericardial** or free pleura fluid was noted. No echographically detectable evidence of infiltrative disease was visible. The cranial **mediastinum** and **pericardial** regions were free of masses in the visible window.

ULTRASONOGRAPHIC FINDINGS

- Stable Stage B1 valvular disease

INTERPRETATION OF THE FINDINGS & FURTHER RECOMMENDATIONS

Minor anesthetic risk. Torbutrol pre-med, Propofol induction, Isoflurane maintenance or similar anesthetic protocol recommended. Recheck echo in 3-6 months, depending on murmur grade and any clinical signs.

INTERPRETED BY

Eric Lindquist, DMV

DABVP, Cert. IVUSS

IMAGING PERFORMED BY

JK

HOSPITAL NAME

Hamburg Vet Clinic

REFERRING VET

Dr. DenHeyer

INVOICE

38832

DATE

6/17/22



PATIENT

Rocky Santalucia

SPECIES

Canine

BREED

Chihuahua

SEX

Intact Male

AGE

13 Years

WEIGHT

7.2 Pounds

INTERPRETED BY

Eric Lindquist, DMV
DABVP, Cert. IVUSS

IMAGING PERFORMED BY

JK

HOSPITAL NAME

Hamburg Vet Clinic

REFERRING VET

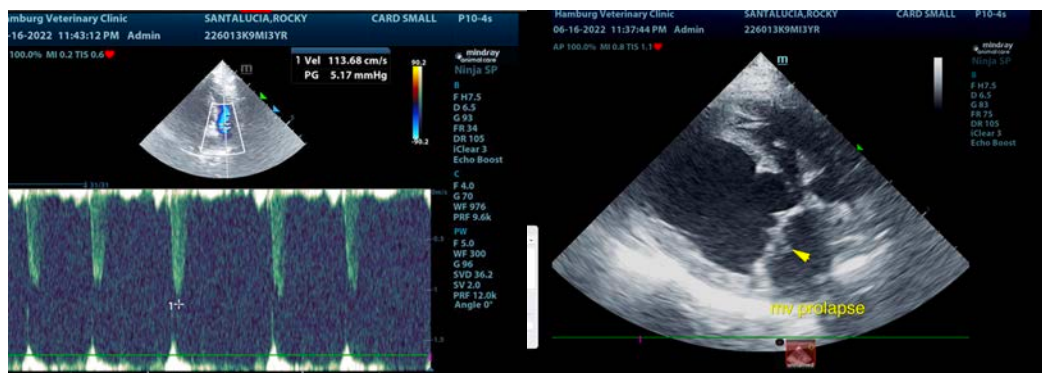
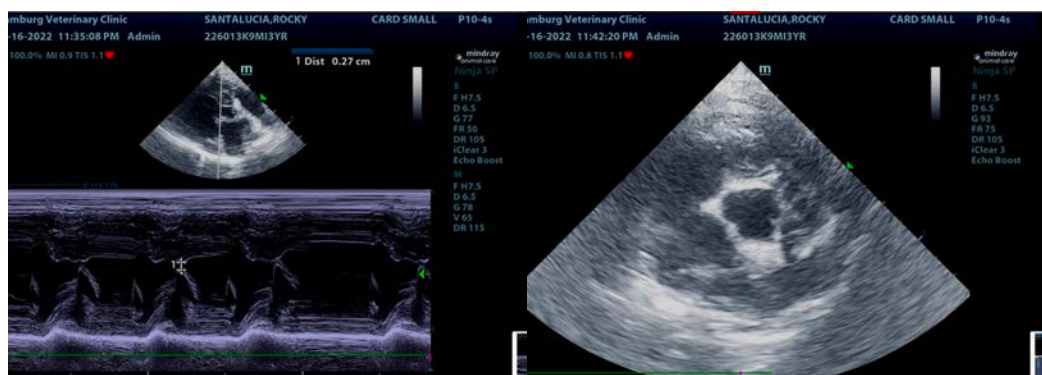
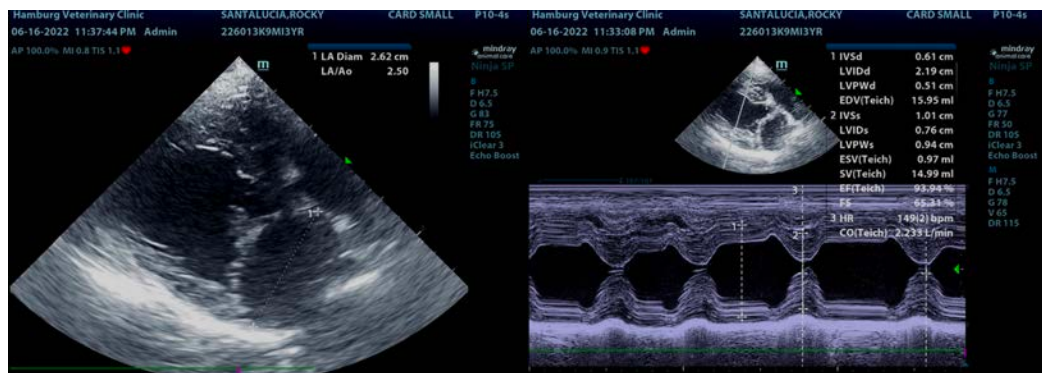
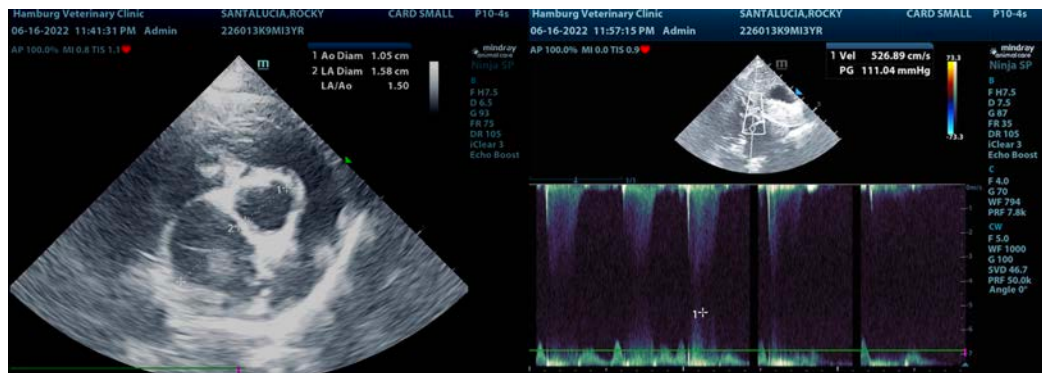
Dr. DenHeyer

INVOICE

38832

DATE

6/17/22





PATIENT

Rocky Santalucia

The information and recommendations provided are based on the images presented by the referring veterinarian/sonographer. No evaluation can be communicated regarding pathology that was not visible in the image/video clips provided.

SPECIES

Canine

Thank you for this referral. If the clinical or image interpretation does not parallel your findings or if I can be of any further assistance please contact me.

Eric Lindquist, DMV, DABVP, Cert. IVUSS, CEO of SonoPath.com

info@SonoPath.com

BREED

Chihuahua

SEX

Intact Male

AGE

13 Years

WEIGHT

7.2 Pounds

INTERPRETED BY

Eric Lindquist, DMV

DABVP, Cert. IVUSS

IMAGING PERFORMED BY

JK

HOSPITAL NAME

Hamburg Vet Clinic

REFERRING VET

Dr. DenHeyer

INVOICE

38832

DATE

6/17/22