



**PATIENT**

Martina Verillo

**PRESENTING CLINICAL SIGNS**

Consumed underwear, vomiting sine. X-rays show colonic FB.  
Abnormal PE/Chem/CBC/UA Results: nsf

**SPECIES**

Canine

**ULTRASONOGRAPHIC EXAMINATION OF THE ABDOMEN**

**Urinary System**

The **urinary bladder**, trigone, and pelvic urethra presented normal thicknesses and normal tone. The ureters were not visible which is normal. No uroliths or sediment were visualized and anechoic urine was present. No evidence of inflammatory or neoplastic changes were noted. Ureteral papillae were normal. The pelvic urethra was imaged 2.0 cm beyond the cystourethral junction.

**BREED**

Doberman Pinscher

**SEX**

Spayed Female

The **kidneys** revealed normal size and structure, corticomedullary definition and ratio for this age. The cortices presented largely uniform texture with normal echogenic relationship to liver and spleen. Medullary structure differed distinctly from the cortex and no evidence of pelvic dilation was present. The capsules were acceptably uniform without significant irregularities. The left kidney measured 6.25 cm. The right kidney measured 6.25 cm.

**AGE**

3 Years 6 Months

**Adrenal Glands**

Both **adrenal glands** were visualized and recognized as having normal shape, size, position and echogenicity for this breed. The phrenic vasculature, glandular echogenicity and detail were unremarkable. Capsule, cortex, and medullary definition were normal for this age patient. The right adrenal gland measured 2.43 cm x 1.27 cm at the cranial pole and 0.74 cm at the caudal pole. The left adrenal gland measured 2.38 cm x 0.58 cm at the cranial pole and 0.68 cm at the caudal pole.

**WEIGHT**

88 Pounds

**Spleen**

**INTERPRETED BY**

Eric Lindquist, DMV

DABVP, Cert. IVUSS

The **spleen** presented a smooth homogeneous parenchyma hyperechoic to liver and renal cortical parenchyma. The spleen was folded upon itself cranially. The capsule was smooth without noticeable expansion or deviation from within the spleen or adjacent pathology. The splenic vasculature demonstrated normal volume without signs of congestion or thrombosis. No sonographic evidence of acute or chronic inflammatory, neoplastic, or infarctual changes were noted.

**IMAGING PERFORMED BY**

Shari Reffi, CVT

**Liver**

**HOSPITAL NAME**

Rockaway AH

The **liver** images submitted revealed subjectively normal liver size, contour, and structure. Parenchymal echogenicity was naturally coarse and hypoechoic to the spleen. Vascular and biliary tracts were of normal volume with no evidence of congestion. The gallbladder presented acceptably thin walls with primarily anechoic content. The cystic and common bile ducts were normal. No pathological hepatic lymphadenopathy was evident. No overt structural evidence of inflammatory, infiltrative or regenerative pathology was evident.

**REFERRING VET**

Dr. Maniar

**Gastrointestinal**

**INVOICE**

38822

The **colon** revealed shadowing, partially obstructive material from the descending colon and pelvic inlet with fluid filled lumen prior to the colonic material. The upper gastrointestinal tract revealed some gas, yet no evidence of obstruction. The pylorus was mildly thickened, likely owing to prior insult. Minor luminal fluid present without obstruction or foreign matter. The small intestine was empty.

**DATE**

6/17/22



**PATIENT**

Martina Verillo

**SPECIES**

Canine

**BREED**

Doberman Pinscher

**SEX**

Spayed Female

**AGE**

3 Years 6 Months

**WEIGHT**

88 Pounds

**INTERPRETED BY**

Eric Lindquist, DMV  
DABVP, Cert. IVUSS

**IMAGING PERFORMED BY**

Shari Reffi, CVT

**HOSPITAL NAME**

Rockaway AH

**REFERRING VET**

Dr. Maniar

**INVOICE**

38822

**DATE**

6/17/22

**Pancreas**

The base and limbs of the **pancreas** were observed to be largely isoechoic to surrounding omental fat. Pancreatic duct and capsular contour were acceptably normal and parenchyma respected normal curvilinear patterns. No overt evidence of active inflammatory or neoplastic disease was noted.

**PRIMARY FINDINGS**

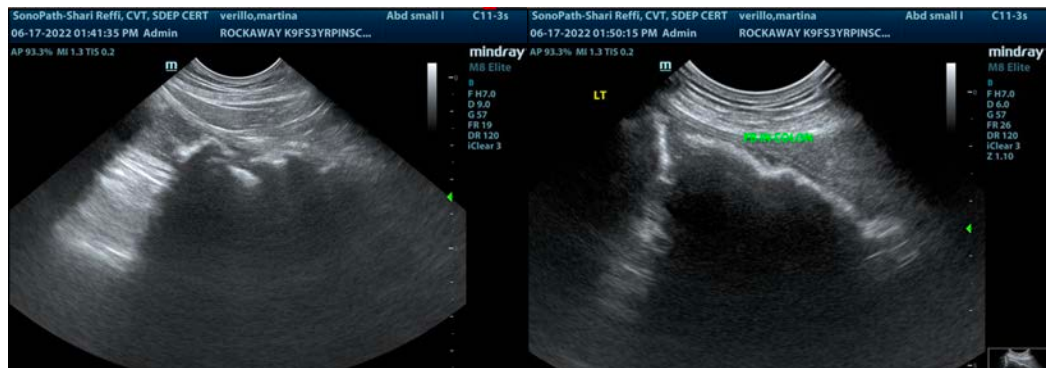
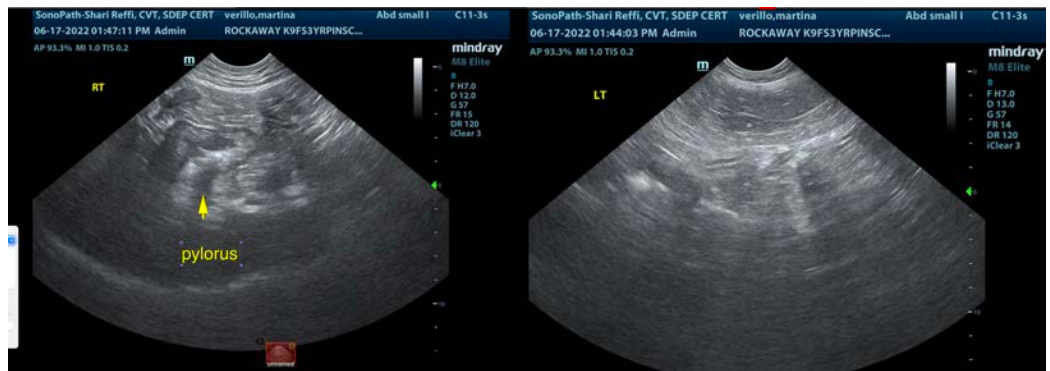
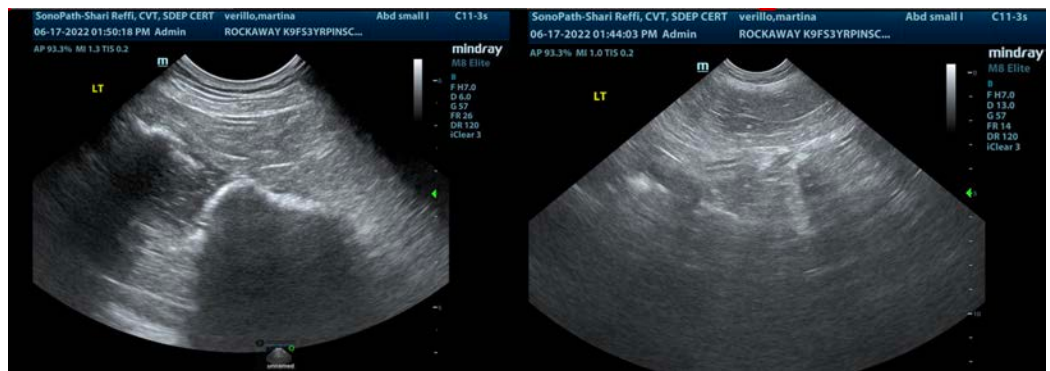
- Colonic stasis and foreign matter

**SECONDARY FINDINGS**

- Folded spleen

**INTERPRETATION OF THE FINDINGS & FURTHER RECOMMENDATIONS**

Sedation and foreign matter retrieval should prove effective without surgery. Recheck sonogram in 12-24 hours to ensure adequate evacuation.





**PATIENT**

Martina Verillo

**SPECIES**

Canine

**BREED**

Doberman Pinscher

**SEX**

Spayed Female

**AGE**

3 Years 6 Months

**WEIGHT**

88 Pounds

**INTERPRETED BY**

Eric Lindquist, DMV  
DABVP, Cert. IVUSS

**IMAGING PERFORMED BY**

Shari Reffi, CVT

**HOSPITAL NAME**

Rockaway AH

**REFERRING VET**

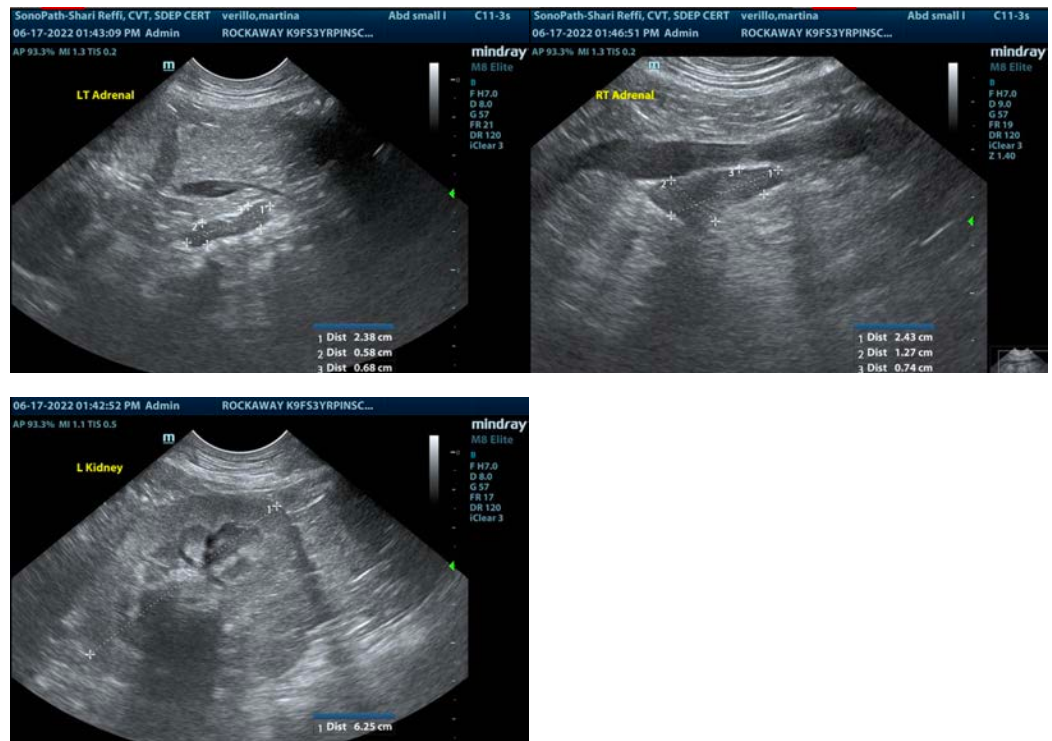
Dr. Maniar

**INVOICE**

38822

**DATE**

6/17/22



The information and recommendations provided are based on the images presented by the referring veterinarian/sonographer. No evaluation can be communicated regarding pathology that was not visible in the image/video clips provided.

Thank you for this referral. If the clinical or image interpretation does not parallel your findings or if I can be of any further assistance please contact me.

Eric Lindquist, DMV, DABVP, Cert. IVUSS, CEO of SonoPath.com

[info@SonoPath.com](mailto:info@SonoPath.com)